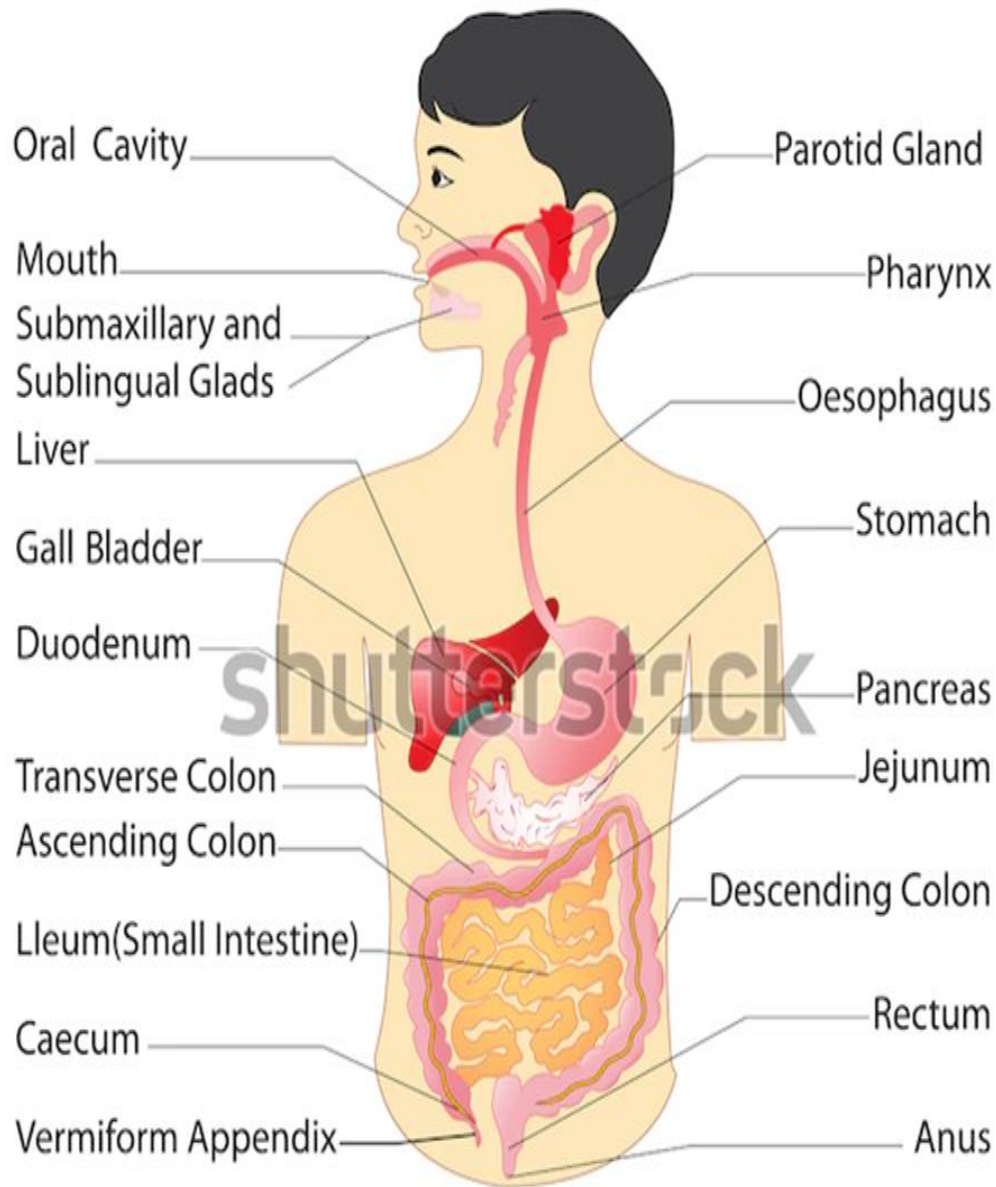




Assessment of the Digestive System

Rodica Bugai PhD, assoc. prof.



The digestive system represents the morphological and functional ensemble of organs, which achieves the digestion and absorption of ingested foods as well as the evacuation of unassimilable residues.



Digestive System

MOM, HOW DOES THE DIGESTIVE SYSTEM WORK?

GOOD AT YOUR AGE, BAD AT MY AGE, AND AT YOUR FATHER'S AGE, FORGET ABOUT IT.

HEY!

CARTOONSTOCK

Search ID: gla110203

WISE/AGDRICH

Digestive system-component structures

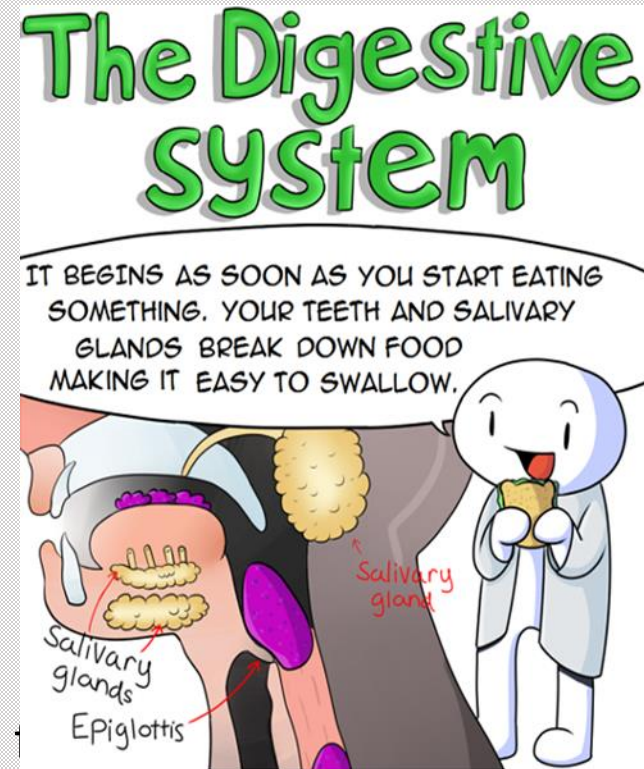
- The digestive system consists of:
 - **digestive tract**, a series of tubular organs of different caliber;
 - **glands**, anchored at different stages of the digestive tract.

- **Digestive tract:**

It measures approximately 9 m in length, from the oral cavity to the anus, constituting the trajectory of the ingested foods during which they undergo transformations necessary for the preparation of food for the cells of the body, through physical and chemical digestive processes.

Digestive system-component structures

- The **oral cavity** is the first segment of the digestive tract, where digestion is started. The oral cavity includes the **tongue** and **teeth**. Through the tongue, the taste, texture, but also the temperature of the food are distinguished. Denture is mainly involved in mastication, which together with the chemical digestion achieved by the action of saliva forms at this level the



Digestive system-component structures

- The **stomach** is a cavitory organ, placed in the gastric lodge in the abdomen and represents the most dilated segment of the digestive tract. It is responsible for transforming the food bowl by mechanical and chemical actions into gastric chem, which it stores until it becomes ready to be evacuated in the small intestine.



Digestive system-component structures

- **Small intestine:**

- it is the longest segment of the digestive tract, measuring a diameter of 2.5 cm and a length of up to 6 m, from the orifice of the pylorus to the ileo-cecal valve.

- In the small intestine, the gastric chemo is transformed into intestinal chilies through a complex of processes, being absorbed about 90% of the nutrients that the body subsequently receives after digestion.

- The small intestine is subdivided into the **duodenum**, the fixed portion where hepatic and pancreatic juice is secreted, the **jejunum**, the middle portion, mobile, spiral, which connects to the **ileum**, the final portion of the small intestine that extends to the **ileo-cecal valve**, from where the digestive tract continues to the large intestine.

Digestive system-component structures

- Large intestine:

- it is the last segment of the digestive tract, having a caliber superior to the small intestine and a length of up to 1.6 m, between the **ileo-cecal valve** and the **anus**.

- At this level, the unabsorbed nutrients from the intestinal keel are taken over, transformed and eliminated later in the form of feces. ---The large intestine has a check with the pyloric appendix, the colon, arranged in a frame around the small intestine, comprising the **ascending, transverse, descending and sigmoid** portion ending in the **rectum**, in which feces are stored before being eliminated by defecation.

- The **anal canal**, located below the rectum, opens through the anal or anus, at which level the digestive tract ends.

Annexes glands of the digestive system

Contributes to digestion through secretions.

- The **salivary glands** are responsible for secreting saliva, a mixture of water, enzymes and mucin, into the oral cavity to lubricate the food to be ingested. Enzymes in saliva also interact with food in the mouth, triggering the process of chemical digestion.
- The **liver** is placed in the hepatic lodge, under the diaphragm and represents the largest gland in the body, weighing about 1.5 kg. The liver has **over 500 functions**, being involved in the process of digestion through the secretion of bile, a liquid that acts with predilection in the degradation of fats. Between meals the bile accumulates in the gallbladder or gallbladder.
- The **pancreas** is a mixed, retroperineal gland located behind the stomach. The exocrine function of the pancreas is involved in digestion, being responsible for the development and secretion of pancreatic juice, a fluid that contains enzymatic equipment capable of degrading all types of food.

Examination of the digestive system

- complaints
- history (of the disease and life)
- inspection
- auscultation
- palpation
- percussion



The History and Physical in Perspective

- 70% of diagnoses can be made based on **history** alone.
- 90% of diagnoses can be made based on **history and physical exam**.
- **Expensive tests** often confirm what is found during the **history and physical**.

NB!!! Important aspects of physical examination

- Elegant appearance
- Decent manner
- Kind attitude
- Highly responsibility
- Good medical morals
- ...



NB!!! Important aspects of physical examination

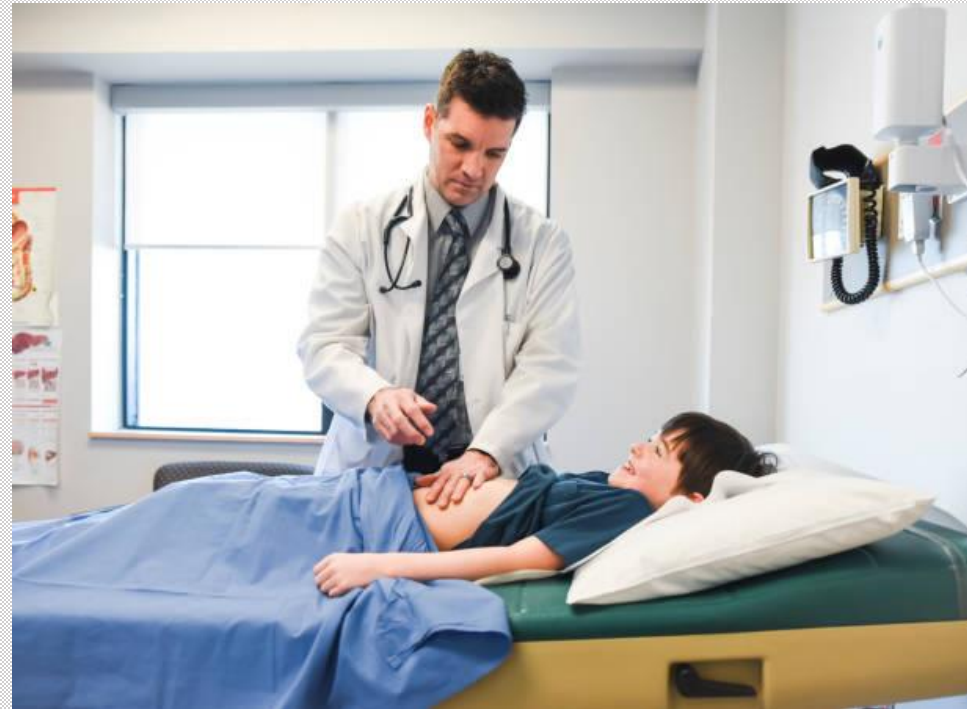- ▶ Wash your hands, preferably while the patient is watching
- ▶ Washing with soap and water is an effective way to reduce the transmission of disease



NB!!!

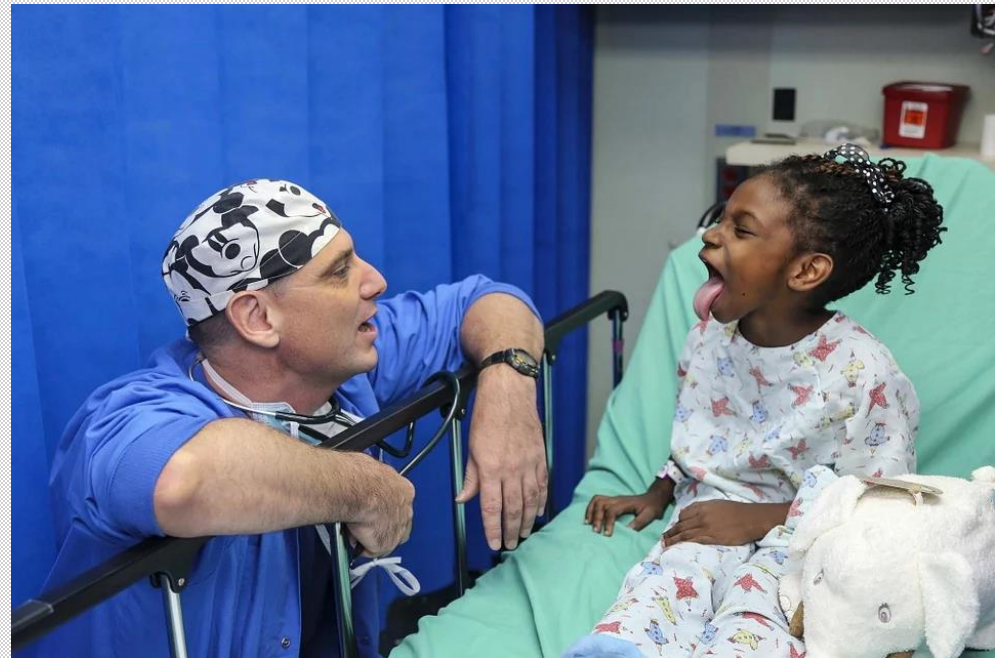Physical examination

- Create **comfortable conditions** for the patient
- Make sure there is enough **light**
- **Explain** what you're going to do Sequential
- **Exposing only the area** that are being examined
- Use **warm hand, warm stethoscope**, and have **short finger nails**



NB!!! Important aspects of physical examination

- ❖ The examiner should continue **speaking** to the patient during the examination
- ❖ **Showing care** to his disease and answer to patient's questions
- ❖ Watch the **patient's face** for discomfort.
- ❖ It can not only release patient's nerviness, but also help to establish the **good physician-patient relationship**



NB!!! Principles of examination

- ❖ Have the patient lie in a comfortable, flat, supine position
- ❖ Have them keep their arms at their sides or folded on the chest
- ❖ The doctor has to be from the right side of the patient
- ❖ If muscles remain tense, patient may be asked to rest feet on table with hips and knees flexed
- ❖ Take a spare bed sheet and drape it over their lower body such that it just covers the upper edge of their underwear

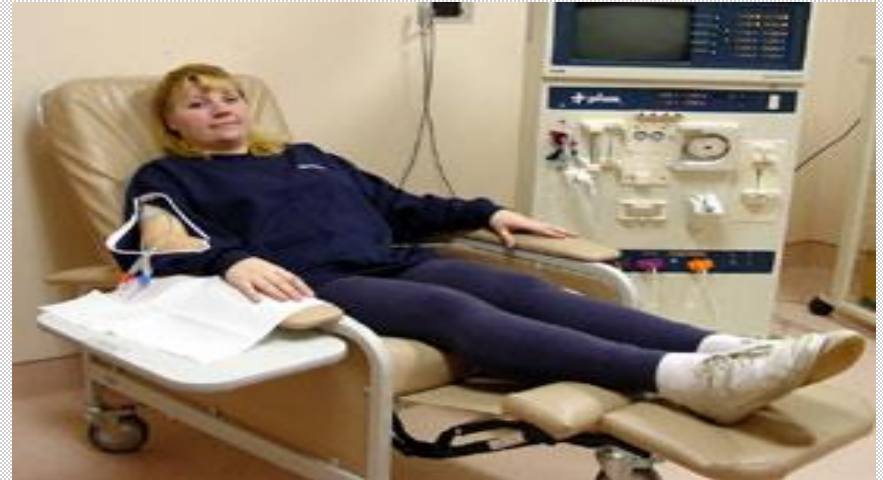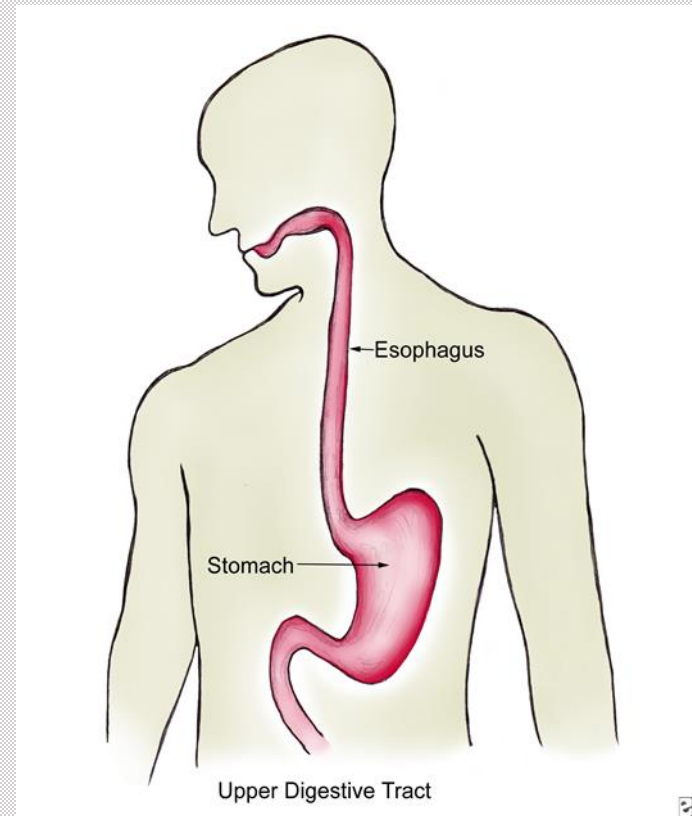


Figure 15.10 The dorsal recumbent position.

Esophagus

Complaints:

- Dysphagia (organic, functional)
- Retrosternal pain
- Retrosternal heartburn
- Regurgitation (belching)
- Abundant salivation
- Bad smell from the mouth
- Nausea and vomiting
- Bleeding



Esophagus

History

- Presence of neoplasm, esophageal polyps in the family,
- Chronic toxic consumption: tobacco, coffee, etc.
- Caustic ingestion, voluntary or involuntary
- General or specific infections
- Association of other diseases of possible interest
- esophageal: liver cirrhosis, scleroderma, etc.
- Recent injuries

Esophagus

History (causes)

Irritant esophagitis is produced by repeated reflux of gastric acid, due to:

- Pregnancy, obesity, scleroderma, smoking
- Gastroesophageal reflux disease, fatty foods, chocolate, coffee, alcohol
- Spices, carbonated drinks, mental retardation
- Spinal cord injuries, immunosuppression
- NSAIDs, Ca channel blockers, beta-blockers - chest radiotherapy, repeated vomiting, hiatal hernia, caustics

Infectious esophagitis can be caused by:

- Fungi: Candida, develops when the immune system is suppressed (HIV/AIDS)
- Viral: Herpes virus also develops at the body's immunosuppression, cytomegalovirus.
- Bacterial.

Esophagus

- Objective examination: does not have an important value due to the retrosternal position of the esophagus.
- Of the 4 methods, only **inspection** and **palpation** can reveal cervical tumor formations accompanied or not, by latero-cervical lymphadenopathy or inflammatory reactive processes.

Esophagus

Diagnostic instrumental investigations:

- **Radiography** is useful only in case of perforation, obstruction, hemorrhage
- **Barium examination in double contrast** - when the dysphagia is the first symptom
- **Direct endoscopy** - allows visualization of esophageal lesions
- Emergency endoscopy in severe hematemesis and perforation
- **Endoscopic biopsy** - when the Barrett's esophagus is suspected or cancerous etiology.

Complaints of digestive system diseases

(stomach, duodenum, intestine, liver, gallblader)

- ❖ **Pain** – mucosal irritation, smooth muscle spasm, peritoneal irritation, capsular swelling or direct nerve stimulation
- ❖ **Nausea & Vomiting**
- ❖ **Fever**
- ❖ **Rectal bleeding**
- ❖ **Abdominal distention**
- ❖ **Mass**
- ❖ **Jaundice**
- ❖ **Pruritis**
- ❖ **Decreased appetite, weight loss**
- ❖ **Bleeding**

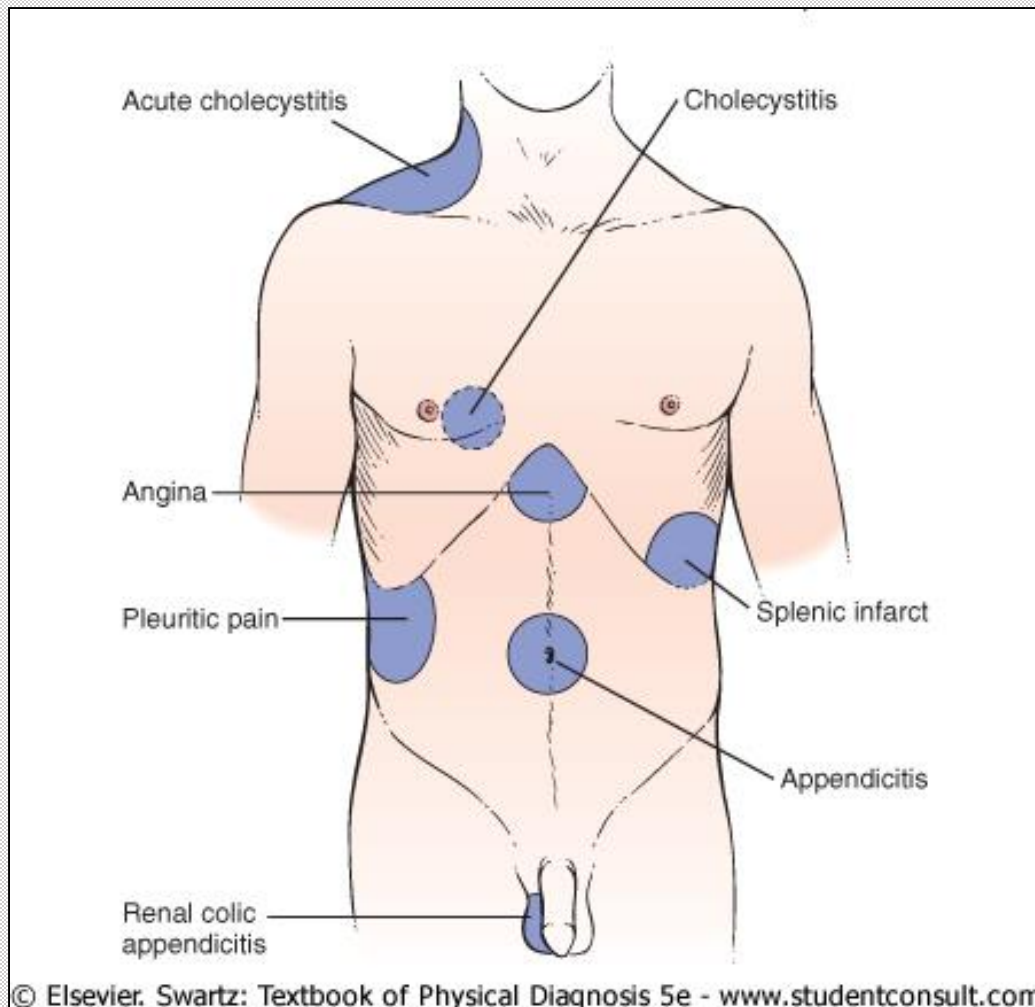
??? on Pain

- ❖ *Where is the pain?, location*
- ❖ *The type of pain, how the patient feels the pain, Is it sharp? dull? burning? cramping?"*
- ❖ *Is the pain continuous? Does it come in waves?*
- ❖ *What are the conditions in which the pain occurs, is related to food ingestion? What makes it worse?*
- ❖ *What makes it better?*
- ❖ *How long have you had the pain?"*
- ❖ *Did the pain start suddenly?"*
- ❖ *Has there been any change in the severity or nature of the pain since it began*
- ❖ *"Has the pain changed its location since it started?"*
- ❖ *"Do you feel the pain in any other part of your body?"*

Pain

- Pain – mucosal irritation, smooth muscle spasm, peritoneal irritation, capsular swelling or direct nerve stimulation
- Acute pain: acute perforation, inflammation, torsion of organ
- Determine location at onset, localization, character, and radiation
- Description of pain: gastric ulcer perforation- burning; dissecting aneurysm –tearing; intestinal obstruction – gripping;
- Referred pain – pain originates areas supplied by somatic nerves entering the spinal cord at the same segment as the sensory nerves from the organ responsible for the pain
- Time of pain : with food –peptic ulcer, 2-3 hours after eating –duodenal ulcer; nocturnal – duodenal ulcer; pain after eating – mesenteric ischemia (abdominal angina)

Common areas of referred pain



Nausea and Vomiting

- Emesis may be caused by irritation of peritoneum: perforation of an organ; obstruction of bile duct, ureter, or intestine; or toxins. Extra abdominal conditions include: CNS conditions, pregnancy, MI, drug toxicity
- *???* : *how long, what color, foul odors, how often, any relation to eating, stool or urine changes, pain in abdomen or chest, fevers, auditory*
- **Clues** : Odor or color to vomitus-acute gastritis causes stomach contents to appear. Biliary colic produces green-yellow vomitus. Intestinal obstruction reveals fecal smelling emesis. Nausea without vomiting is seen in hepatocellular disease, pregnancy, and metastatic disease. Emesis and hearing and tinnitus may be seen with Meniere's disease.

Change in Bowel Movements

??? Acute Diarrhea

- ❖ 1. How long have you had the diarrhea-onset after a meal suggests viral infection or toxin?
- ❖ 2. How many bowel movements daily-multiple movements may mean a bacterial infection?
- ❖ 3. Did the diarrhea start suddenly?
- ❖ 4. Are they malodorous, bloody, watery- watery diarrhea is associated with inflammatory disease of small or large bowel. Bloody diarrhea can be caused by the bacteria shigella or amebiasis.
- ❖ 5. Is the diarrhea associated with abdominal pain, decreased appetite, nausea, vomiting?

Change in Bowel Movements

???

Chronic Diarrhea

- 1. How long have you has diarrhea?
- 2. Do you have diarrhea altering with constipation? -colon cancer or diverticulitis
- 3 Are stools watery? -inflammatory bowel disease & protein losing enteropathies; loose? – diseases of left colon; floating - malabsorption ; or malodorous?
- 4 Is there any blood, mucus, undigested food? - Bloody stool mixed with mucus- inflammatory bowel disease.
- 5. What is color? Any relation to eating and timing?
- 6. How many BM's/day?
- 7. Any association with pain, distention, nausea, or emesis?
- 8. Any weight loss?

Change in Bowel Movements

??? Constipation

- 1. How long constipated, how often do you have BM?
- 2. What is the size? – thin stools associated with rectal cancer;
- Color? – pale stools absence of bile
- 3. Any blood or mucus?
- 4. Are there alternating periods with diarrhea?
- 5. Any flatus? Weight change or appetite change? – thyroid disease.

Rectal Bleeding

- 1. bright red blood (**hematochezia**) – tumors, diverticular disease, ulcerative colitis.
- 2. red blood mixed with stool- inflammatory disease, tumors, or hemorrhoids.
- 3. Black tarry stools (**melena**)-bleeding from above the small bowel caused by stomach tumors or ulcer disease though may also be red
- 4. Silver colored stools (**acholic**)-duodenal cancer with sloughing off of tissue.
- 5. **Tenesmus** – painful, continued straining during stooling caused by lesion in distal rectum or anus
- 6. How long? Any streaking with blood? any mixing with stool? Any rectal sensation?
- 7. Any vomiting, diarrhea, abdominal pain, sweating, weight changes?

Jaundice (icterus)

Think liver disease or obstruction to bile flow; decreased excretion of conjugated bilirubin into bile.

- **????**
- How long? Did it occur slowly or suddenly?
- Any abdominal pain? weight loss? Nausea? Vomiting?
- Any fevers? Chills? Pruritis?
- Any sg of transfusions? drug use? Tattooing? Hepatitis C?
- Any travel abroad? Ingestion of raw seafood?- Hepatitis A
- Changes in color of stool or urine?
- Type of work performed and hobbies – Hepatitis B

- Clues
- 1. Slowing developing jaundice with pale stools-bile obstruction with stones or cancer
- 2. Rapid jaundice with nausea and loss of appetite-liver disease such as viral hepatitis
- 3. Liver enlargement without pain to palpation-liver toxicity as alcoholism or toxic chemical exposure
- 4. carbon tetra chloride and vinyl chloride may cause liver disease from occupational exposure

Abdominal Distension

- May be caused by increased gas in intestine or ascites. Increased gas from malabsorption, irritable colon, or air swallowing (**aerophagia**). Ascites from : cirrhosis, CHF, portal hypertension, peritonitis , neoplasia.

???

- How long? Any relation to eating? Any changes with the passage of gas from above or below?
- Any nausea? Emesis? Weight loss? Appetite change? Bowel changes? Shortness of breath? Abdominal pain?

Clues

- 1. Intermittent distension related to eating –relieved by passage of gas
- 2.Slow distension (ascites)- liver disease or malignancy; with shortness of breath-congestive heart failure; possible -aortic aneurysm

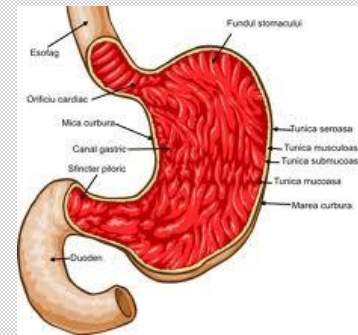
Pruritus-itching

1. Rectal itching (**pruritis ani**)-fistulas, parasites, or diabetes
2. Generalized itching- liver, gall bladder disease
3. Intense generalized itching-lymphoma , Hodgkin's disease, or cancer of GI tract

stomach and duodenum

Complaints:

- Abdominal pain
- Nausea and vomiting
- Upper gastrointestinal bleeding (vomiting with coffee grounds, melena)
- belching
- anorexia
- Weight loss



stomach and duodenum

History

- History of gastro-duodenal disorders: duodenitis, gastritis, ulcer.
- Other favorable morbid associations: chronic liver disease (liver cirrhosis), congestive heart failure, chronic kidney failure, Zollinger Elisson syndrome, chronic pulmonary heart disease, etc.
- Chronic drug use: steroids, non-steroidal anti-inflammatory drugs, antibiotics, etc.
- Chronic consumption of irritants: alcohol, acidic foods, irritants such as tobacco ingestion of caustic substances
- Food profile, eating rhythm, schedule
- Stressful activity

stomach and duodenum

History

- **Hereditary**-collateral antecedent - gastroduodenal ulcer, gastric neoplasm, gastric polyps.
- **Personal data**: the age of the patient can sometimes be correlated with certain digestive diseases (gastroduodenal ulcer at 30-40 years).
- **Gender**: Duodenal ulcer is more common in men.
- **Patient's profession**: irregular meals, stressful work, effort prolonged, postprandial rest, exposure to toxins.
- **The onset of the disease**: it is important to specify the mode of onset, acute or chronic, which were the first manifestations, disgust with some foods, loss of appetite, heartburn, nausea, postprandial vomiting, belching, postprandial bloating, abdominal pain related or not food, type of food, etc.

stomach and duodenum

General inspection

- **Forced position** - imposed by suffering
- Flected** (abdominal colic)



stomach and duodenum

General inspection

The difference between physiognomy and facies

Physiognomy - the structural ensemble of the face

Mimicry - the psychomotor expression of the face, which reflects the emotional state and psychic reactions of the person

Facies is the term used by doctors to characterize the specific appearance of the face in certain diseases. It comes from Latin and means "face". Certain diseases, in addition to pathophysiological changes related to weight, physical condition, mental state, height, sense organs, etc., also cause changes in the appearance of the face. Thus, the facies is characterized by induced and specific changes in certain diseases. The clinician can intuit the diagnosis at a glance - "blinck diagnosis".

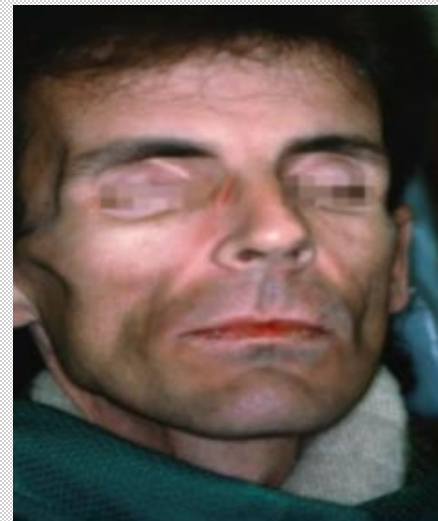!!! We can talk about facies only in sick people (some diseases).

stomach and duodenum

General inspection

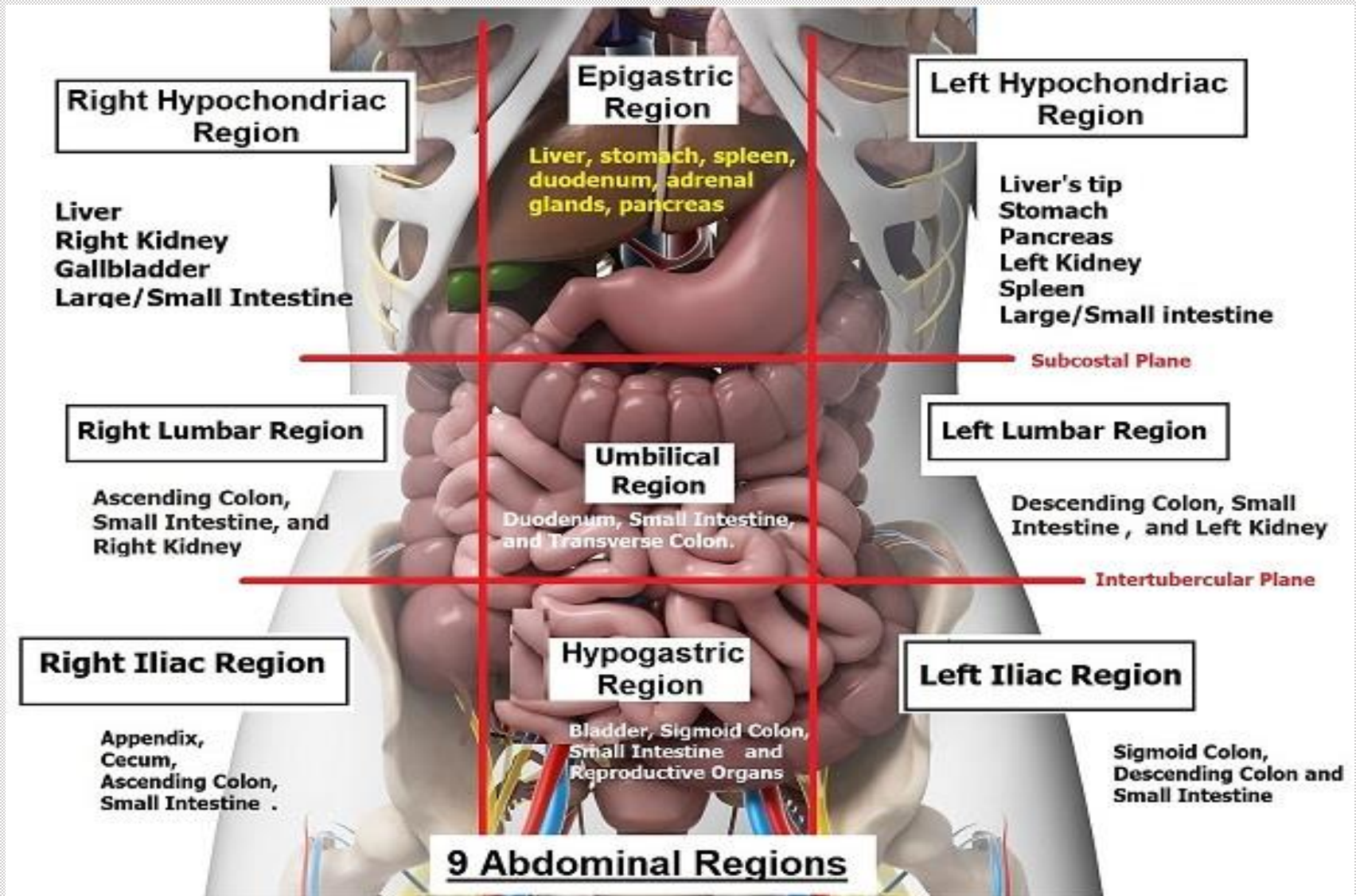
-**Peritoneal facies (Hippocratic)**: in acute peritonitis (by perforations, ulcer, appendicitis, ileus—in the late stages).

- earthy skin, covered with cold sweats*
- clogging the eyes in orbits, dark circles*
- sharp nose, dry lips - anxious look*
- cold and cyanotic ears*

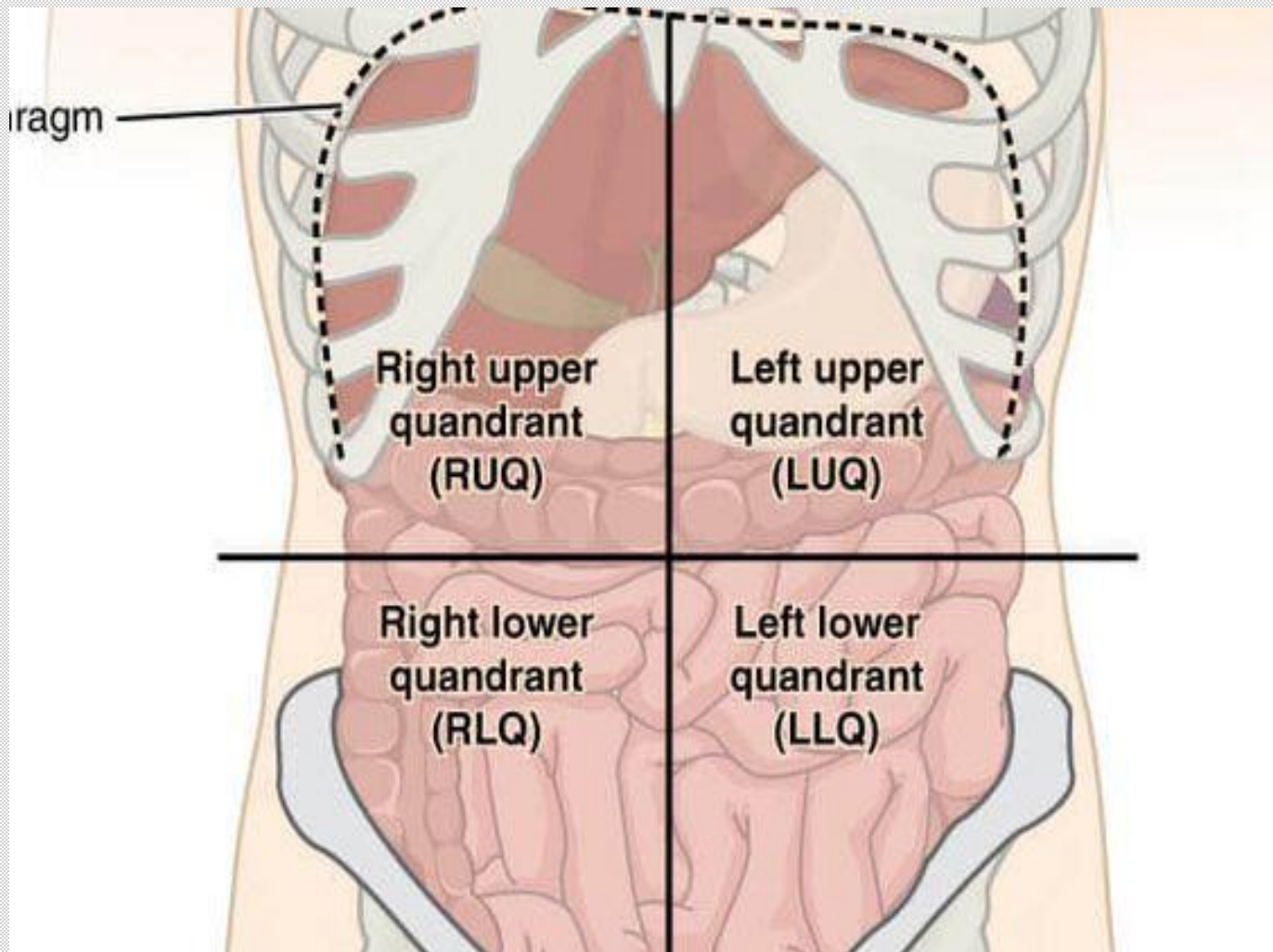


NB !!! Think anatomically

- When looking, listening, feeling and percussing imagine what organs live in the area that you are examining.



The 4 Quadrants of the abdomen



The 7 Quadrans of the abdomen

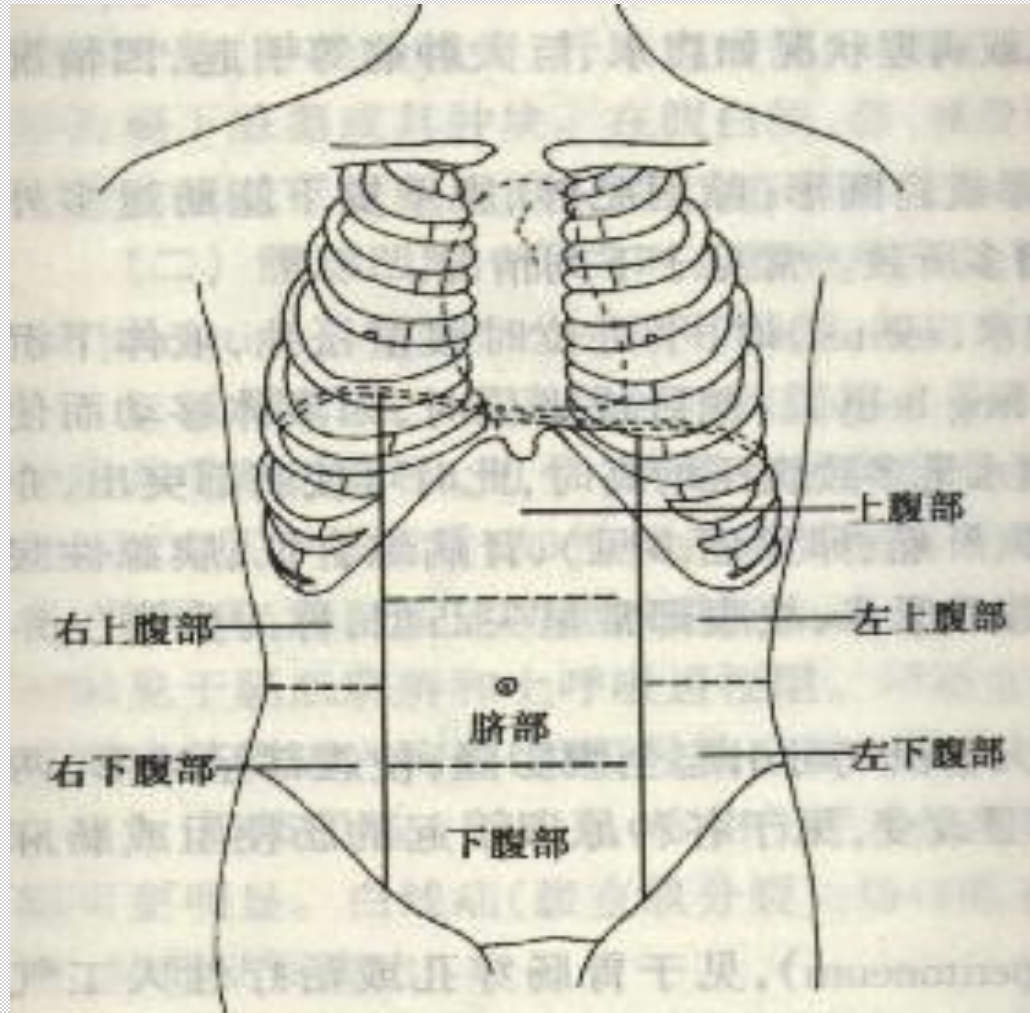


图 2-6-4 腹部体表分区示意图
(七区分法)

General principles of examination of the abdomen



Figure 15.10 The dorsal recumbent position.

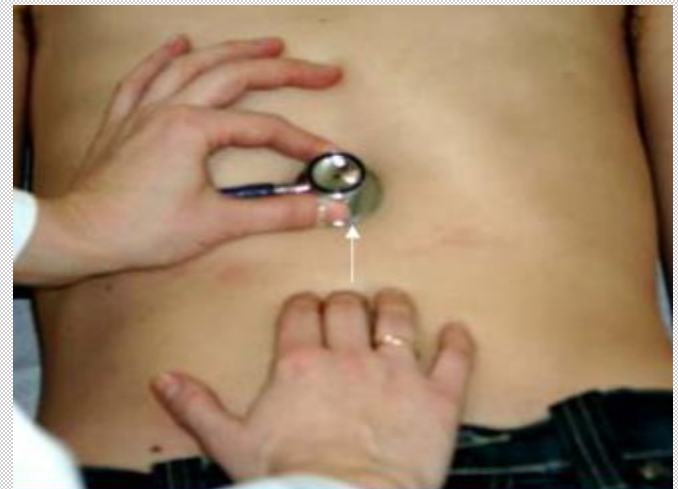stomach and duodenum

- **Inspection** - may rarely show bulges in the epigastrium, especially in giant gastric or peristaltic tumors accentuated in case of pyloric stenosis.
- **Palpation** - **superficial** and **especially deep** put in evidence of increased epigastric pain.
- palpation of painful abdominal points: epigastric,cholecystic, duodenal, pyloric, pancreatic have relevance in certain clinical contexts.
- performing the splash maneuver is of clinical importance when other signs of pyloric stenosis appear (history of duodenal ulcer, food vomiting in large quantities with food ingested for more than 2 days)

stomach and duodenum

- **Percussion:** has no significant value except in the presence of tumors.
- **Auscultation** can be performed at least in the morning on an empty stomach in patients with suspected pyloric stenosis and it is done using the stethoscope to print sequences in the epigastrium.

❖ Auscultation can be used for determining the lower limit of the stomach



stomach and duodenum

PARACLINICAL EXAMINATIONS

General blood test;

General urine test:

Fecal masses (occult blood)

Upper digestive endoscopy

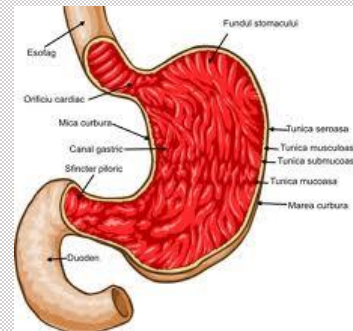
Radiological examination;

Examination of gastric secretion;

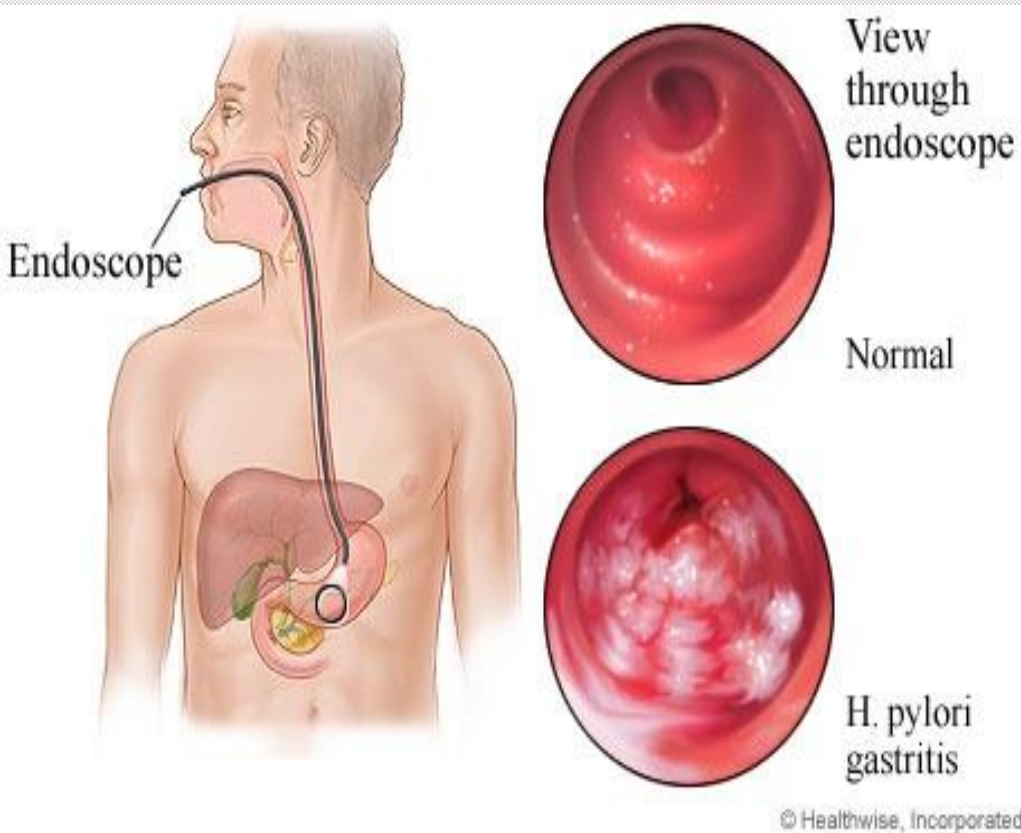
Determination of serum gastrin.

Histopathological examination;

Bacteriological examination (*H. pylori*) ...



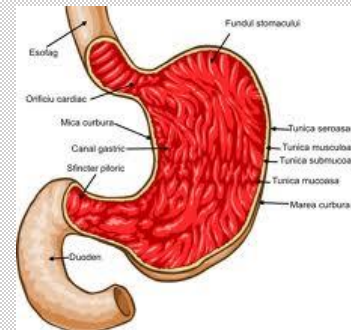
stomach and duodenum



- **Upper digestive endoscopy** - with biopsy, using forceps inserted on the working channel of the endoscope.
- Samples taken can prove (or disprove) the existence of *Helicobacter pylori* infection or the presence of neoplastic cells

stomach and duodenum

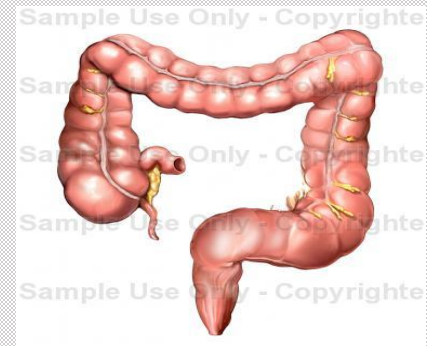
The **radiological examination** - barium transit - is reserved mainly for patients who refuse endoscopic examination or have contraindications; it is less reliable for diagnosis and obviously does not allow the establishment of *Helicobacter pylori* in the stomach, cell metaplasia and, consequently, the administration of an appropriate treatment.



Intestine

Complaints

- Pain
- Intestinal transit disorders
- Flatulence
- Weight loss



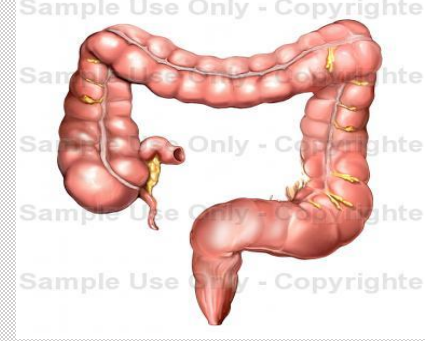
Intestine

History

- Age:** - in children and young people appear more frequently acute enterocolitis and acute appendicitis.
- in adults - chronic colitis
 - in the elderly - constipation, mesenteric infarction
colon and recto-sigmoid neoplasm
 - Colon cancer develops around the age of 50
or after 65 years.

Frequent family predisposition to: ulcerative hemorrhagic colitis (Crohn's disease), ulcerative colitis, colon neoplasm, habitual constipation, etc.

Intestine



History

- **Hereditary diseases:** gluten enteropathy, digestive enzyme deficiencies (lactase, sucrose).
- **Infectious diseases** that can affect the intestine: dysentery, food poisoning, parasitosis, typhoid fever, etc.
- **General, metabolic diseases** that can also affect the intestine: diabetes, heart and kidney failure, etc.
- **Other digestive** diseases that can secondarily affect the intestine: cholecystitis, gallstones, chronic pancreatitis, liver cirrhosis, etc.
- **Abdominal surgery:** total or partial gastrectomies, partial pancreatectomies.

Intestine

History

- **Living and working conditions:** - poor food hygiene and especially unhygienic, can cause food poisoning, acute and chronic enterocolitis;
- **chronic alcoholism** - chronic enteropathy
- **consumption of purgatives** - drug enteropathies
- **lead poisoning** - saturnine colic

Disease history:

- It is important to know the onset of the disease, acute (intestinal perforation, mesenteric infarction, acute appendicitis, intestinal occlusion) or chronic, slow (chronic enterocolitis, colon cancer, ulcerative colitis, intestinal tuberculosis).

Abdominal inspection

Inspection

This is done with the patient lying on his back with his upper limbs along his body; In the conditions in which it is possible to lift the patient, the inspection is also performed under orthostatism.

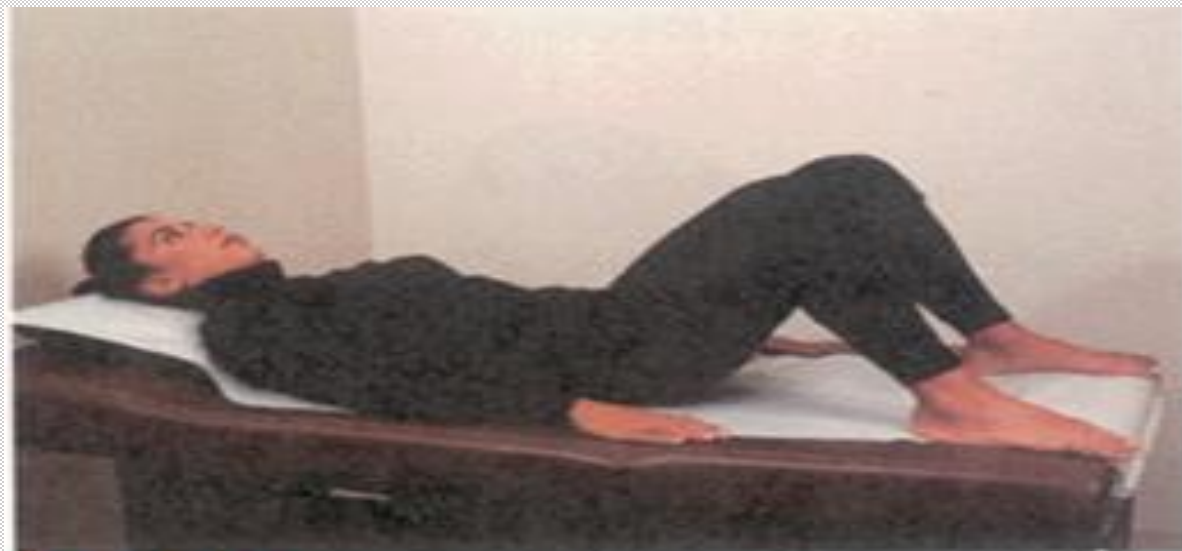

Figure 15.10 The dorsal recumbent position.

Abdominal inspection

Purpose of the inspection:

1. The appearance of the abdominal skin

- skin color**, which may be subicteric or jaundiced in liver cirrhosis, acute, chronic hepatitis, global heart failure
- the presence of **stretch** marks caused by the rupture of elastic and muscular fibers in the dermis in multiparous women (mother-of-pearl appearance), Cushing's syndrome (reddish appearance)
- abdominal collateral circulation** of the cavo-cav type (arranged on the flanks) or porto-cav (jellyfish head, arranged periumbilically and mesogastric)
- abdominal eruptions: bruising on the flanks (Gray Turner sign) in acute pancreatitis, hemoperitoneum and periombic bruising
- the presence of **postoperative scars**

Abdominal inspection

Purpose of the inspection:

2. **The shape** of the abdomen: it can be different depending on age and sex: in children, the abdomen is globular, in adults it is supple, and in the elderly the volume increases.

General or segmental bulges or excavations can be detected.

a. Full abdominal bulging occurs in:

-in obese people by depositing fat in the abdominal wall, in peritoneal effusions (ascites), the abdomen has a globular appearance, relaxed in volume; in ascites with a large amount, the abdomen is typical of the batracian, relaxed on the flanks with collateral circulation and the erasure of the umbilical scar; ascites may occur in case of cirrhosis of the liver with portal hypertension, anasarca (decompensated heart failure), nephrotic syndrome, major deficiency syndrome), peritonitis

-in the intestinal occlusion due to the distension of the intestinal loops above the obstacle

-in the giant ovarian cyst

Abdominal inspection

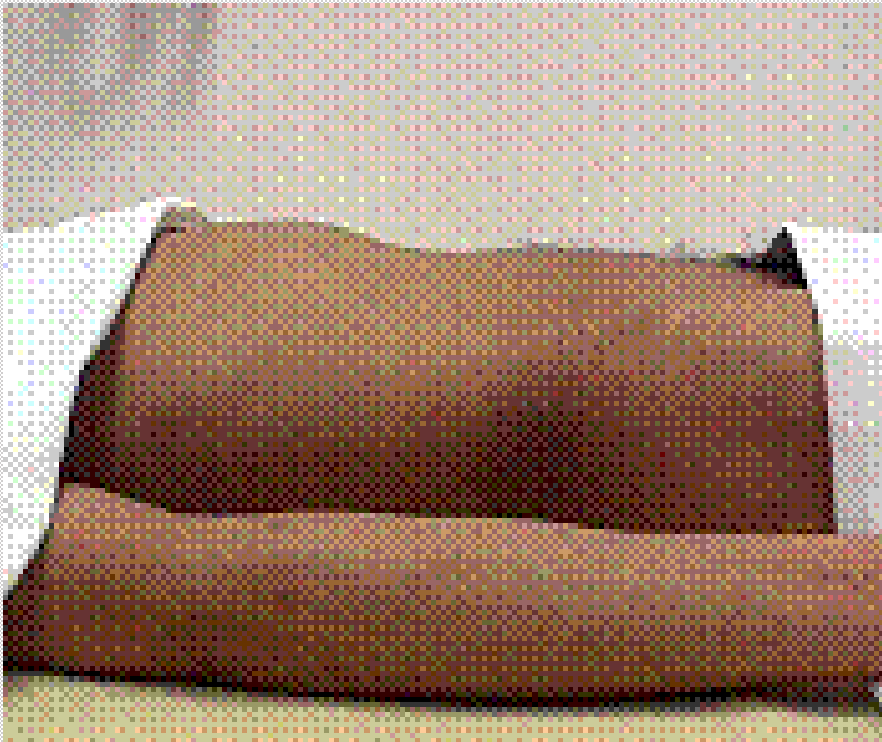Purpose of the inspection:

2. Shape of the abdomen:

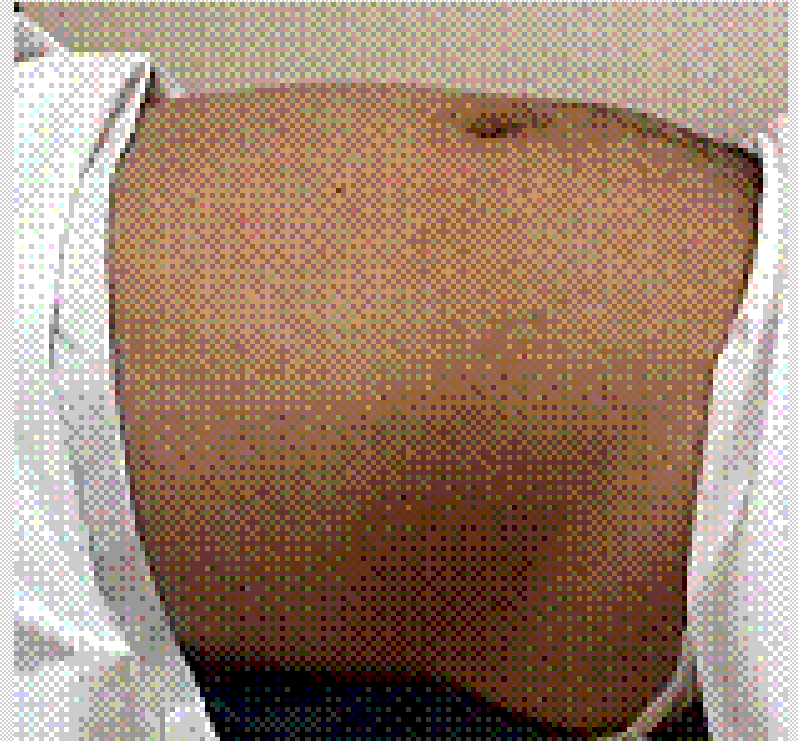b. The regional bulging of the abdomen determines its asymmetry:

- in the right hypochondrium: macronodular hepatomegaly in primary or metastatic liver cancer,
- in the left hypochondrium: giant splenomegaly (leukemias, lymphomas, splenic tumor, splenic abscess)
- at the level of the mesogastric: umbilical hernia, postoperative eventrations
- on the flanks: tumors of the ascending or descending colon (rare)

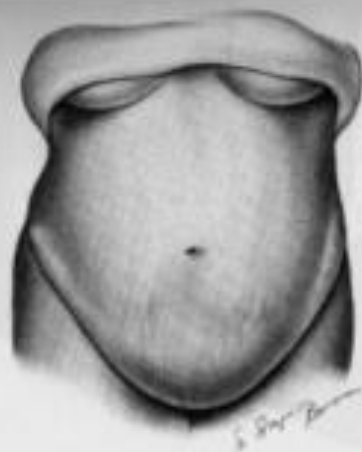Symmetry of the abdomen



Scaphoid or flat in young patients
of normal weight

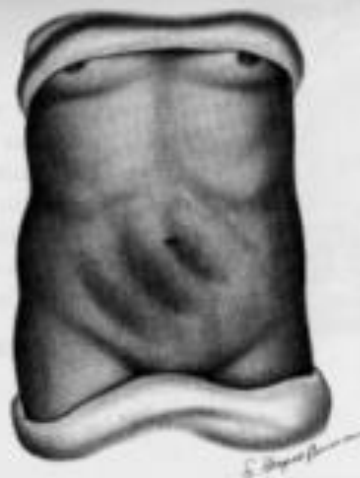

slightly full but not distended in older age
group due to poor muscle tone or in
subjects who are mildly overweight



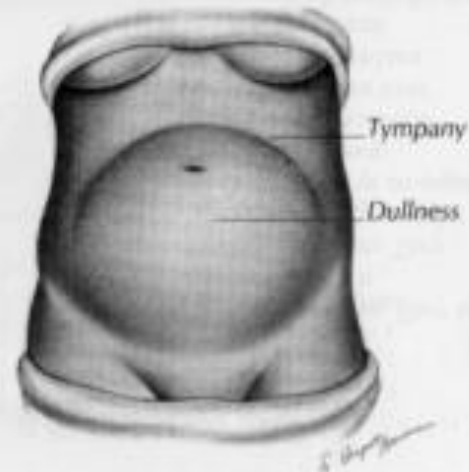
Fat

Fat is the most common cause of a protuberant abdomen and is associated with generalized obesity. The abdominal wall is thick. Fat in the mesentery and omentum also contributes to abdominal size. The umbilicus may appear sunken. The percussion note is normal. An apron of fatty tissue may extend below the inguinal ligaments. Lift it to look for inflammation in the skin fold or even for a hidden hernia.



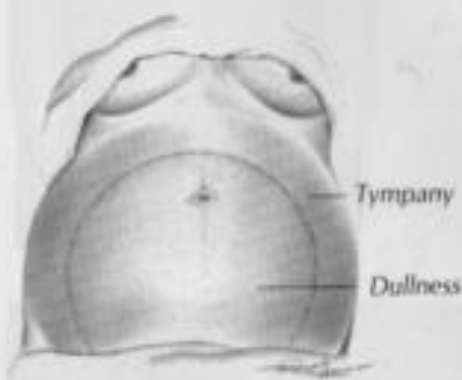
Gas

Gaseous distention may be localized, as shown, or generalized. It causes a tympanitic percussion note. Increased intestinal gas production due to certain foods may cause mild distention. More serious are intestinal obstruction and adynamic (paralytic) ileus. Note the location of the distention. Distention becomes more marked in colonic than in small bowel obstruction.



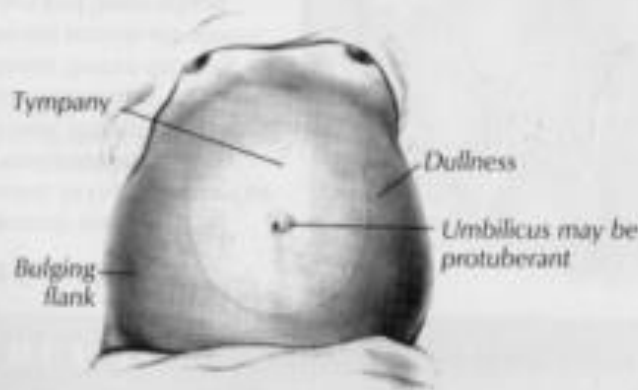
Tumor

A large, solid tumor, usually rising out of the pelvis, is dull to percussion. Air-filled bowel is displaced to the periphery. Causes include ovarian tumors and uterine myomata. Occasionally, a markedly distended bladder may be mistaken for such a tumor.



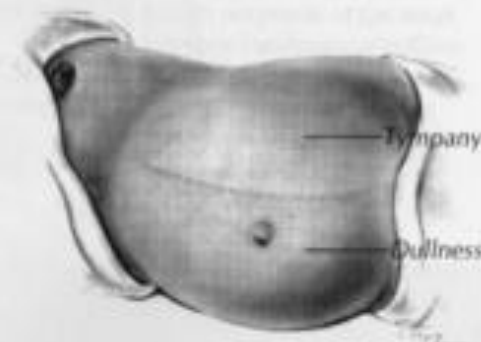
Pregnancy

Pregnancy is a common cause of a pelvic "tumor." Listen for the fetal heart (see pp. 411-412).



Ascitic Fluid

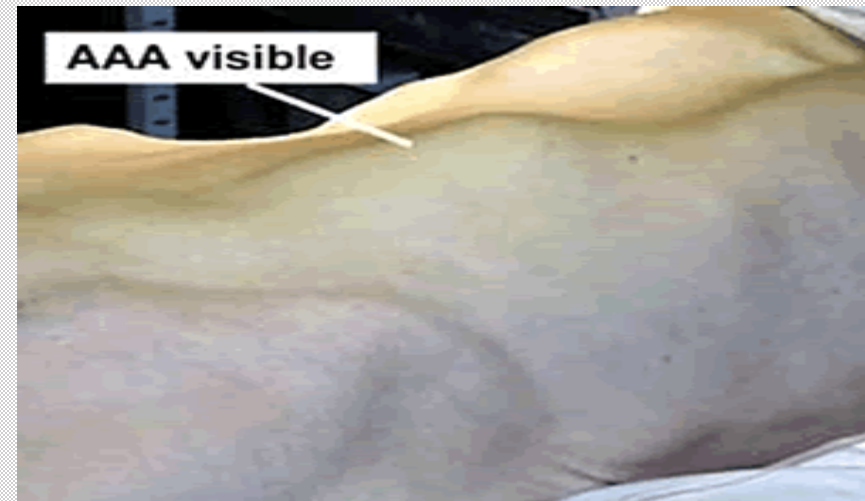
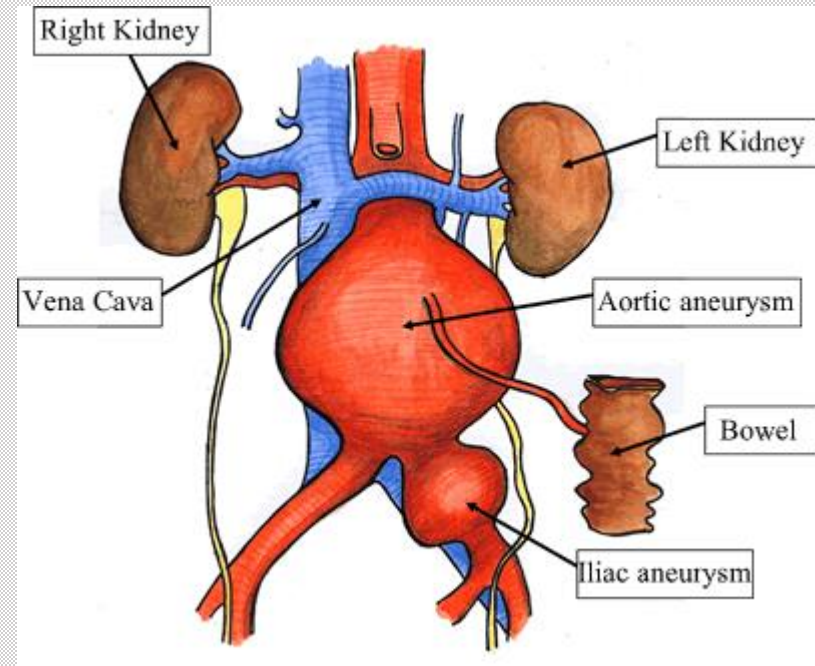
Ascitic fluid seeks the lowest point in the abdomen, producing bulging flanks that are dull to percussion. The umbilicus may protrude. Turn the patient onto one side to detect the shift in position of the fluid level (shifting dullness). (See pp. 350-351 for the assessment of ascites.)



Abdominal inspection

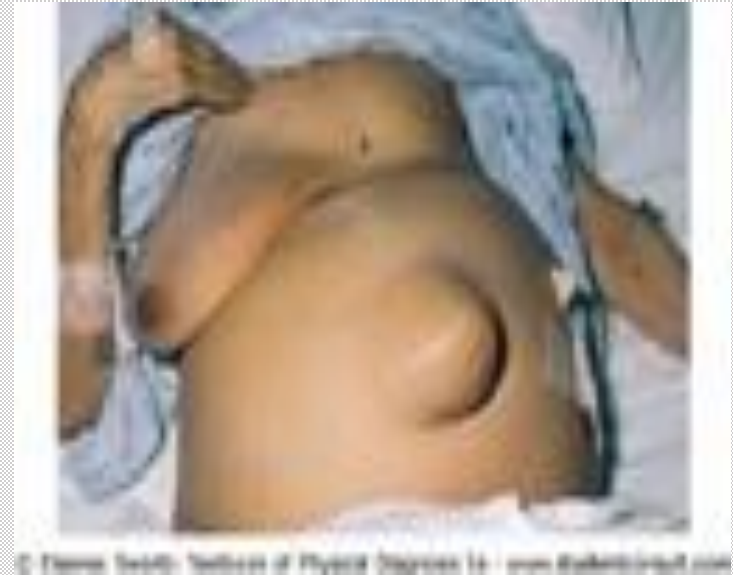Aortic aneurysm

- palpable mass
- The patient feels a pulsation
- Sometimes it can be visible.
- 1 in 10 men > 60 years old has dilated abdominal aorta. About 1 in 100 have a large aneurysm that requires surgery.



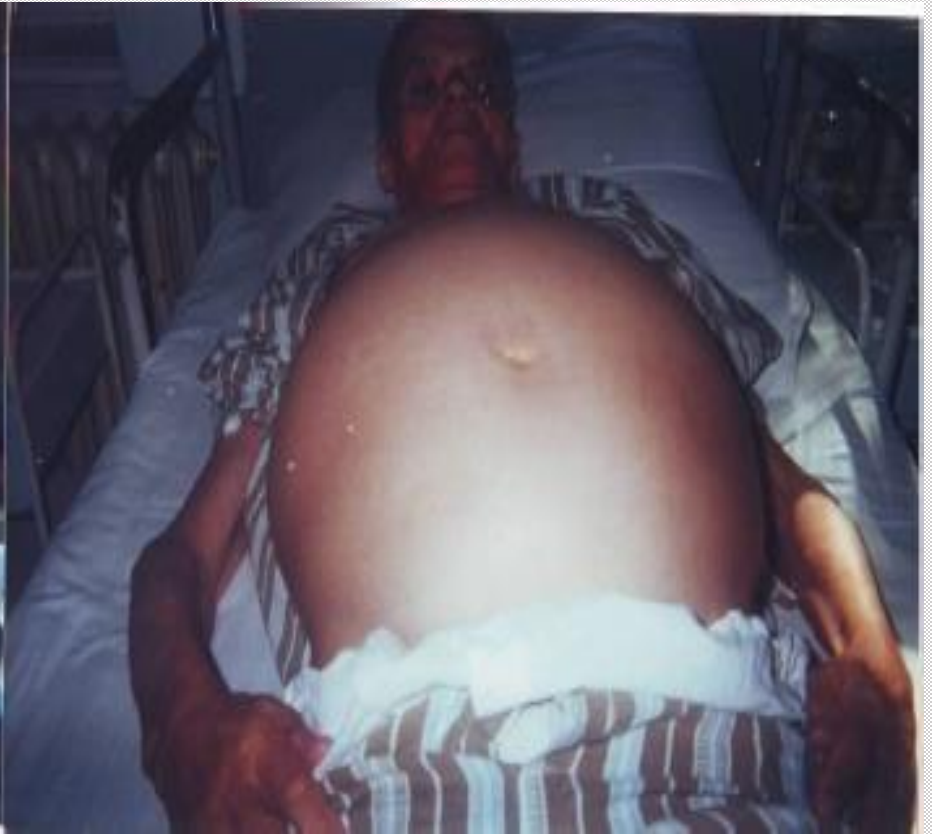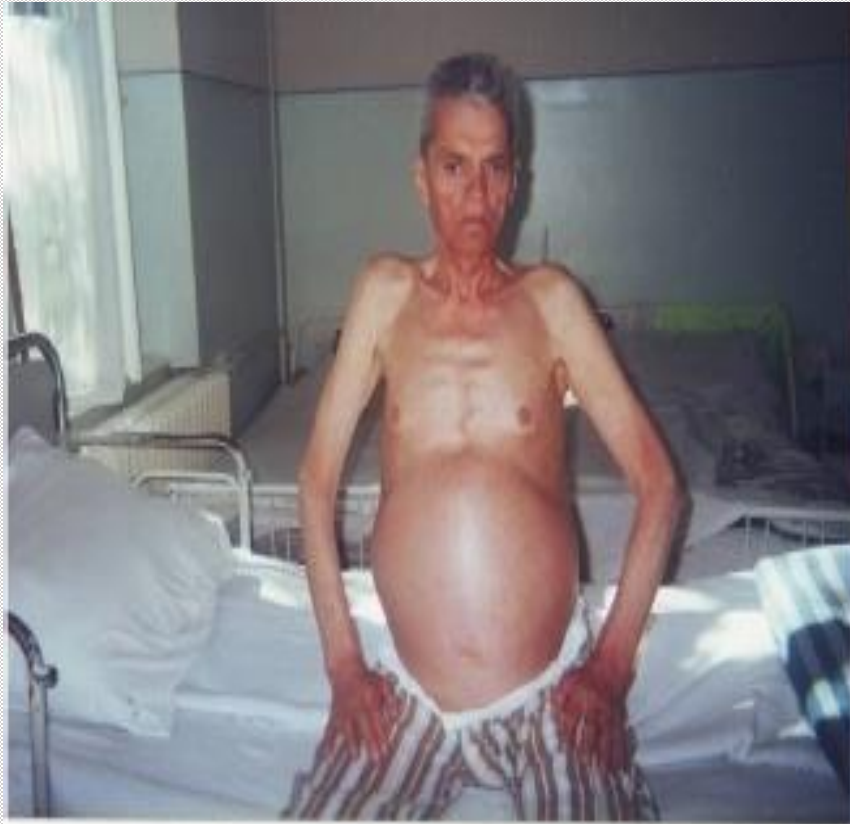Abdominal mass

- Mass may be **hernia** or **neoplasm**
- **Hernia** – protrusion of peritoneal cavity (omentum, intestine, bladder wall). Abdominal hernias may be : inguinal, femoral, umbilical, or internal. (Reducible, incarcerated, strangulated)
- Pulsatile mass in abdomen- think aortic aneurysm



© Thomas Smith: Textbook of Physical Diagnosis 14 - www.studentconsult.com

Abdominal inspection (Ascites)





Michelangelo Merisi, detto il CARAVAGGIO

Milano 1571 - Porto Ercole 610

Medusa

1595-1598 circa

Olio su tavola rivestita di tela
Inventario 1890 n. 1351

Donata nel 1598 al Granduca Ferdinando I dal Cardinale Francesco Maria del Monte e posta nell' "Armeria Nuova" di Galleria senza attribuzione, è citata come del Caravaggio nell' inventario del 1631, abbinata ad un' armatura persiana indossata da un manichino su cavallo di legno.

Medusa

ca. 1595-1598

Oil on canvas-covered panel
Inventory 1890 no. 1351

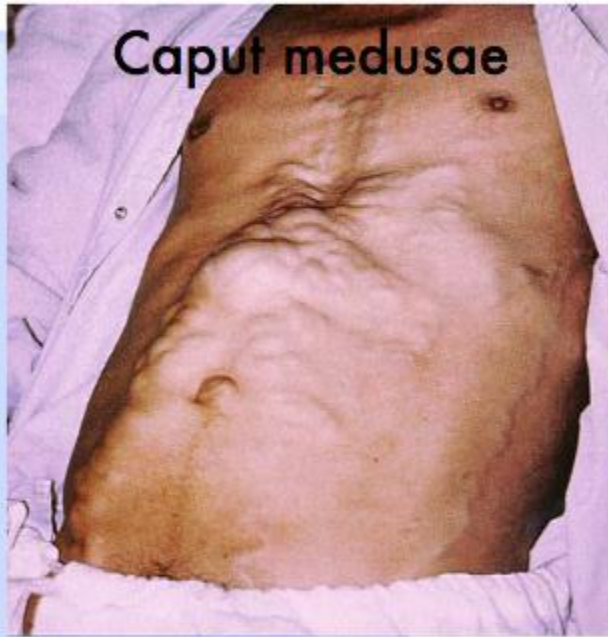
In 1598 Cardinal Francesco Maria del Monte gave this painted shield to the Grand Duke Ferdinando I. It was put in the "Armeria Nuova" of the Uffizi Gallery, without any attribution, near a figure dressed in Persian armor mounted on a wooden horse. In the 1631 inventory it was listed as a work by Caravaggio.



SHOT ON MI 8 SE
AI DUAL CAMERA

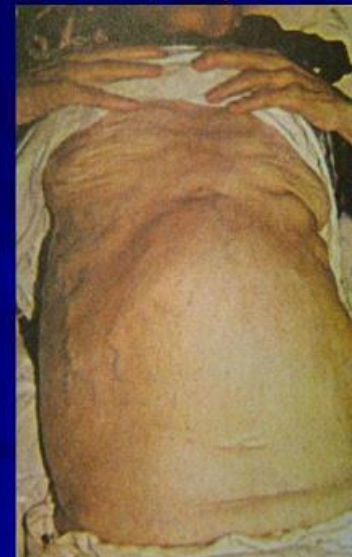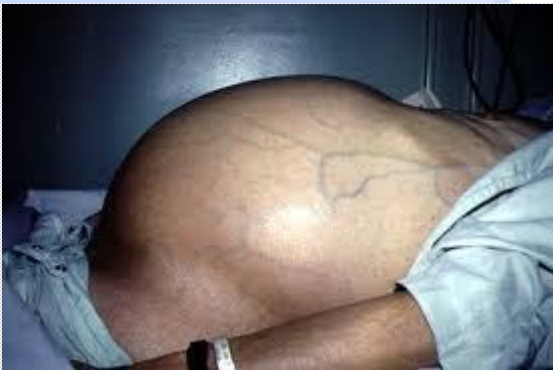●●● Case

Very rare!



Abdominal inspection

Cirrhosis - ascites, caput Medusae

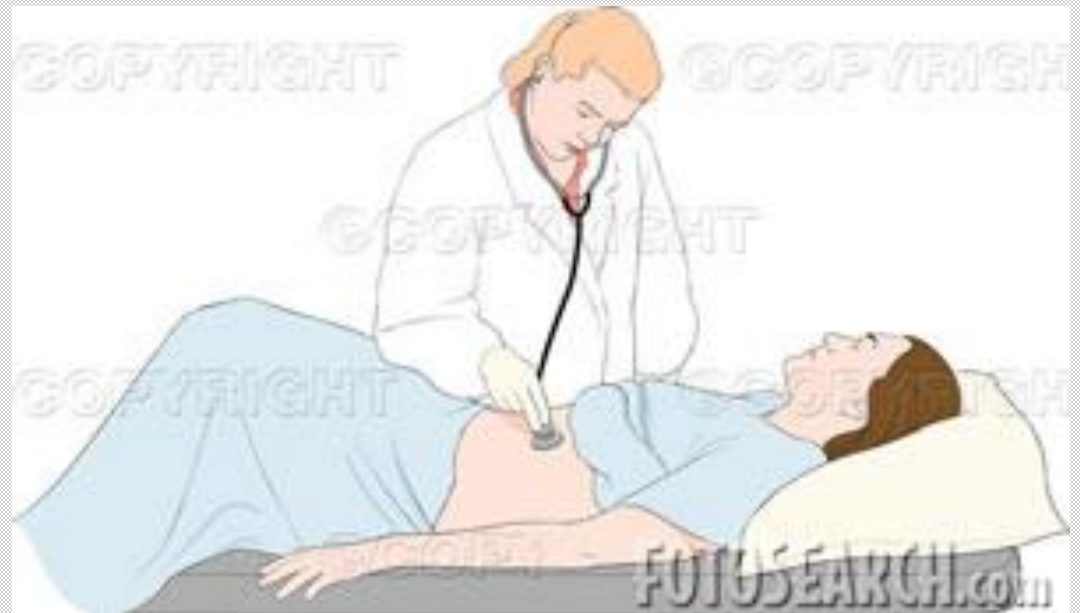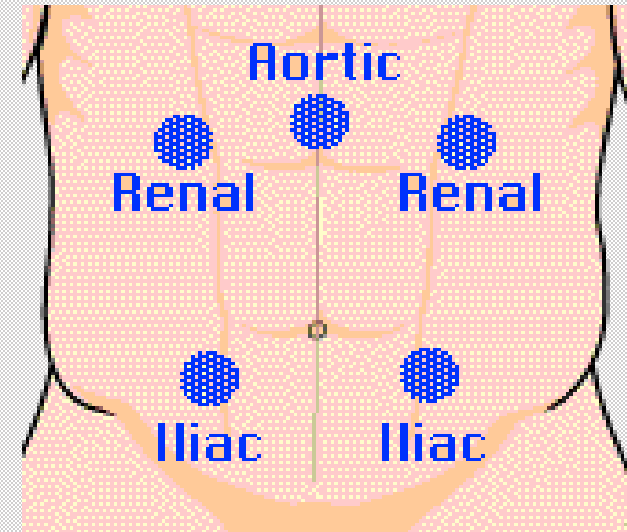


Abdominal auscultation

To determine:

- intestinal movement
- vascular noises (bruits)
- rubs (on the liver and spleen)

- (can be used for determination lower limit of the stomach)



Abdominal auscultation

- Normally, listening to the abdomen with a stethoscope highlights the presence of hydroaerial noises caused by intestinal peristalsis.
- Decreased intestinal peristalsis occurs in acute peritonitis, leading to extinction in paralytic and dynamic ileus (abdominal silence)
- Intensification of intestinal peristalsis occurs in gastroenteritis, the initial phase of occlusion (Köenig sign).
- A systolic murmur in the supraumbilical area may be determined in the case of an abdominal aortic aneurysm and a systolic murmur in the right or left hypochondrium in the case of renal artery stenosis.

Palpation of the abdomen

- It is the most important method for the clinical examination of the abdomen because it detects changes in the wall, abdominal contents and changes in pain.
- Palpation is done with the patient lying on his back, relaxed, with his lower limbs slightly bent and the examiner placed to the patient's right.

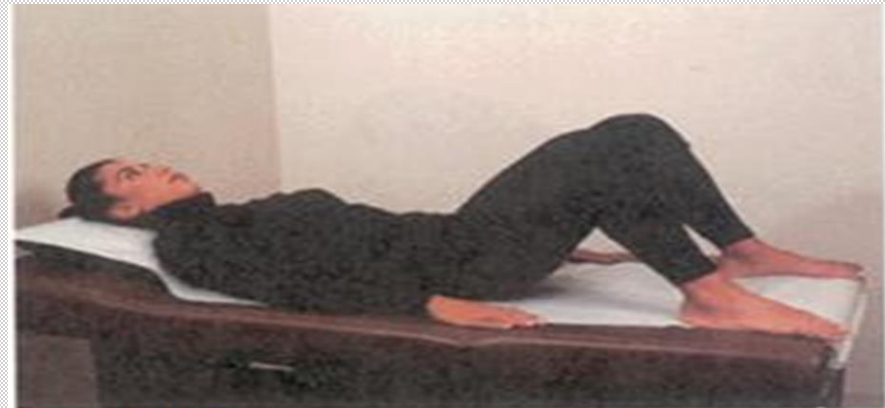
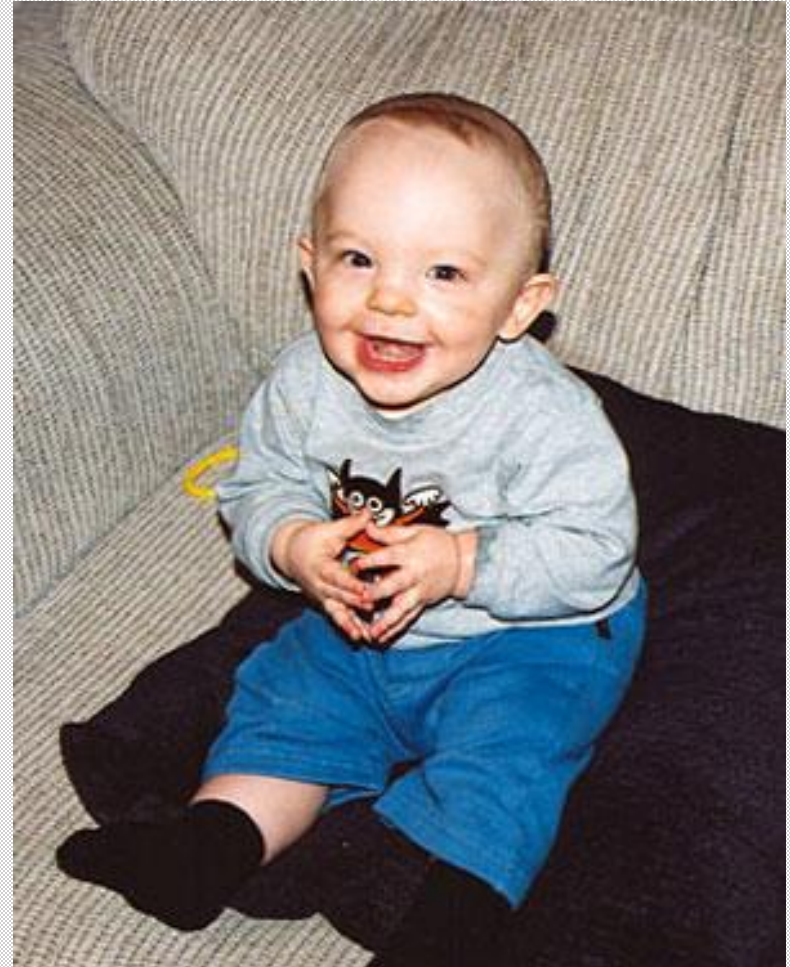
Figure 15.10 The dorsal recumbent position.

Palpation of the abdomen

Palpation can be done **single-handedly** or **bimanually**.

Abdominal palpation is **superficial and deep**

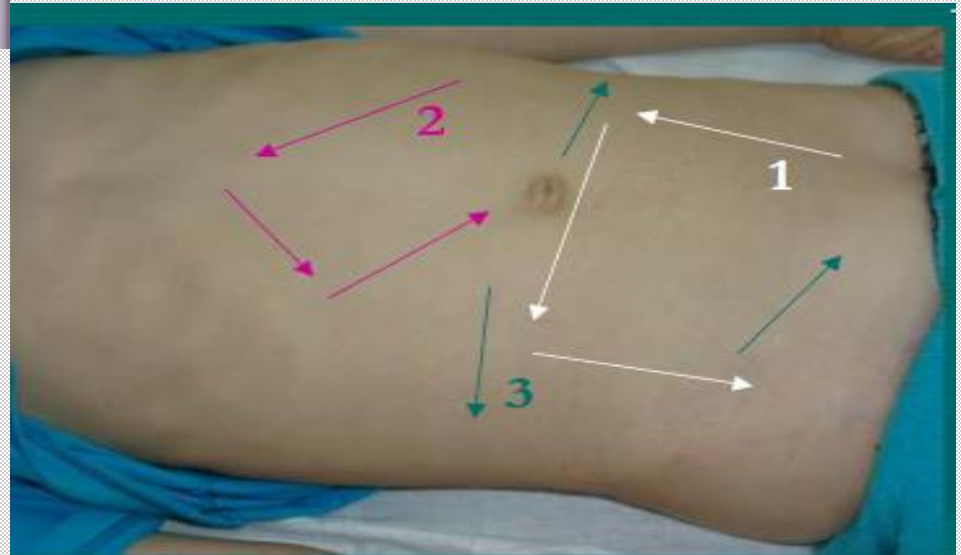
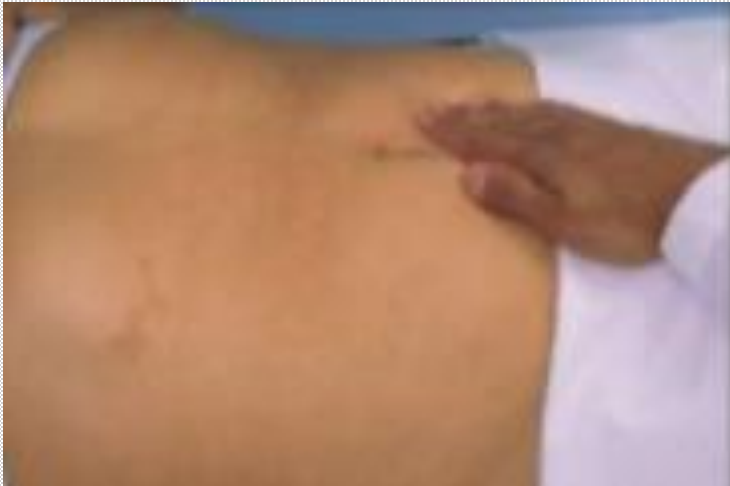

Palpation of the abdomen

Superficial palpation

- May be determined: lipomas, tumors, superficial inflammatory processes sometimes overlying the organs concerned (liver abscess with superficial reaction).
- Cutaneous hyperaesthesia is an important sign in the detection of peritoneal irritation in the early stages of acute peritonitis by inflammation of an abdominal organ (acute appendicitis, cholecystitis, perforated ulcer). It is highlighted by walking your fingers very finely on the surface of the skin.
- Palpation of the wall muscles assesses its degree of development, the presence of hernia points or tumors. In the presence of hyperesthesia, concomitant muscle contracture can be seen, a sign called muscle defense that occurs in peritonitis. If the muscle contracture is generalized, the abdominal wall is rigid as a board and is called the wooden abdomen.

Superficial palpation of the abdomen



Palpation of the abdomen

Deep palpation (by Obraztsov-Strajesco, by sliding)

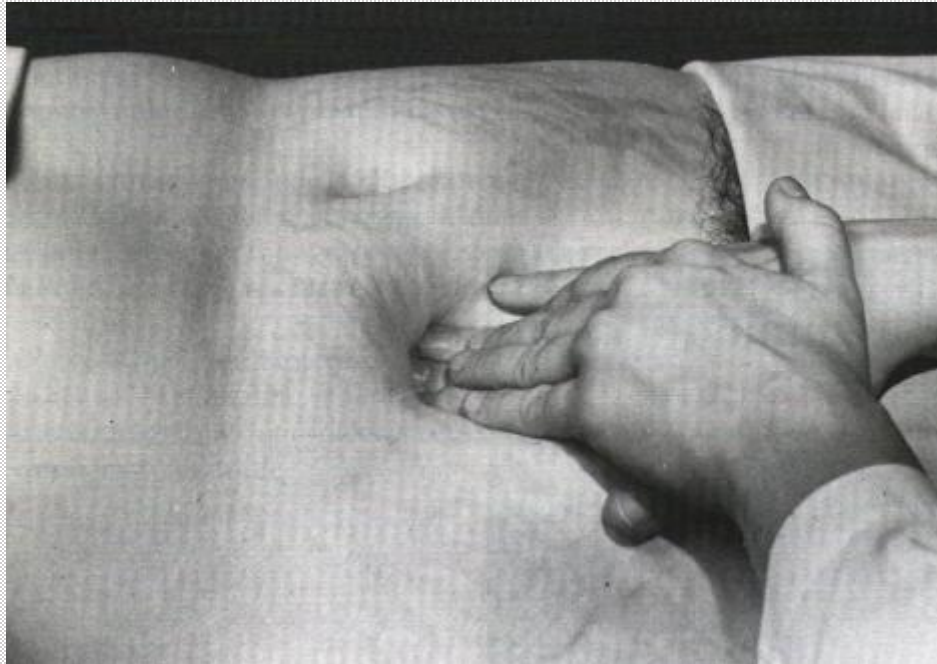TECHNIQUE:

- ❖ is achieved by applying the palm on the abdominal wall, creating progressive pressure, while the patient breathes normally,
- ❖ or palpation by sliding, which initially penetrates with the fingertips, progressively depressing the wall, the patient being asked to inhale slowly and deeply, the examiner's hand sliding deeply with the movement of the abdominal wall that rises during inspiration.

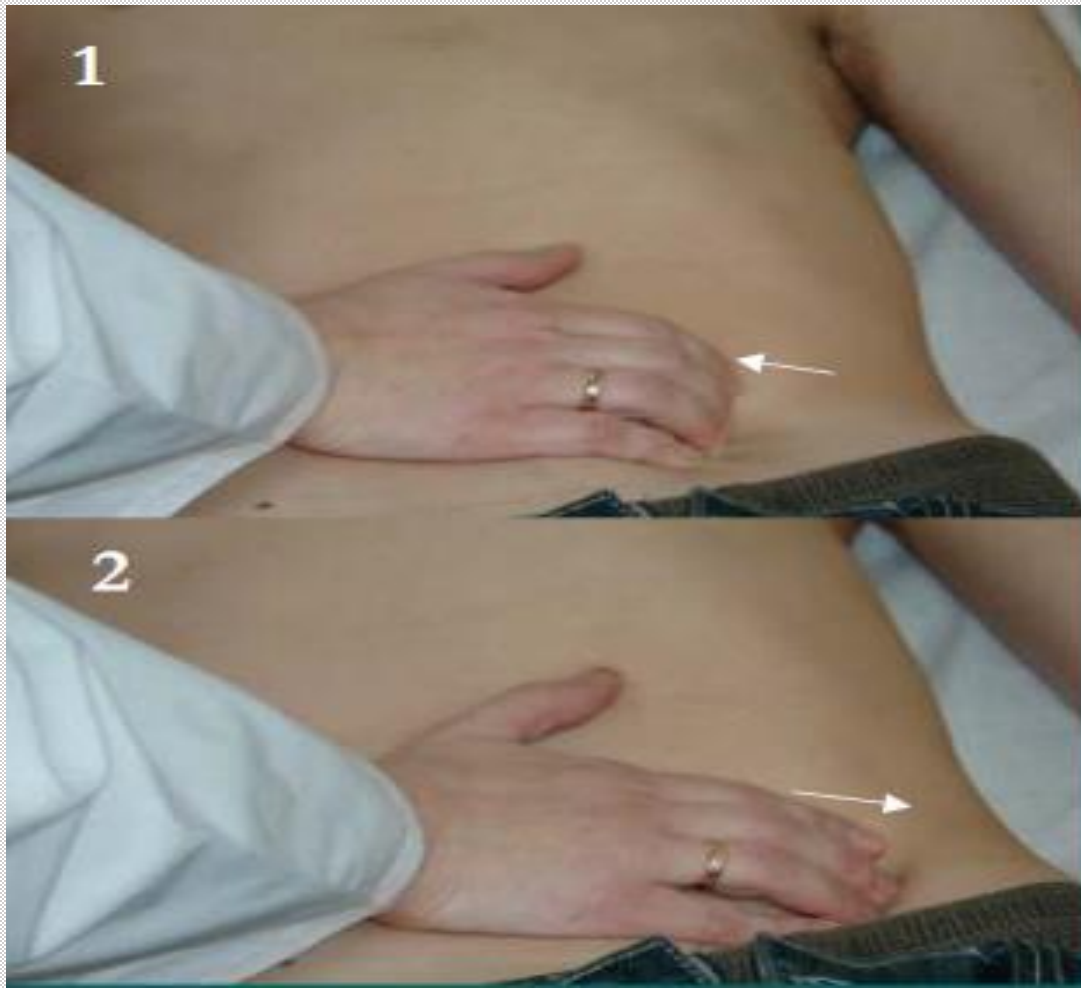
!!!. It is advisable to palpate gently and start from the area as far away from the painful region as possible.

- ❖ It can be executed in clockwise or counterclockwise order. Palpation usually begins in the left iliac fossa following successively the topographic areas: left flank, left hypochondrium, epigastrium, right hypochondrium, flank and right iliac fossa, hypogastrium, mesogastric (1. large intestine (sigmoid, descending colon), 2. large intestine (cecum, ascending colon, transverse), 3. stomach, Duodenum, Liver, spleen

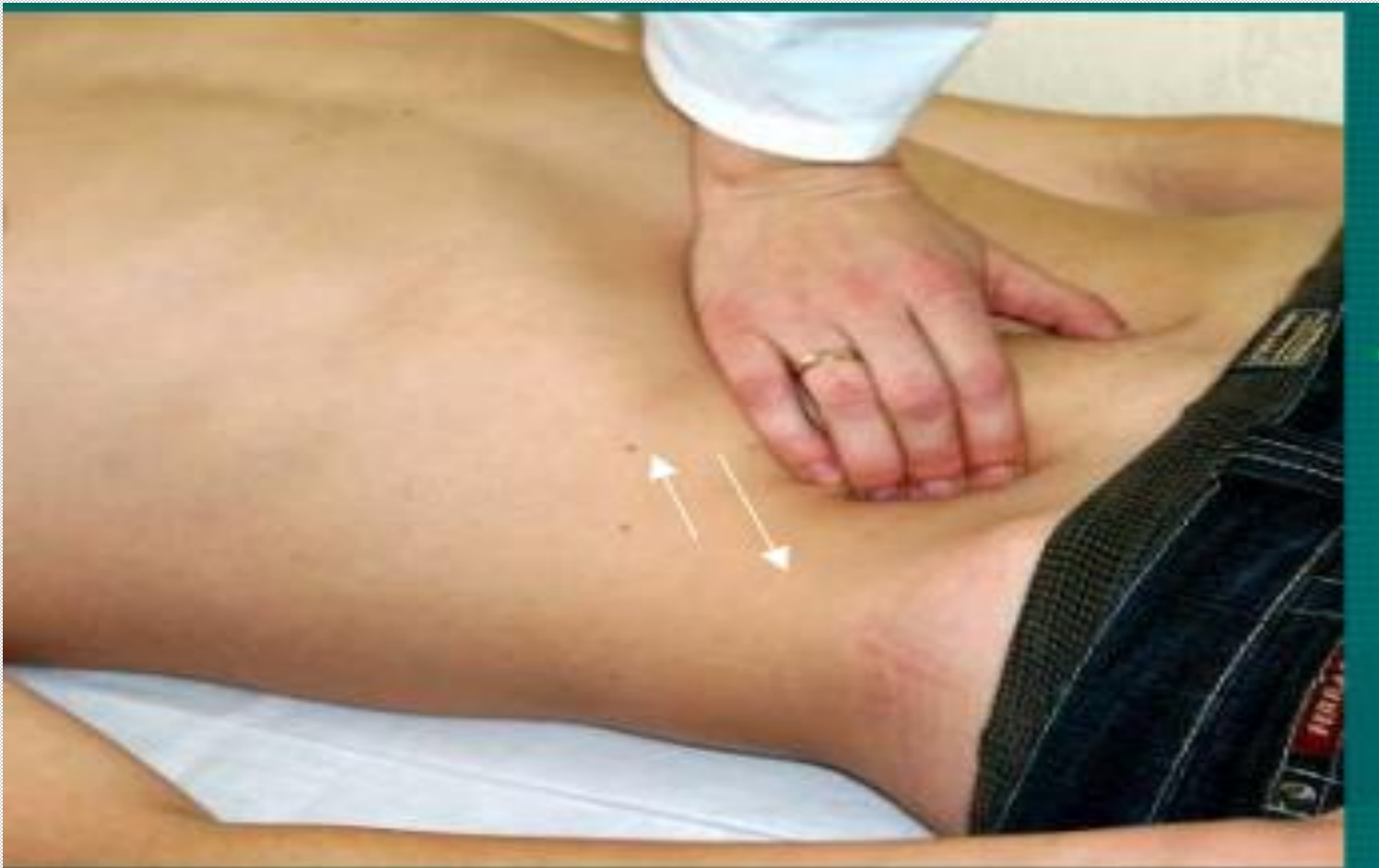Bimanually deep palpation of the abdomen



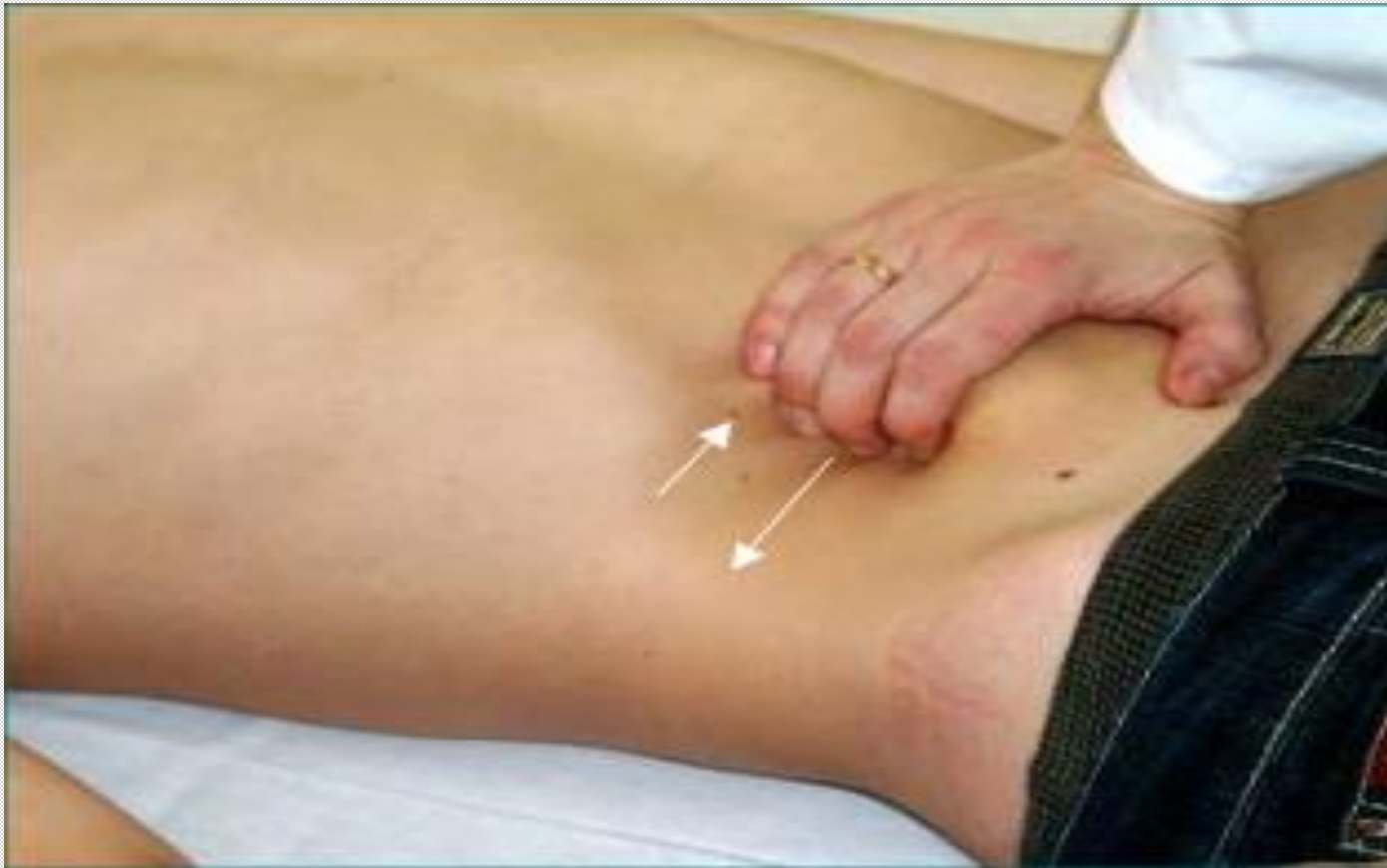Deep palpation of the sigmoid



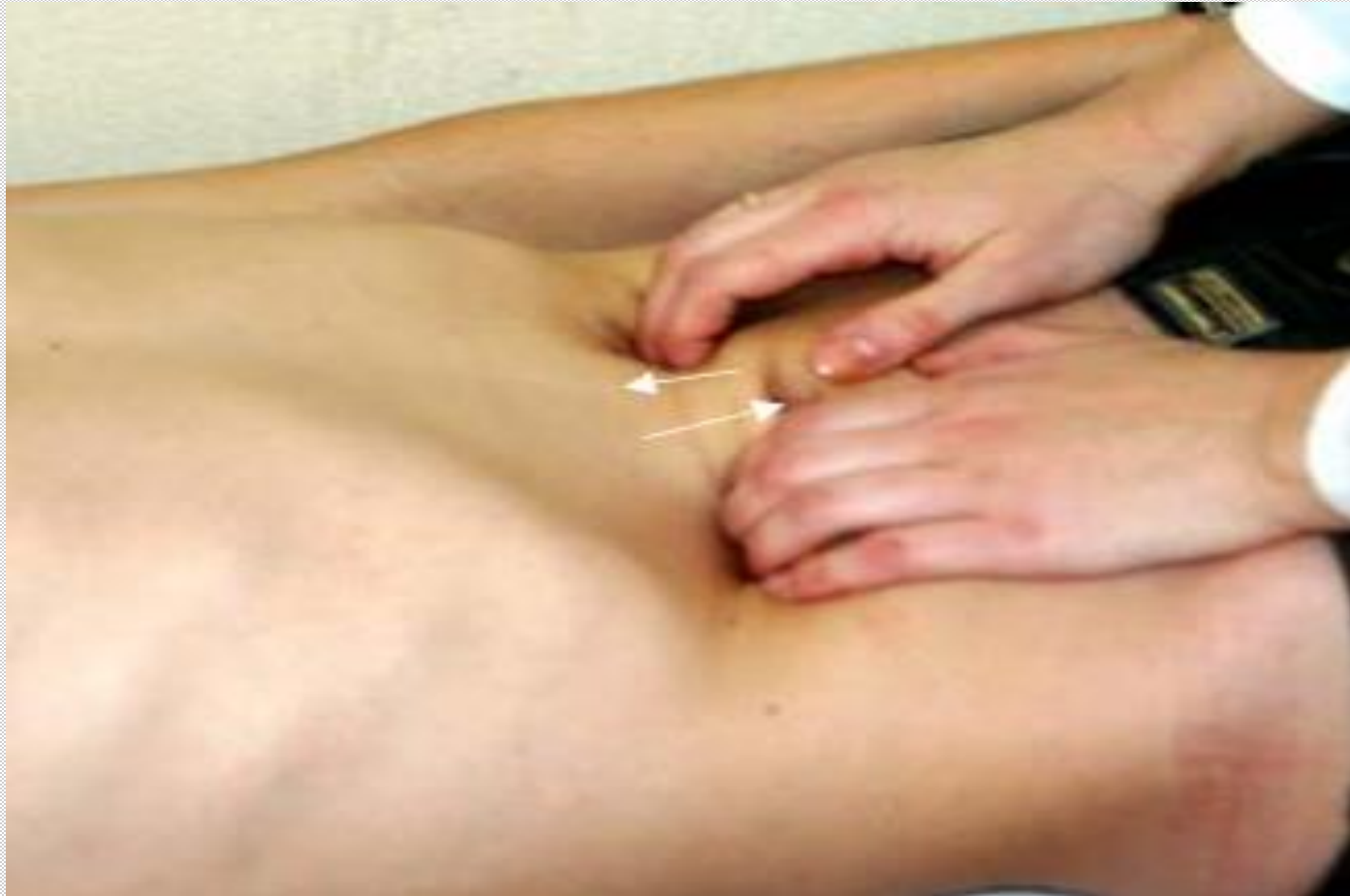Deep palpation of the cecum



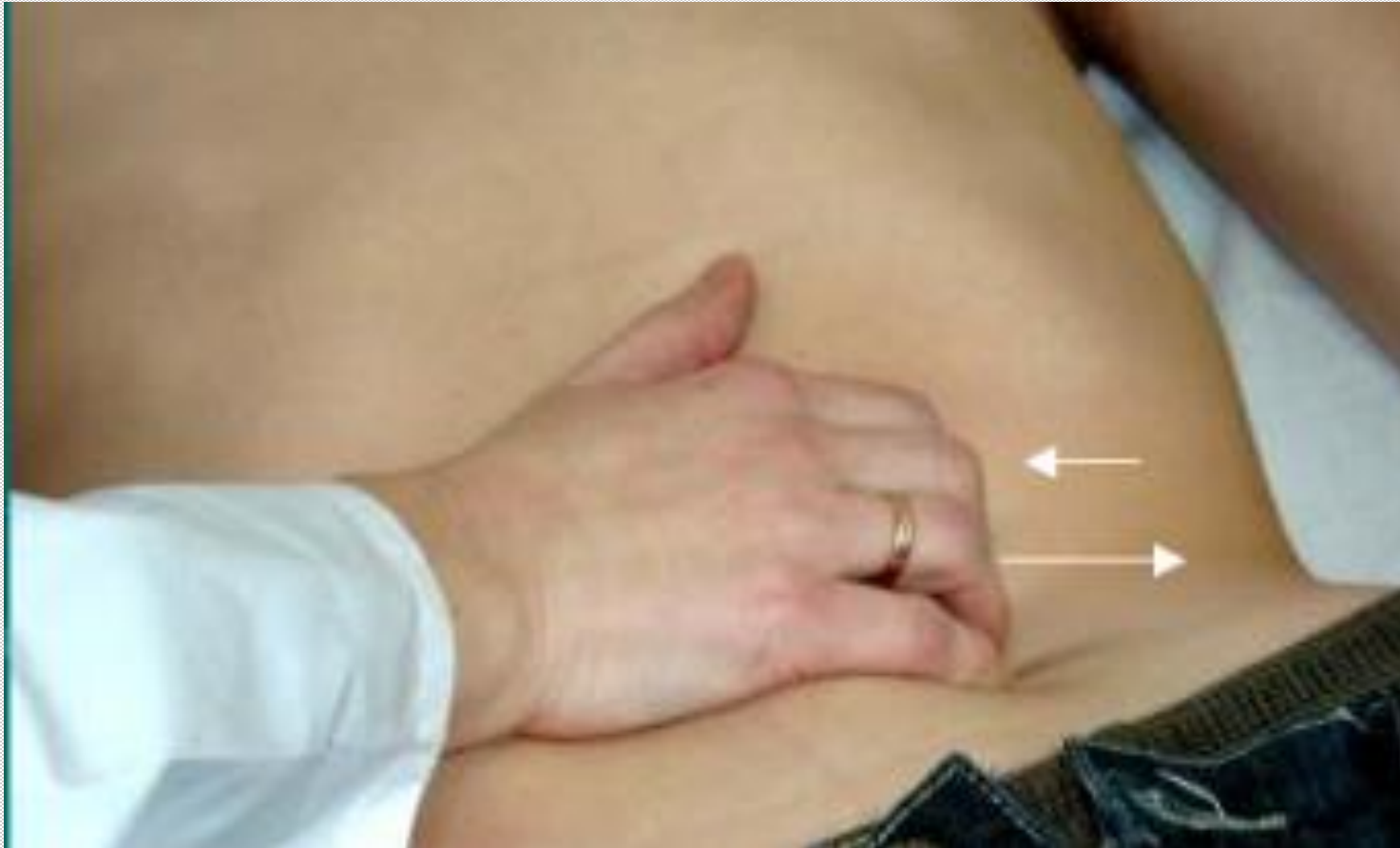Deep palpation of the ascending colon



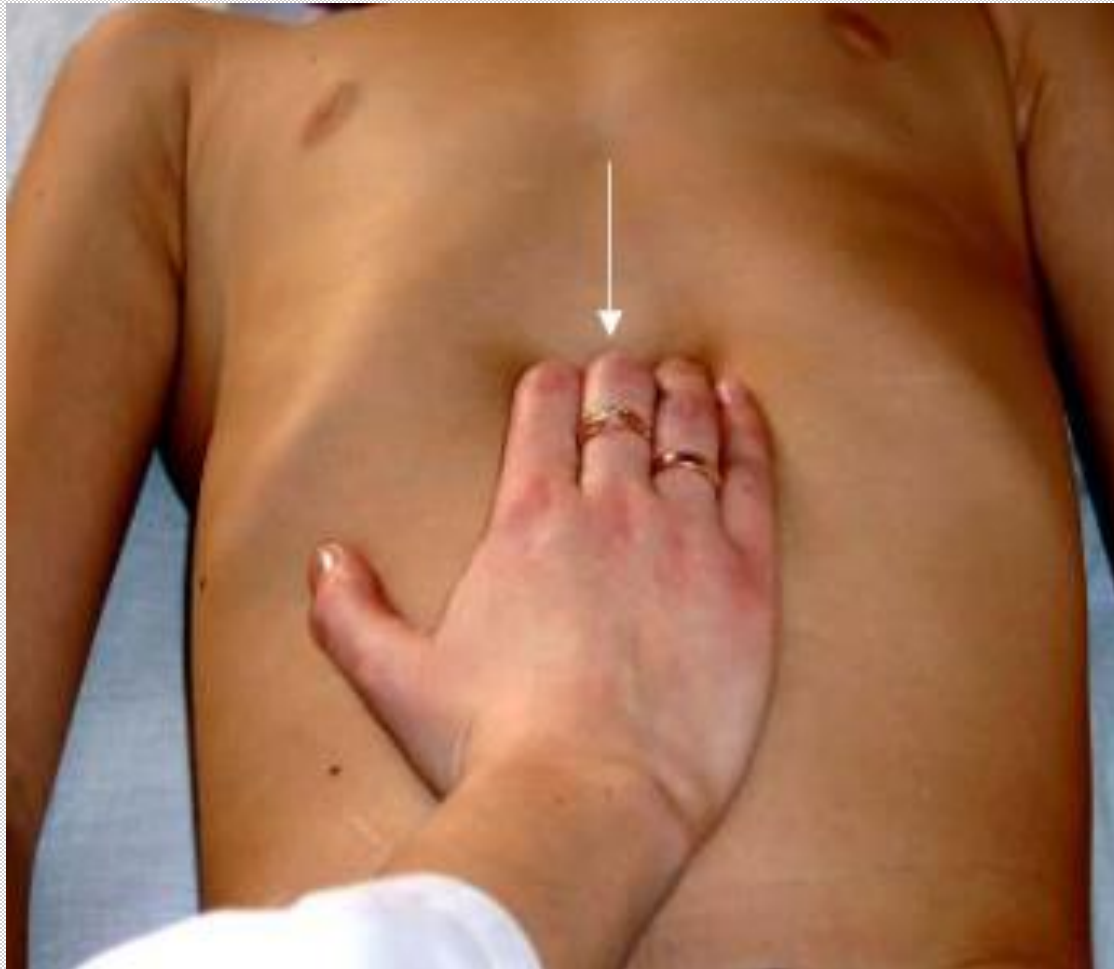
Palpation of the transverse colon



Deep palpation of the descending colon



Deep palpation of the stomach



Palpation of the abdomen

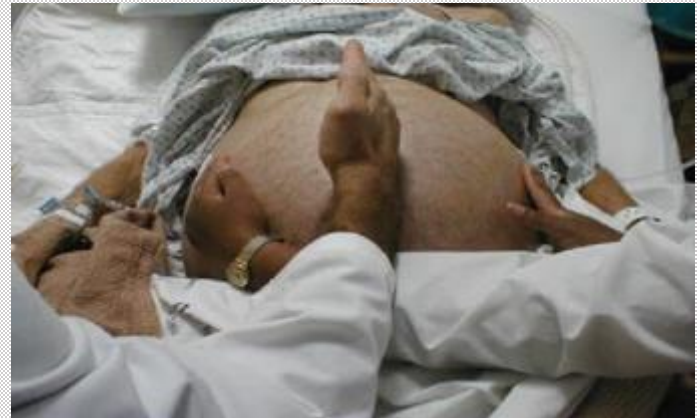In case of detecting a tumor, it will be appreciated:

- Topographic location
- Form
- Size (in cm)
- Mobility (presence or absence of adhesions to superficial or deep palpation)
- Consistency
- Sensitivity
- Participate in breathing movements

Palpation of the abdomen

In the case of the presence of ascites, it is necessary to perform two examination methods:

- **Wave sign**: the examiner places the palmar face of one hand at the level of one flank, and with the fingers of the other hand performs rhythmic percussions in the other flank; the percussion wave transmitted through the ascites fluid will be felt as a wave or wave on the opposite side



- **Palpation by baling**: it is used in cases where a tumor formation is palpated in an abdomen relaxed by the presence of ascites. The maneuver is performed by sudden pressure on the tumor formation (liver, spleen) which sinks into the liquid immediately returning to its initial position - **the sign of the ice cube in a barrel of water**.

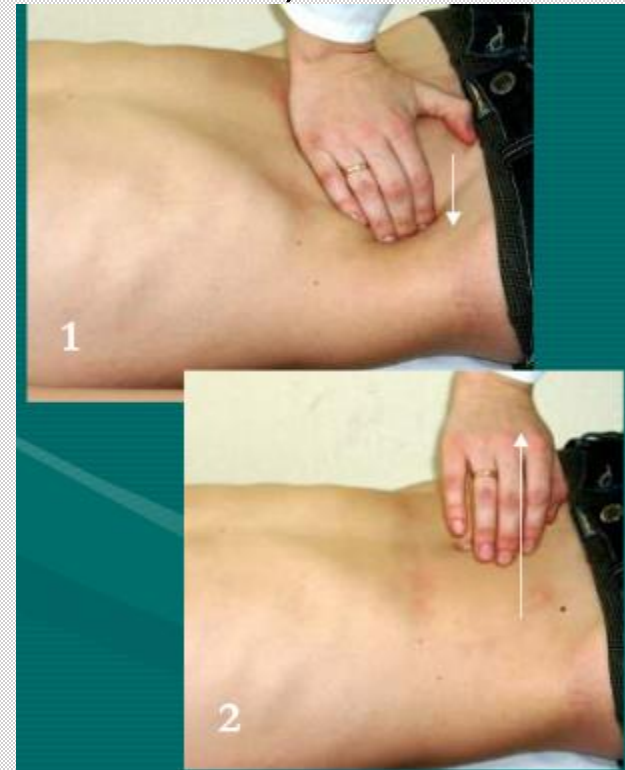Palpation of the abdomen

Assessment of the pain caused - is done by examining the abdominal pain points or by means of pain-provoking maneuvers.

- The abdominal pain points are: solar, epigastric, cholecystic, appendicular, renoureteral and are sometimes significant in affecting the respective organs.

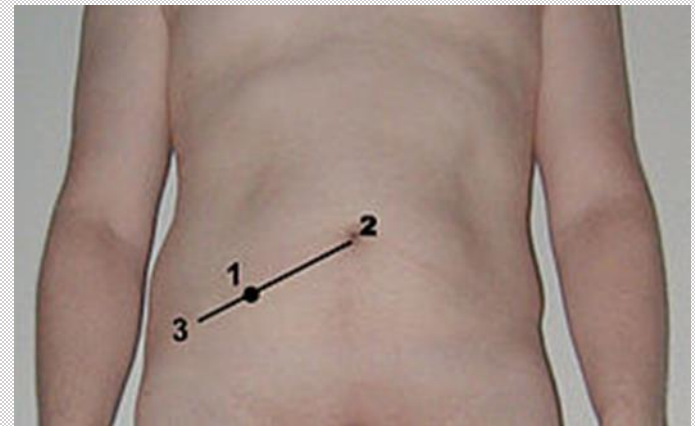
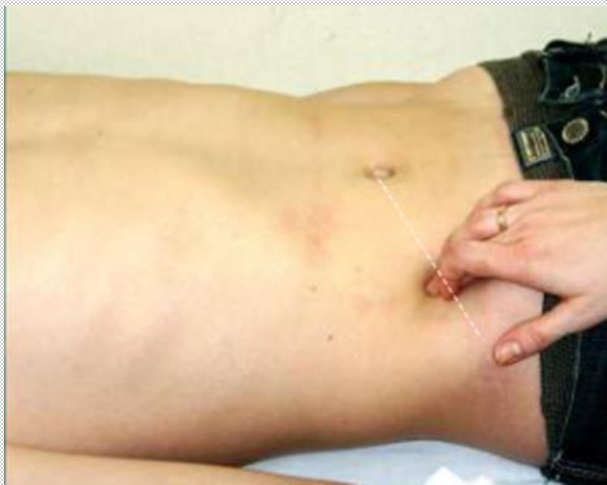Challenge maneuvers are used especially in cases of peritoneal irritation, the most important being:

Blumberg maneuver - the examiner's hand performs an increasingly deep pressure, after which it is raised abruptly; at the time of lifting there is a sharp pain caused by irritation peritoneal



Palpation of the abdomen

- **Rowling maneuver** - compresses the descending and transverse colon in antiperistaltic direction obtaining a sharp pain at the distension of the cecum and the appendix - sign of acute appendicitis
- **Murphy maneuver** - consists in placing the examiner's hand in the cholecystocolodocian area below the costal rim on the medioclavicular line; inviting the patient to take a deep breath, when the gallbladder is pushed into the examiner's hand, a sharp pain is caused.
- **McBurney's point** (appendicitis)

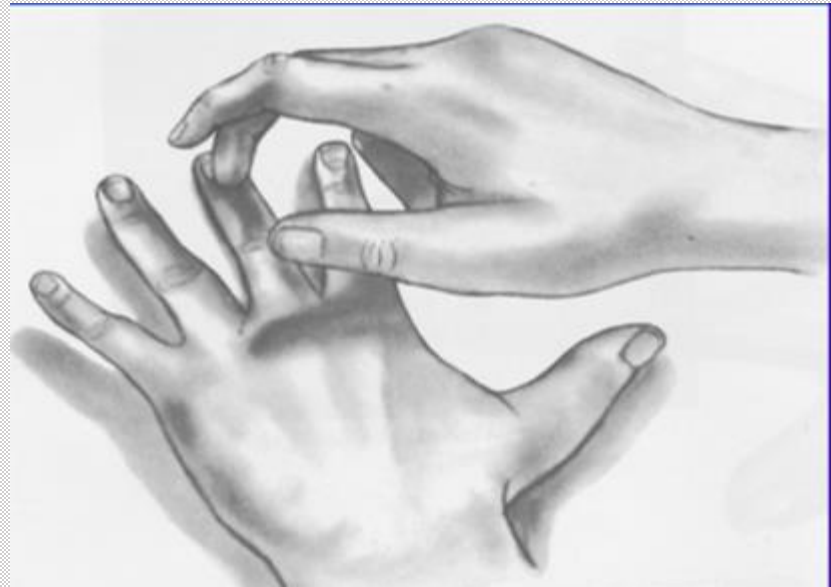

- Location of McBurney's point (1), located two thirds the distance from the [umbilicus](#) (2) to the right [anterior superior iliac spine](#) (3)

Abdominal percussion

-The percussion completes what the examiner found by inspection and palpation, establishing the size, consistency of the abdominal organs, the presence of fluid or air in the abdomen, the presence of tumors.

As a result of the percussion, **tympanic** zones can be obtained at the level of the stomach and intestinal loops and **dull** areas above the liver, spleen or in the case of presence of free fluid in the abdomen



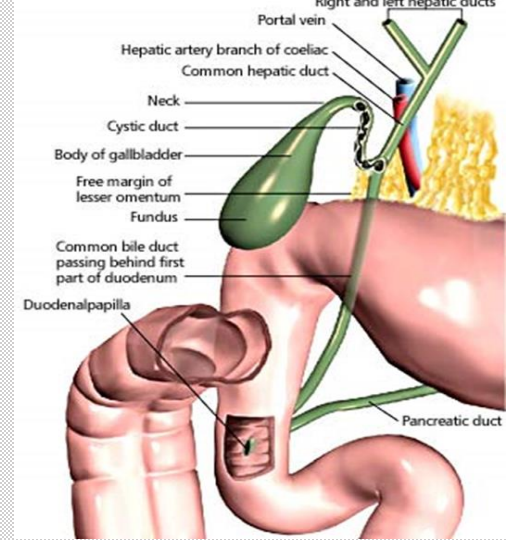
Abdominal percussion

Percussion can be done in two ways:

- Starting from the highest point of the abdomen to the lower areas (in the form of sunlight). Most often it starts from the epigastrium and obtains a dullness with the concavity upwards. To demonstrate the presence of free fluid, the patient may be invited to lie on the right or left lateral decubitus, the percussion is repeated in the same way and the presence of a dullness with the horizontal upper line is noted.
- Percussion of solid abdominal masses in the lower abdomen shows the presence of a dullness with downward concavity (bladder, pregnancy, ovarian cyst, ovarian tumor).

Liver and bile ducts

Complaints



- **Pain:** - discomfort (chronic hepatitis)
- painful embarrassment
(increase in bile duct pressure due to an obstacle, calculation)
- -bile colic - violent, in the right hypochondrium, with posterior irradiation

- **Fever** + - gallstones
 - - angiocolitis
 - - cholecystitis
 - septic - liver abscess
 - - infected hydatid cyst
 - subfebrile ~ common
(angiocolitis, viral hepatitis, after biliary colic)

- **Pruritus**
- **Weight loss**

Liver and bile ducts

Complaints

Disorders:

Dispeptic: - bloating

- regurgitations
- bitter taste
- accelerated transit (\pm melena-in haemorrhages)
- decrease or lack of appetite
- nausea
- vomit (\pm bile-containing; coffee grounds-bleeding)

Neurological: agitation, restlessness,
sleepiness

...and other complaints **!!! The liver has over 500 functions**

Liver and bile ducts

History

Debut:

Acute - gallstones, hemorrhage upper digestive tract

Progressive - gallstones liver cirrhosis, chronic hepatitis

Gender

- Men - steatosis, cirrhosis (alcohol)

- Women - cholecystitis, gallstones, bilio-digestive dyskinesia

Age

- newborn - physiological jaundice

- adult - chronic hepatitis, liver cirrhosis

-elderly - liver cirrhosis

Hereditary antecedent:

-iron- hemochromatosis

-copper- Wilson's disease

-hemolytic jaundice - Gilbert's disease, Crigler-Najar disease

Liver and bile ducts

History

Pathological personal history

- viral hepatitis B or C - hepatocellular carcinoma
 - cholecystitis
 - gastroduodenal ulcer
 - typhoid fever, dysentery
 - leptospirosis, syphilis
 - malaria (liver / spleen), lamblia, hydatid cyst (liver)
 - heart disease - stasis liver
- = intoxications: fungi, alcohol, drugs: Rifampicin, Tetracycline, Hydrazide

Living and working conditions:

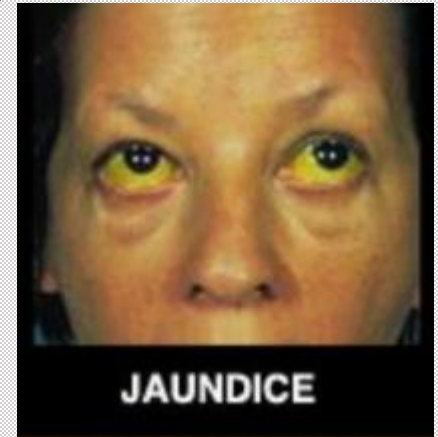- viral hepatitis - medical staff, dialysis wards, blood transfusions
- alcohol - chronic hepatitis, liver cirrhosis
- toxic (benzene, toluene, phosphorus, lead) - chronic hepatitis, cirrhosis of the liver

Liver and bile ducts

General inspection

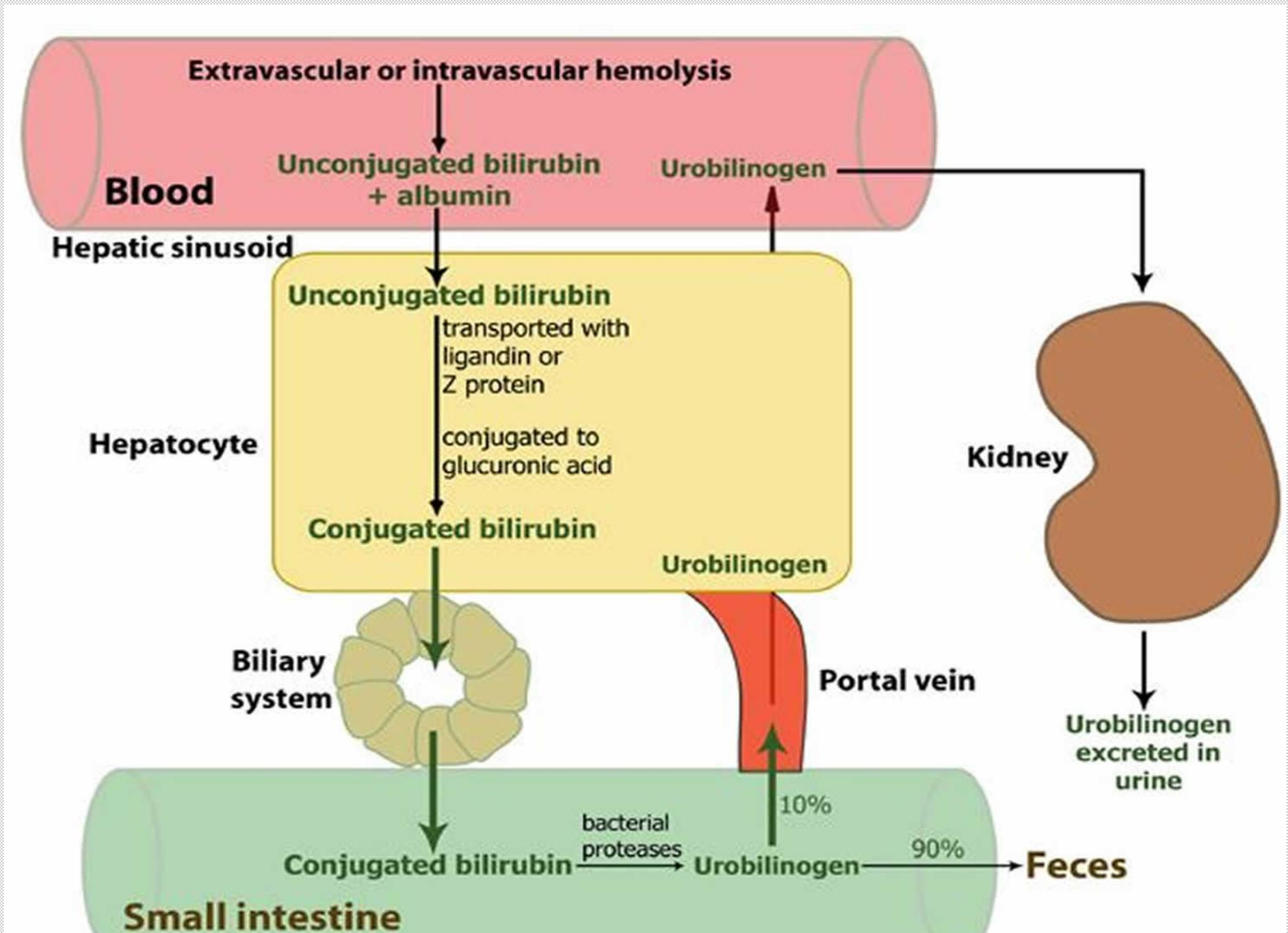
(Habitus) - cachexia

Skin and mucous membranes-jaundice, petechiae rashes, subcutaneous bleeding, vascular constipation, hyperemia of the palms and soles, gynecomastia in men



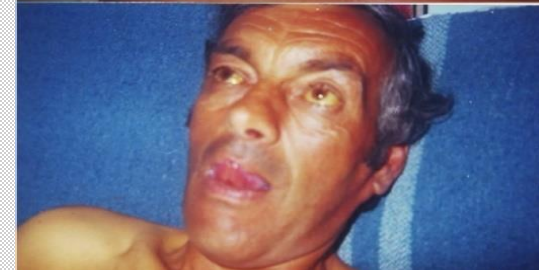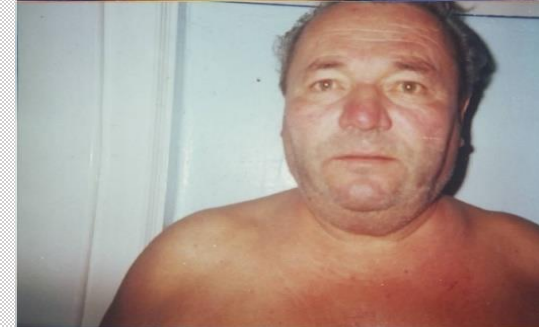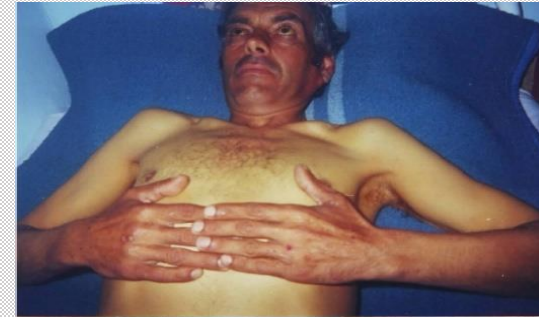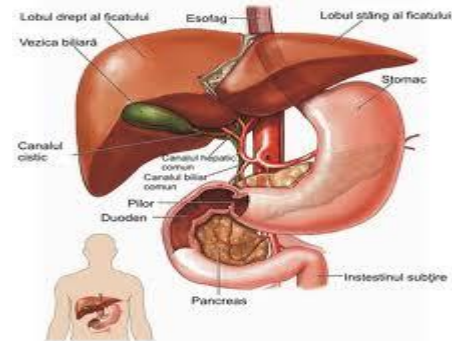
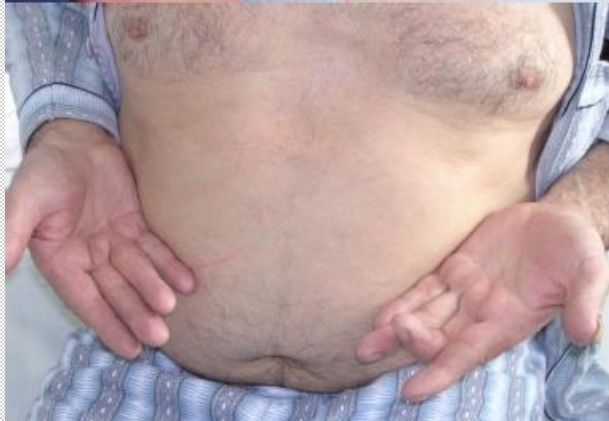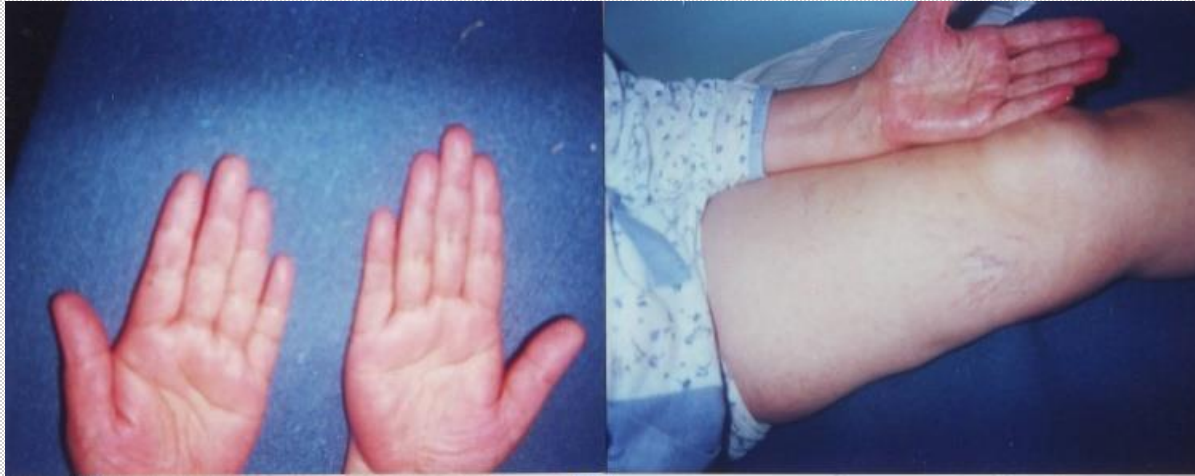Jaundice is the clinical expression of an increase in bilirubinemia following hereditary, developmental, or acquired abnormalities in the formation, transport, metabolism, and disposition of bilirubin.

bilirubin metabolism



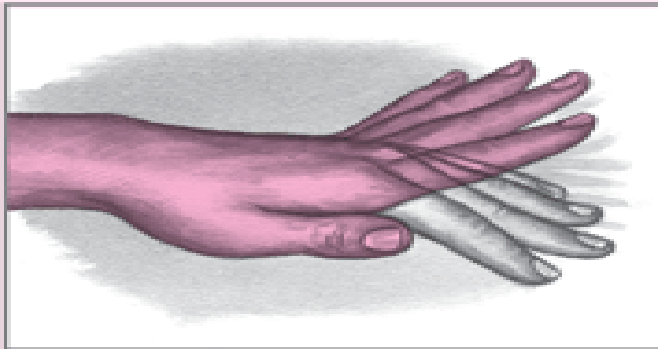
Liver and bile ducts

Inspection

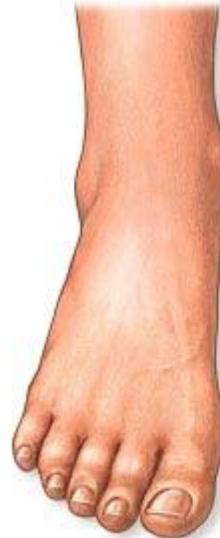

Recognizing asterixis

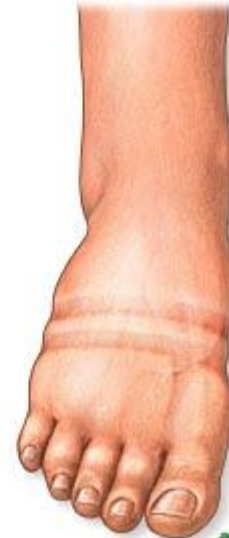With asterixis, the patient's wrists and fingers are observed to "flap" because there's a brief, rapid relaxation of dorsiflexion of the wrist.



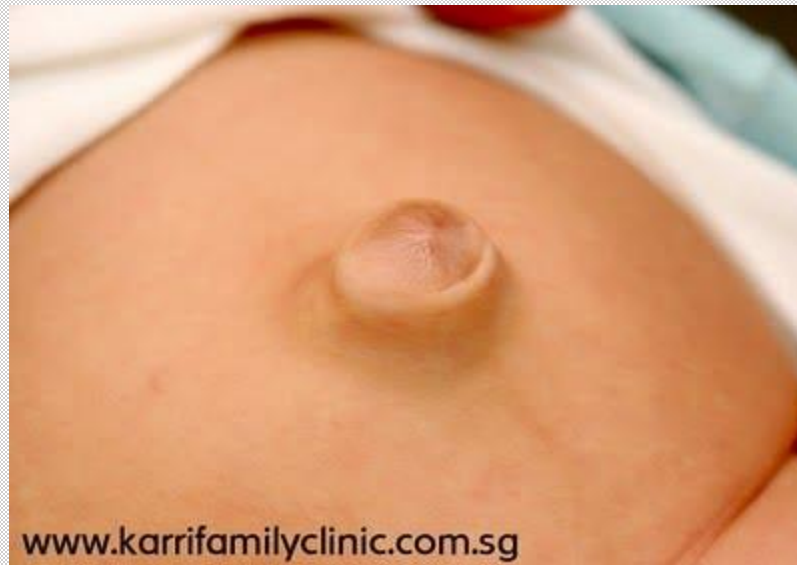Normal foot



Foot with edema

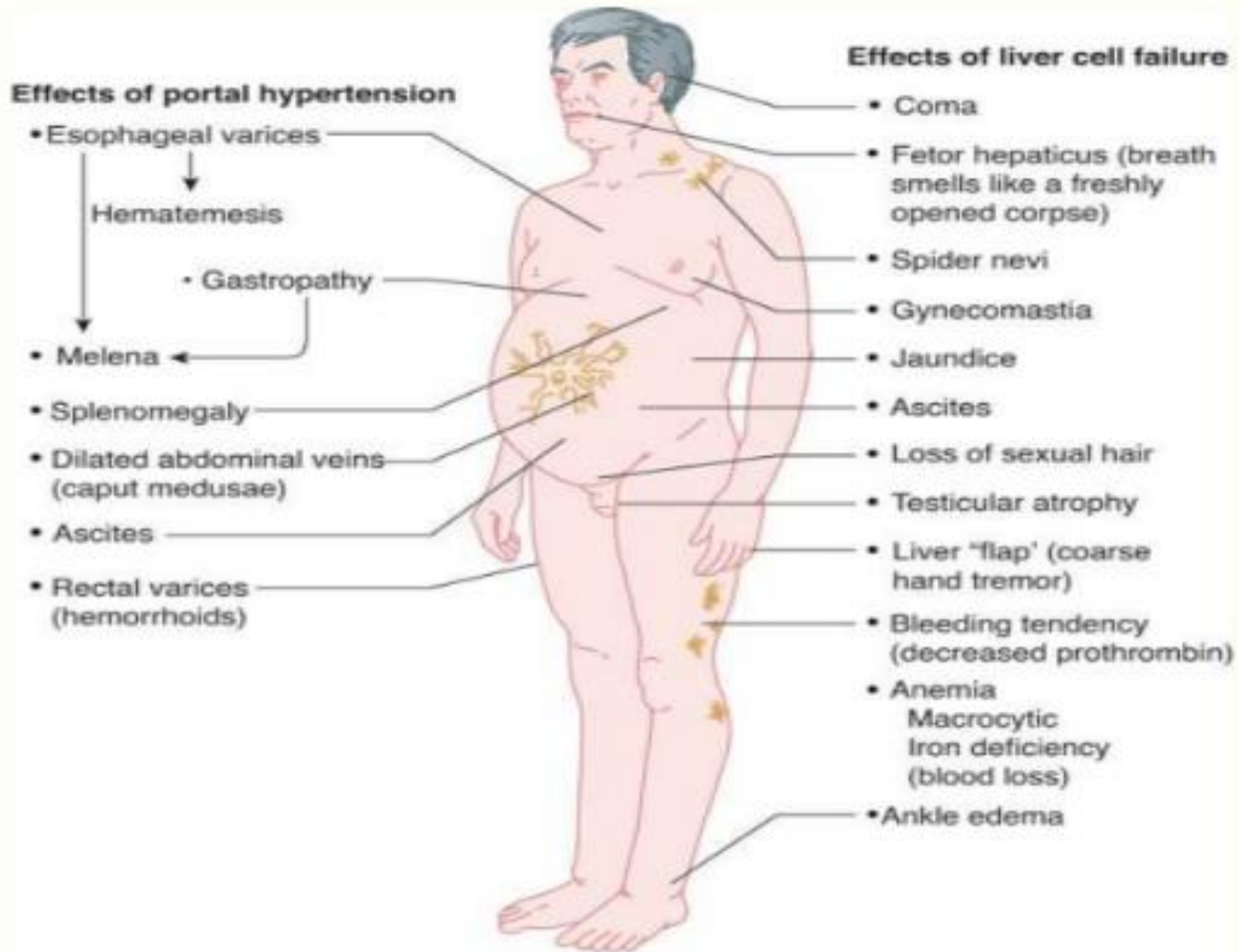


ADAM.



www.karrifamilyclinic.com.sg

Clinical Manifestations

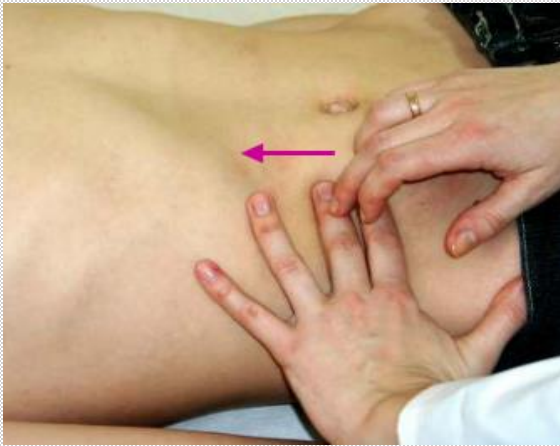

Source: McPhee SJ, Hammer GD: *Pathophysiology of Disease: An Introduction to Clinical Medicine*, 5th Edition: <http://www.accessmedicine.com>

Copyright © The McGraw-Hill Companies, Inc. All rights reserved.

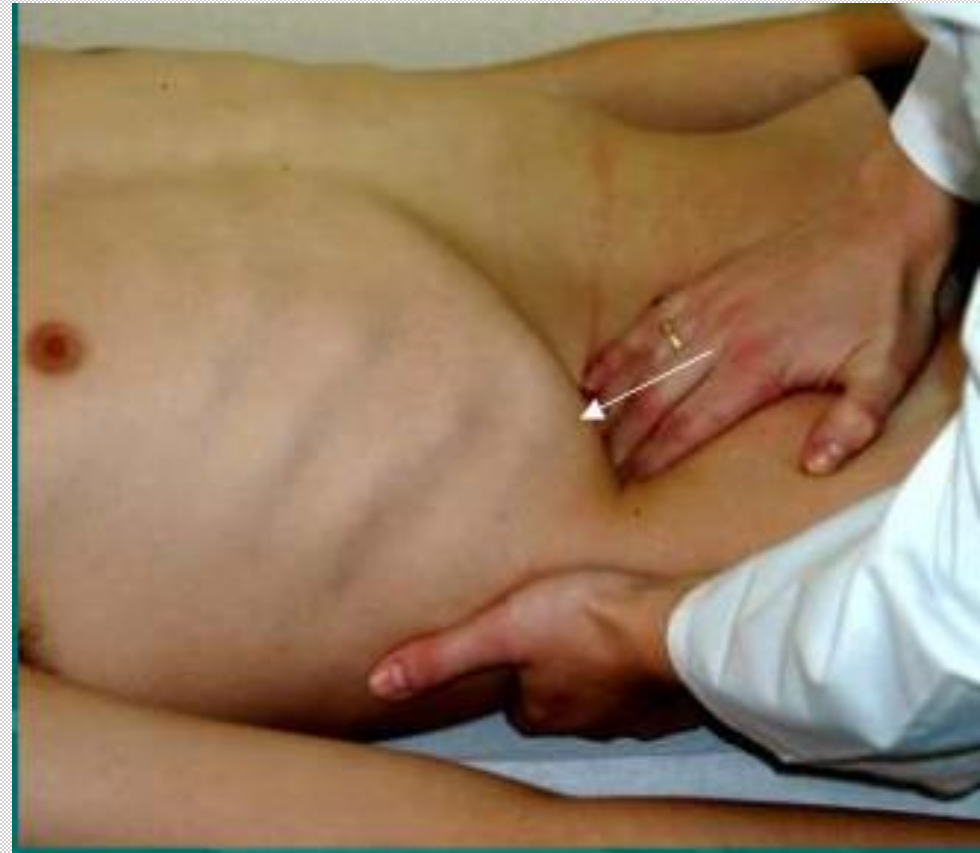Deep palpation of the liver

(!!! lower limit percussion precedes palpation)



In order to appreciate:

- the lower edge of the liver, the contour (smooth or irregular);
- edge consistency (hard or soft)
- the shape of the edge (sharp or rounded)
- pain
- organ surface (smooth or irregular).

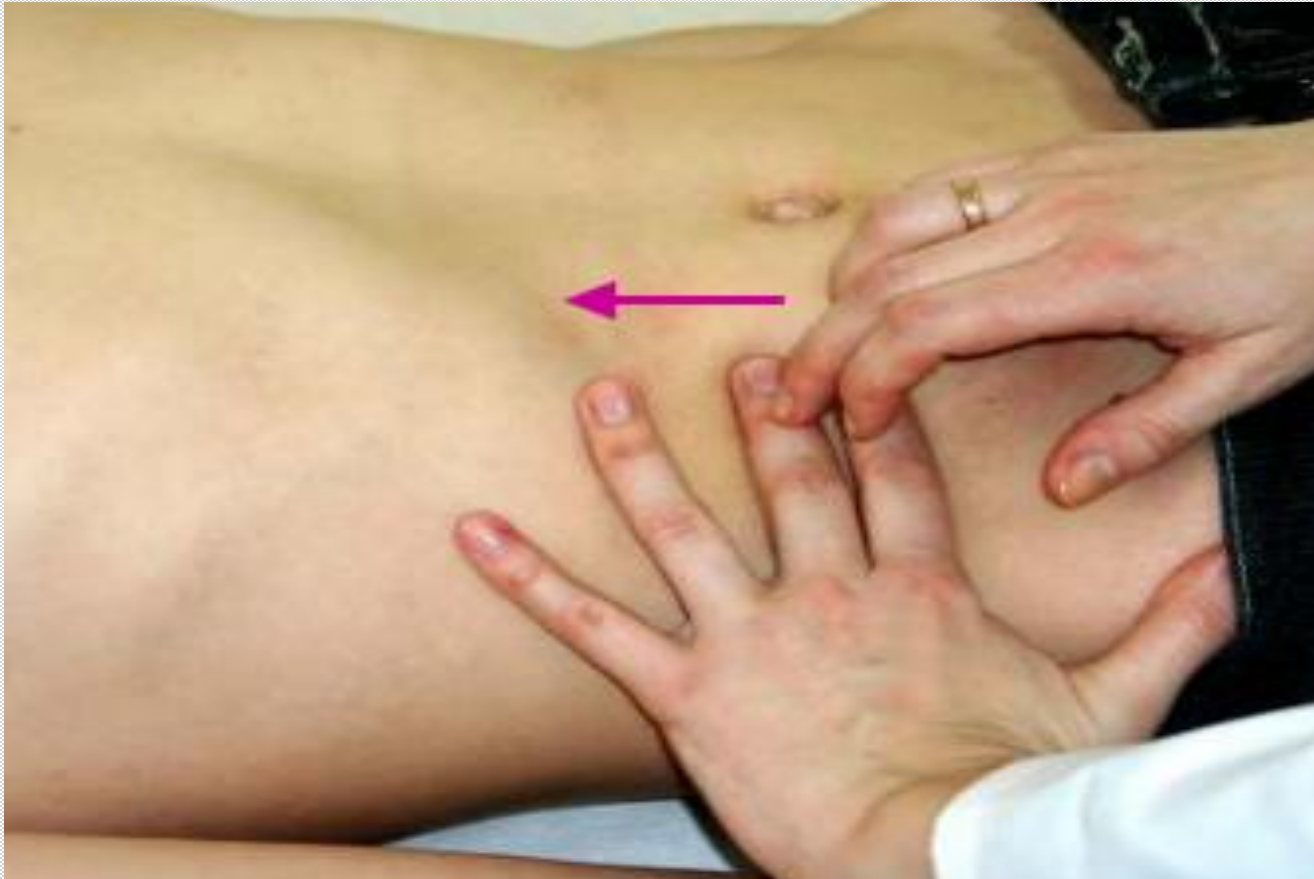

Palpation of the liver

!!! In case of massive accumulations of free fluid in the abdominal cavity:

-the tips of the fingers of the right hand exert jerky blows on the abdominal wall (without removing them from the surface of the abdomen), moving the hand from the bottom up. reaching the edge of the liver, the fingers feel a hard organ, which on hitting moves away from the fingers and approaches again (*symptom of floating ice*).

Percussion of the lower edge of the liver

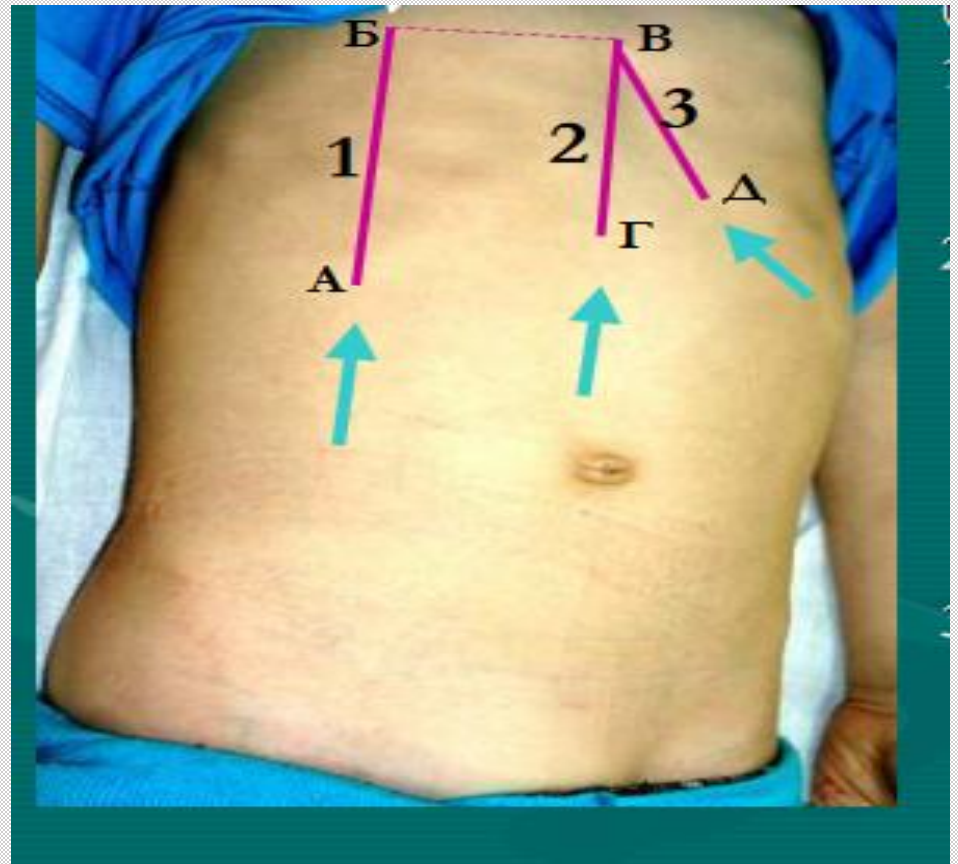
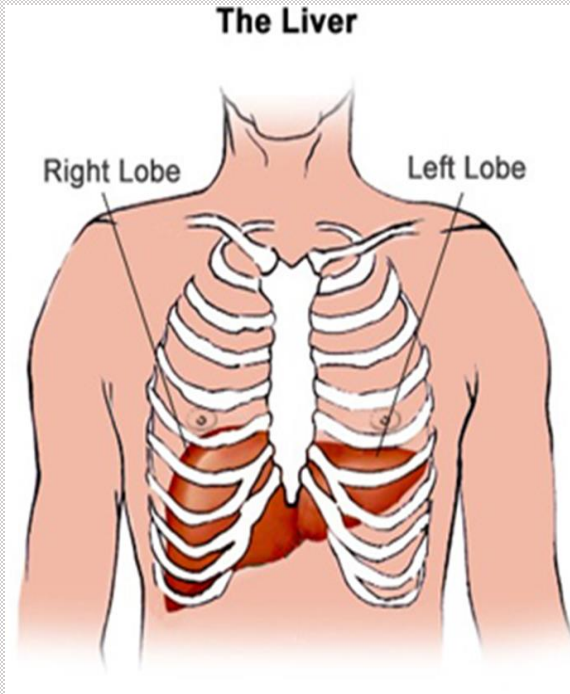


Liver percussion by Kurlov

I size - 9 ± 2 cm (right midclavicular line)

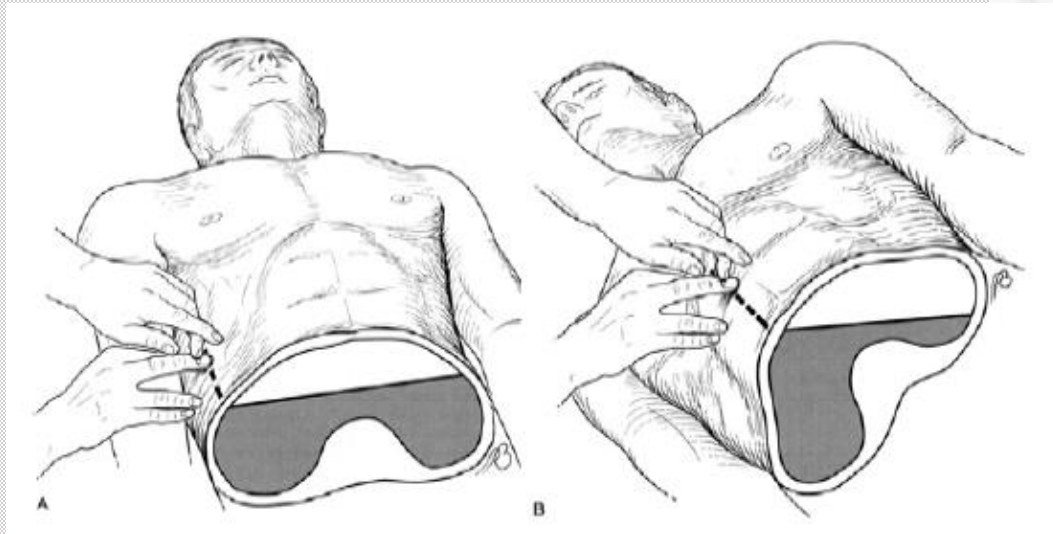
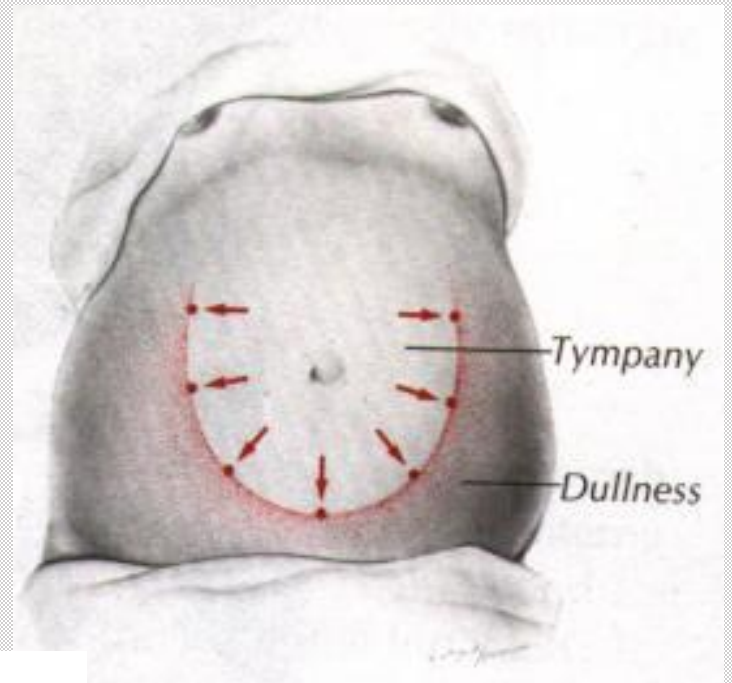
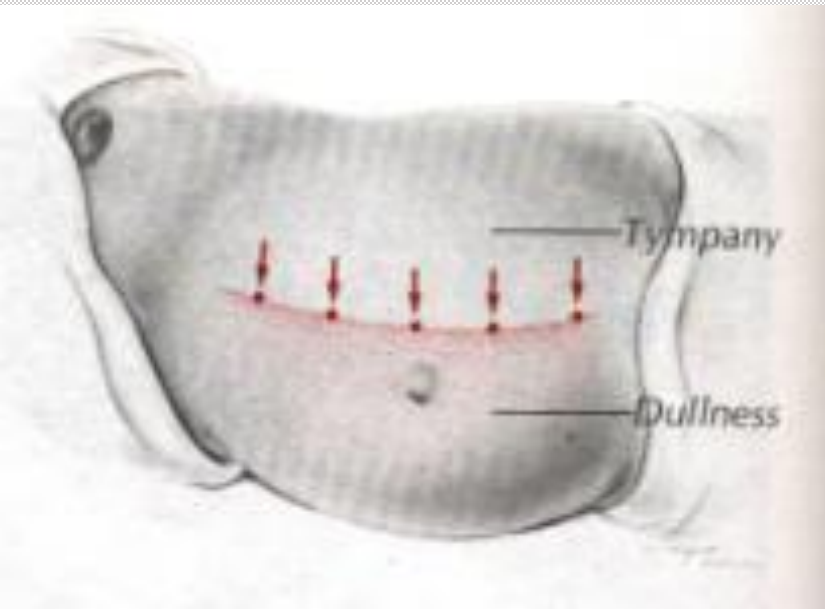
II size 8 ± 2 cm (midsternal line)

III size 7 ± 2 cm (left costal rim)



Liver

Percussion of the abdomen with ascites (displaceable dullness in the flanks)



Gallbladder (GB)

Local inspection

- bulging in the right hypochondrium (Courvoisier-Terrier s. from the neoplastic blockage of the choledochus)
- vesicular hydrops (cystic duct blockage)

Palpation

Normally GB is not detected by palpation !!!

only pathological GB is palpable !!!

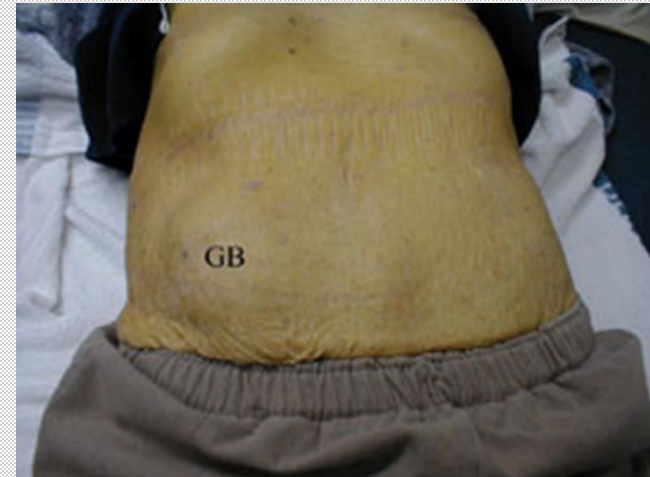High GB (biliary stasis)

GB distended (Courvoisier-Terrier s.)

GB large, mobile, like a "bell tongue" - vesicular hydrops

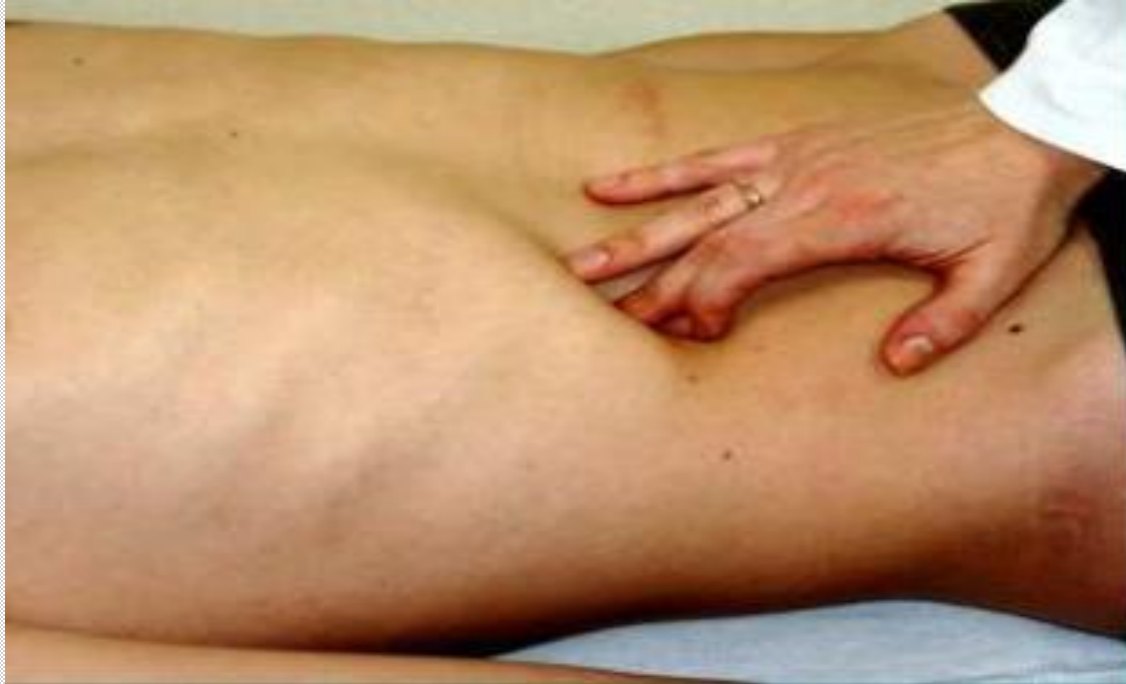Large GB, irregular wall, hard, painless - GB neoplasm

GB small, hard, woody - GB calculous, sclero-atrophic



Palpation of the gallbladder

(at the intersection of the outer edge of the right abdominal muscle with the costal rim)



Gallbladder

painful points specific to biliary GB damage:

Murphy - accentuation of pain in the right hypochondrium at the pressure of the right abdominal wall in projection of the gallbladder during deep inspiration (usually the patient interrupts the expiration due to pain)

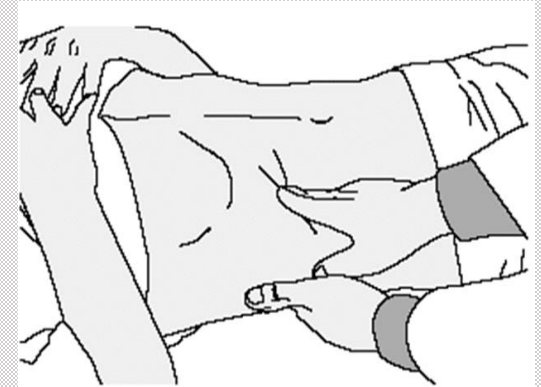


Figure 1. Elicitation of the Murphy's sign of cholecystitis.

Kerhr - the appearance or intensification of pain in inspiration on palpation in the point of the gallbladder

Lepehne - pain on the percussion of soft tissues in the region of the right hypochondrium

Ortner - percussion pain on the right costal rim

Aizenberg II - pain occurs in the region of the right hypochondrium if the patient suddenly gets up on the fingers and leaves on the sole

Volskii - pain, which appears at a slight paleness with the edge of the hand from top to bottom on the right costal rim

Krâmov - pressure pain in the upper right area of the umbilical region

Gallbladder

Reflective pain points in diseases of the biliary tract

Right reactive vegetative syndrome (irritant) - pain occurs on palpation of vascular and nervous points:

- orbital point (Bergman symptom),
- occipital point (Ionash symptom),
- cervical point (Mussy's symptom),
- interscapular point (Haritonov symptom),
- femoral point (Lapinskii symptom),
- plantar point (back of right foot)

Gallbladder and bile ducts

Paraclinical diagnosis

Abdominal ultrasound - is a method with good accuracy that can visualize stones with dimensions up to 2 mm; false positive or false negative results in 2-3% of cases

Abdominal radiograph - can diagnose calcium-containing stones

Duodenoscopy

Abdominal CT

Abdominal MRI

Endoscopic retrograde cholangiopancreatography

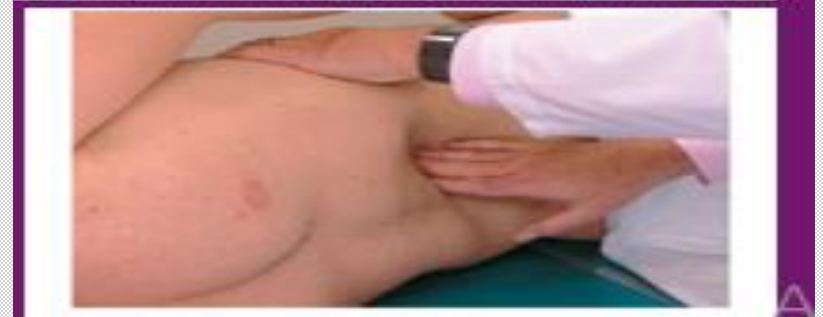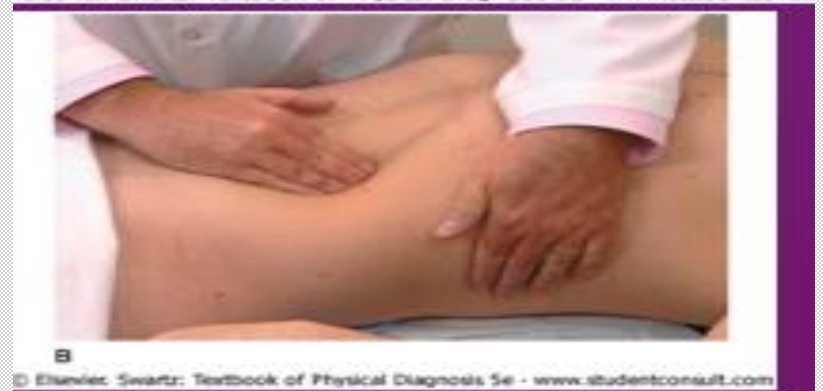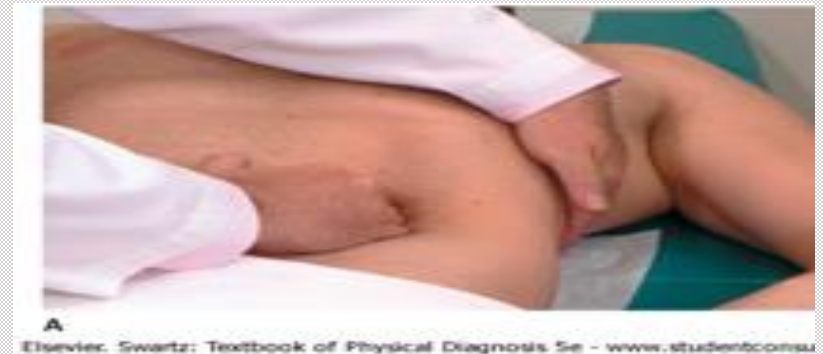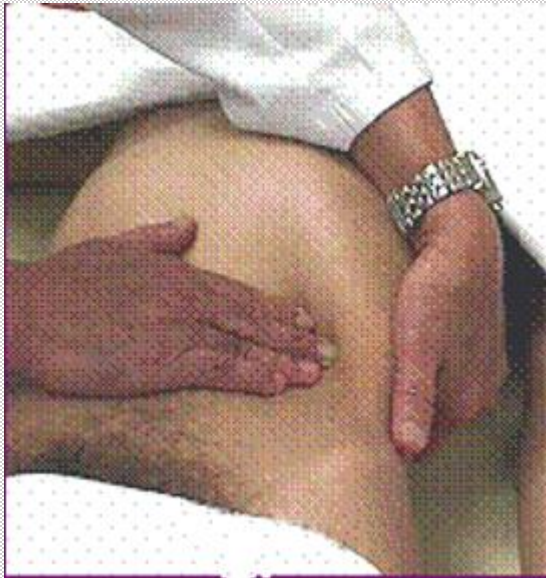Magnetic Resonance Cholangioancreatography (MRCP)

Endoscopic ultrasonography

...

Palpation of the spleen

(!!! Normally the spleen is not detected)



Spleen percussion

Use low intensity percussion

- Longitudinal diameter (6-8 cm): at the level of the left X rib
- Transverse diameter (4-6 cm) - longitudinal diameter is divided in half and struck perpendicularly on the X rib

Percussion can be performed from clear sound to dullness and vice versa

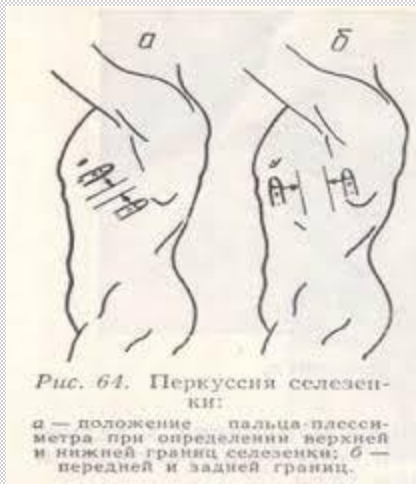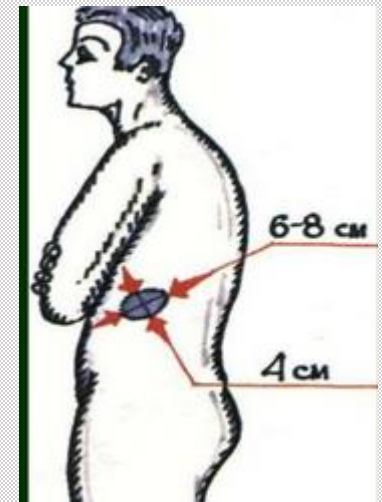
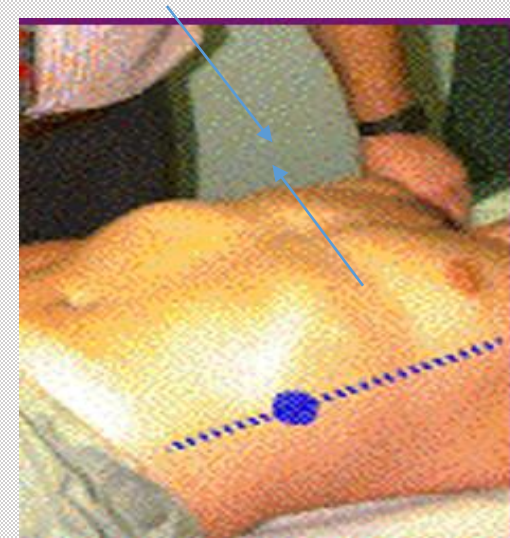
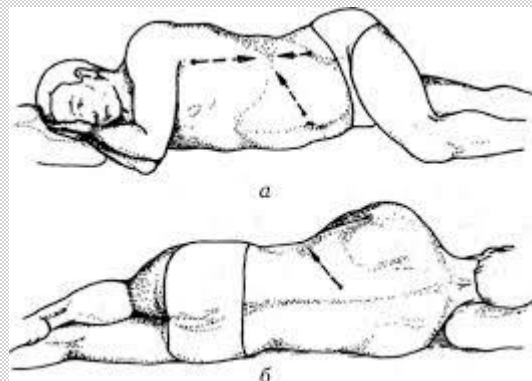


Рис. 64. Перкуссия селезенки:
а — положение пальца-пальцемера при определении верхней и нижней границ селезенки; б — передней и задней границ.



Thank you for your
attention

