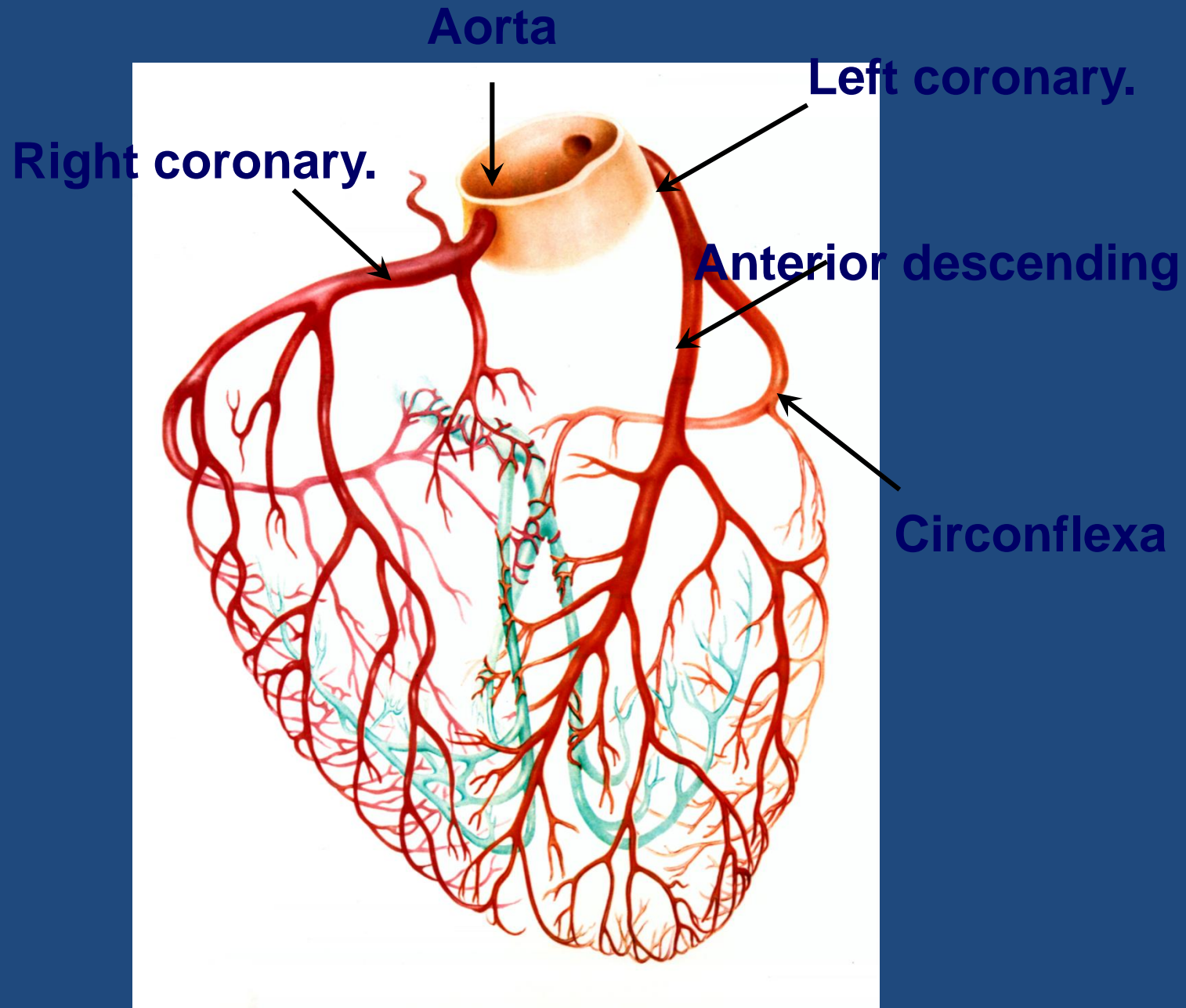


**ELECTROCARDIOGRAPHICAL CHANGES IN
ACUTE MYOCARDIAL INFARCTION AND
angina PECTORIS**

Ischemic heart disease

- is a disease whose fundamental mechanism is **unsatisfactory irrigation** of the myocardium, a consequence in most cases of **coronary artery obstruction** (> 90%) by coronary atherosclerosis.



CLASIFICATIOn

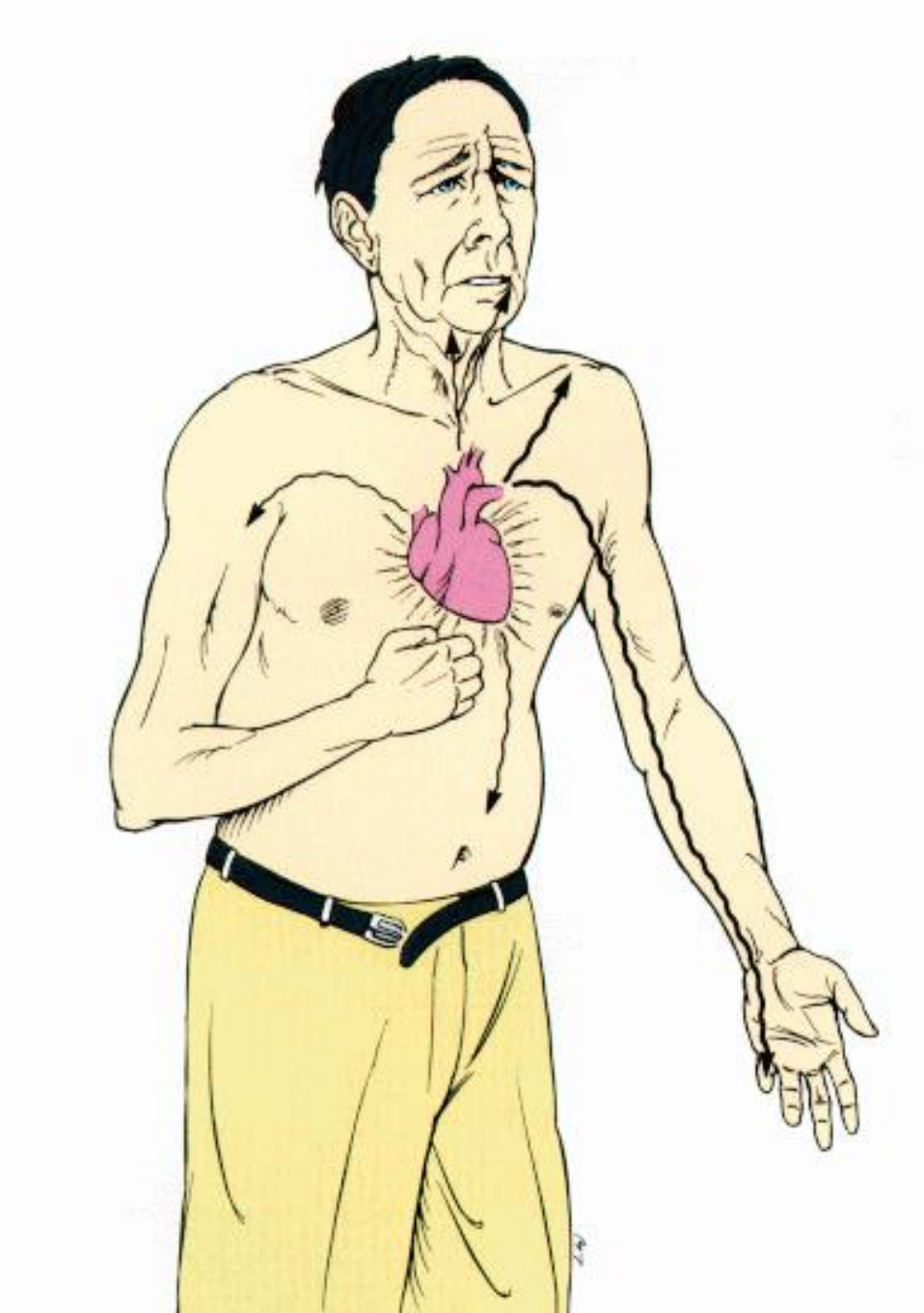
Classification of ischemic heart disease according to the International Society of Cardiology

- ▣ A. Primary cardiac arrest
- ▣ B. Angina pectoris
 - effort
 - again
 - aggravated
 - stable
 - spontaneous (vasospastic, Prinzmetal)
- ▣ C. Myocardial infarction
 - Acute MI
 - Old MI
- ▣ D. Ischemic heart failure
- ▣ E. Ischemic cardiac arrhythmias

DEFINITION

Acute myocardial infarction (AMI) - ischemic necrosis of the myocardium, caused by complete and prolonged obstruction of a coronary artery

Acute coronary syndrome - acute myocardial ischemia due to complete or partial occlusion of a coronary artery



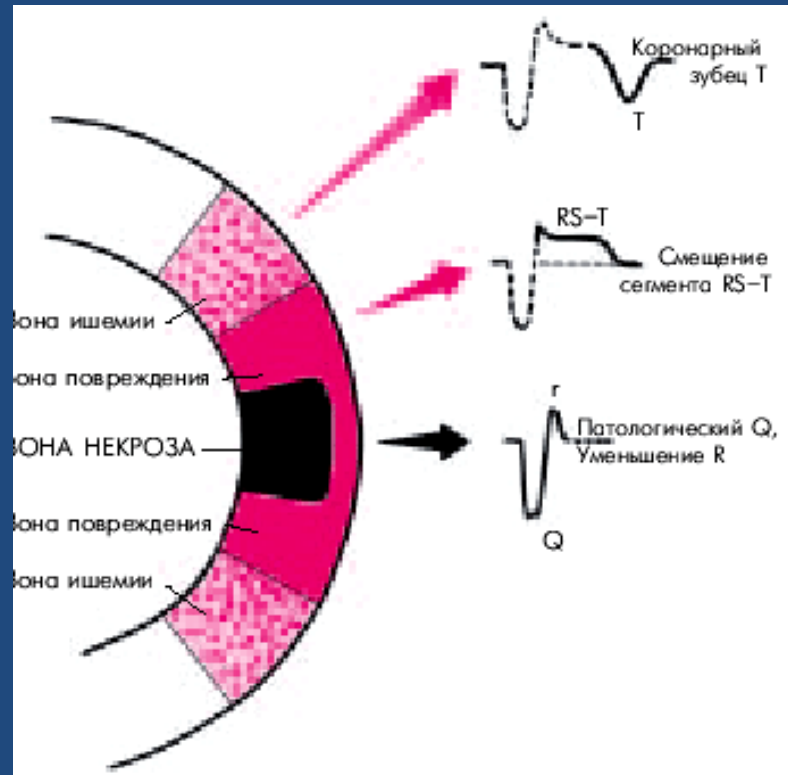
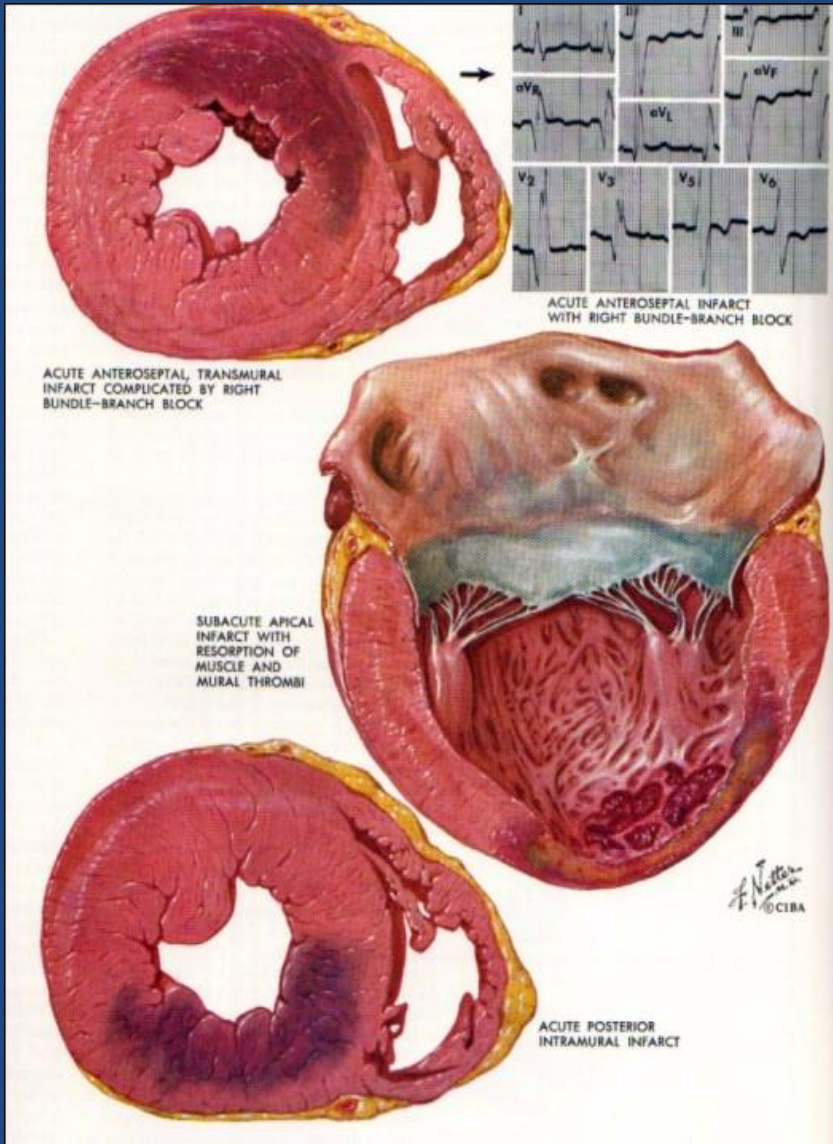
ACS without ST segment elevation:

- ▣ **Unstable angina**
(negative myocardial necrosis markers)
- ▣ **Myocardial infarction without ST elevation**
(positive myocardial necrosis markers)

ACS with ST segment elevation:

- ▣ **Acute myocardial infarction with ST elevation**
(positive myocardial necrosis markers)

MORFOPATOLOGY



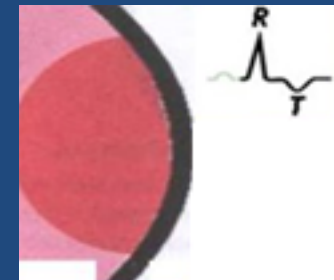
AMI areas:

- necrosis area
- lesion area
- ischemia area

ECG - THE AREA OF ISCHEMIA

The changes are only from the T wave:

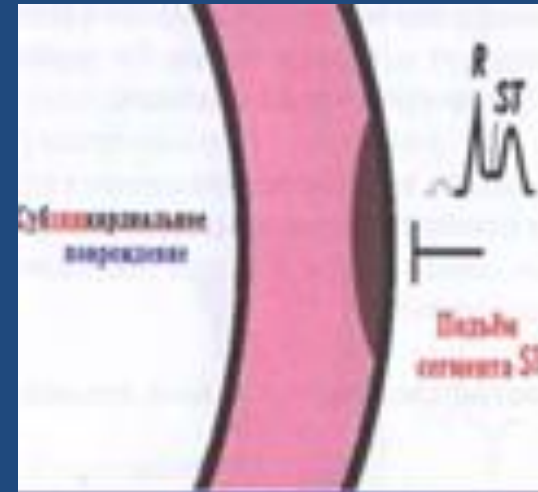- In subendocardial ischemia - T is large, sharp
- In subepicardial ischemia - T is negative
- In transmural ischemia - T is large, negative



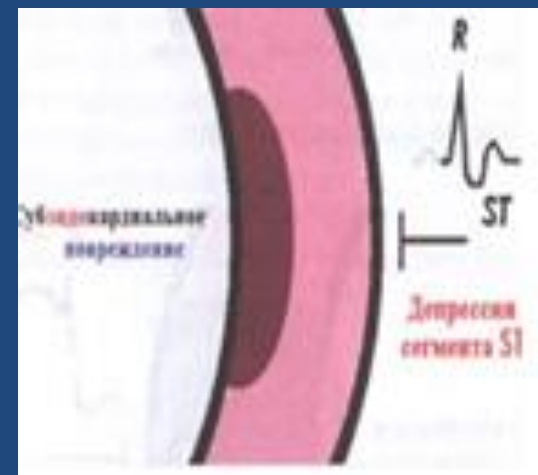ECG – LESION AREA

The changes are from the ST segment:

- ST elevation
(subepicardial injury)

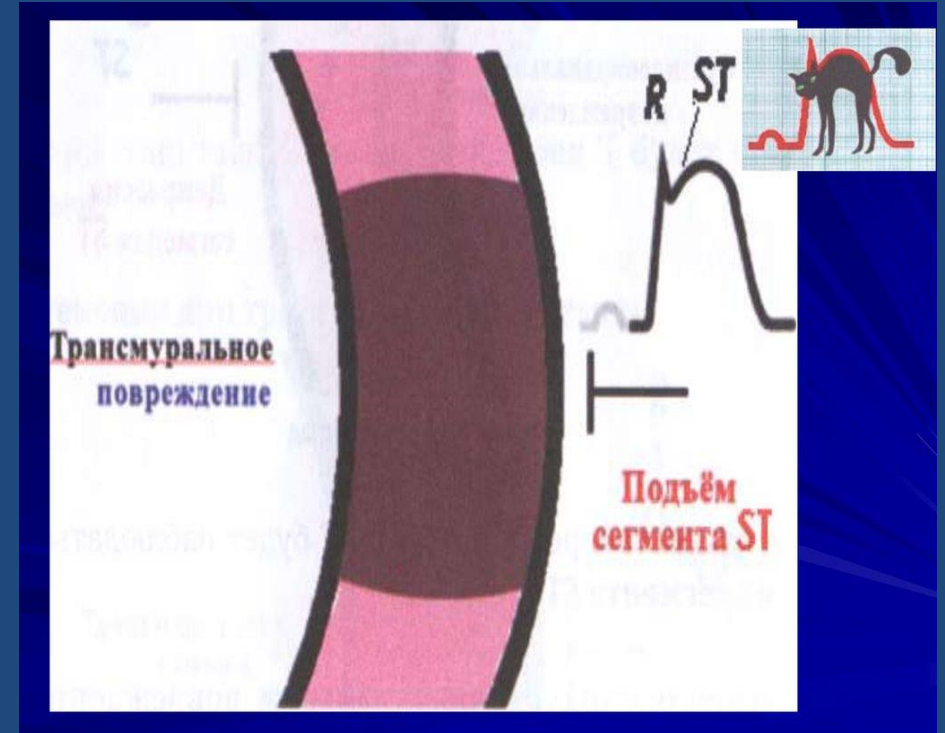


- ST depression
- (subendocardial injury)



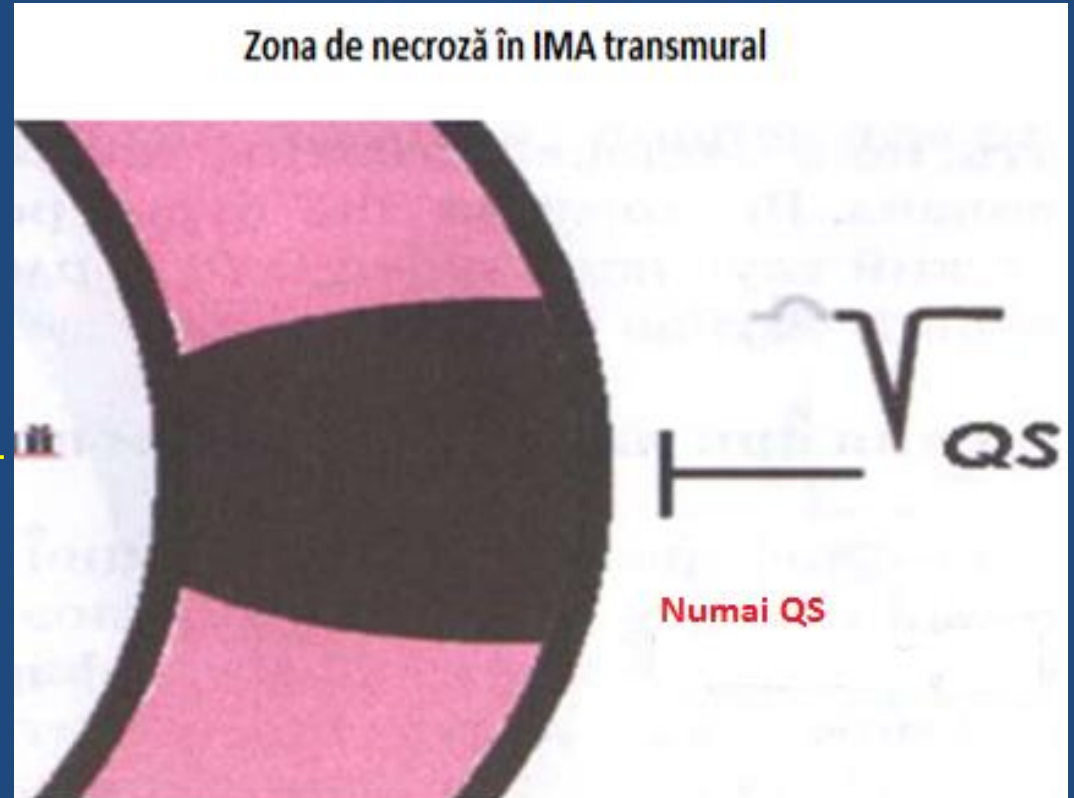
ECG – LESION AREA

- In transmural injury the elevation of the ST segment is so high that it encompasses the T-wave - "cat's back" - the Pardee wave
- This complex is recorded in the early stages of AMI - the superacute stage (early acute), when the area of necrosis has not yet formed, but is a transmural lesion.

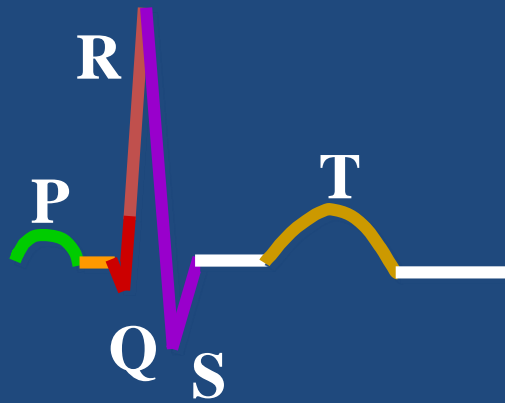


ECG – NECROSIS AREA

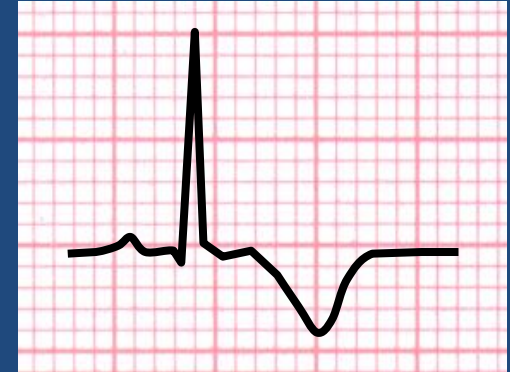
- In the area of necrosis, the muscle fibers are destroyed, so they are not excited - the myocardium completely loses all its functions. The electrode located in the necrosis area will not record the R wave on the ECG.
- Necrosis may involve:
 - only part of the myocardial wall - nontransmural AMI
 - the whole myocardial wall - transmural AMI
 - It can be located inside the myocardial wall - intramural AMI.



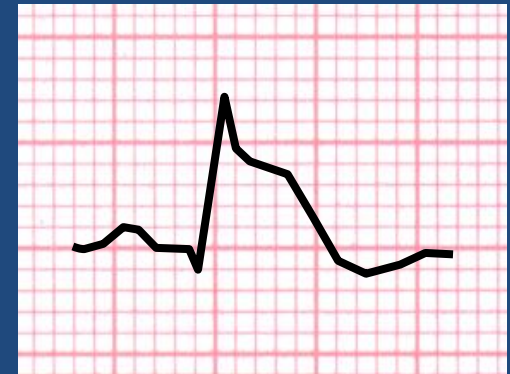
NORMAL ECG



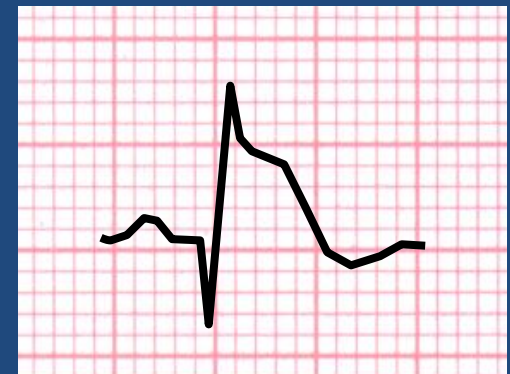
ISCHEMIA



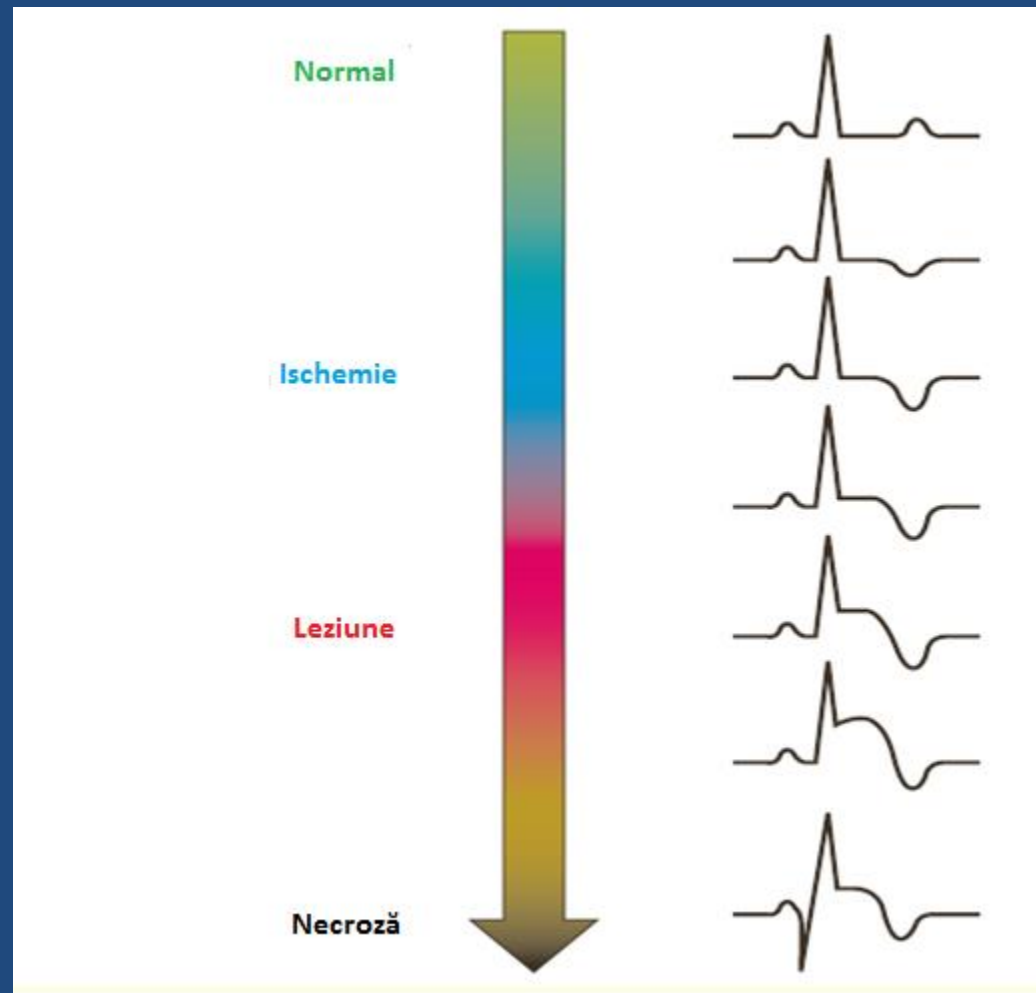
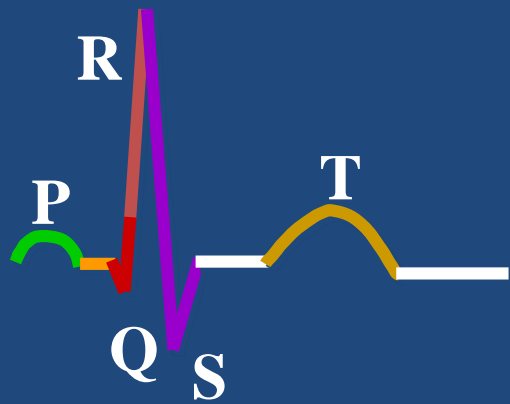
LESION



NECROSIS
(+ lesion)

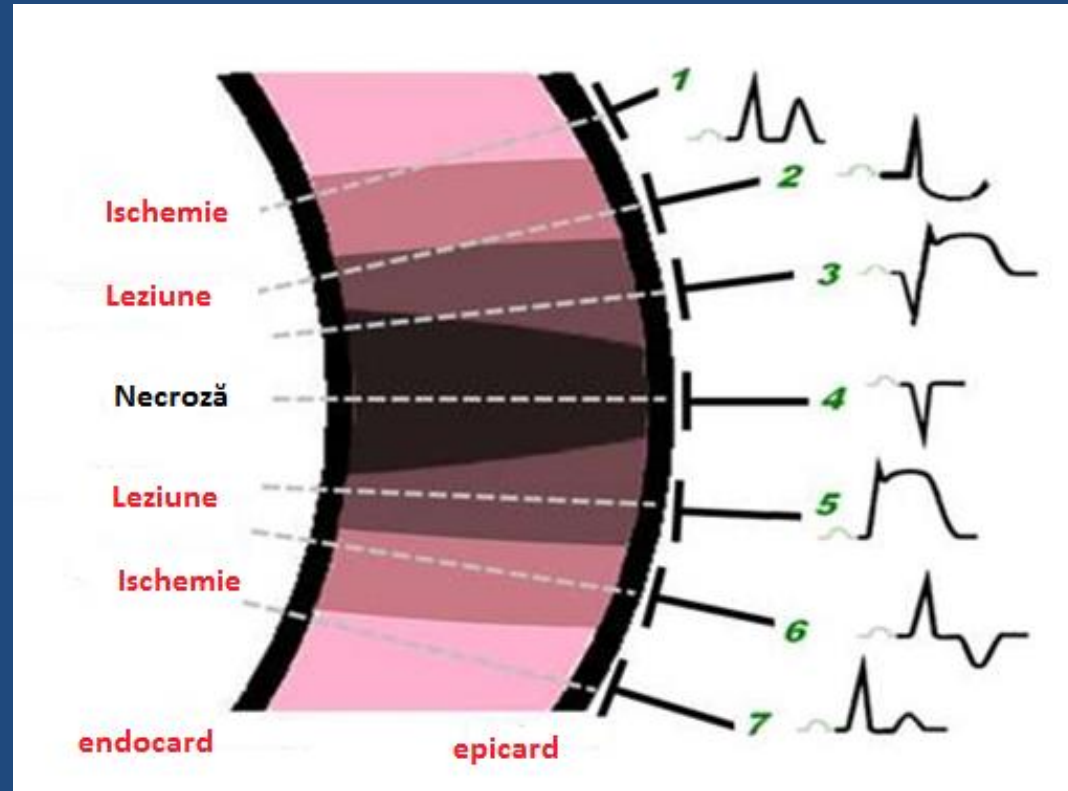


▣ NORMAL ECG



ECG - various associations of ischemia, injury and necrosis

1. In the concomitant presence of several areas (ischemia, lesion, necrosis) the ECG signs add up
2. Example: subendocardial lesion + subepicardial ischemia (ST depression + negative T wave)

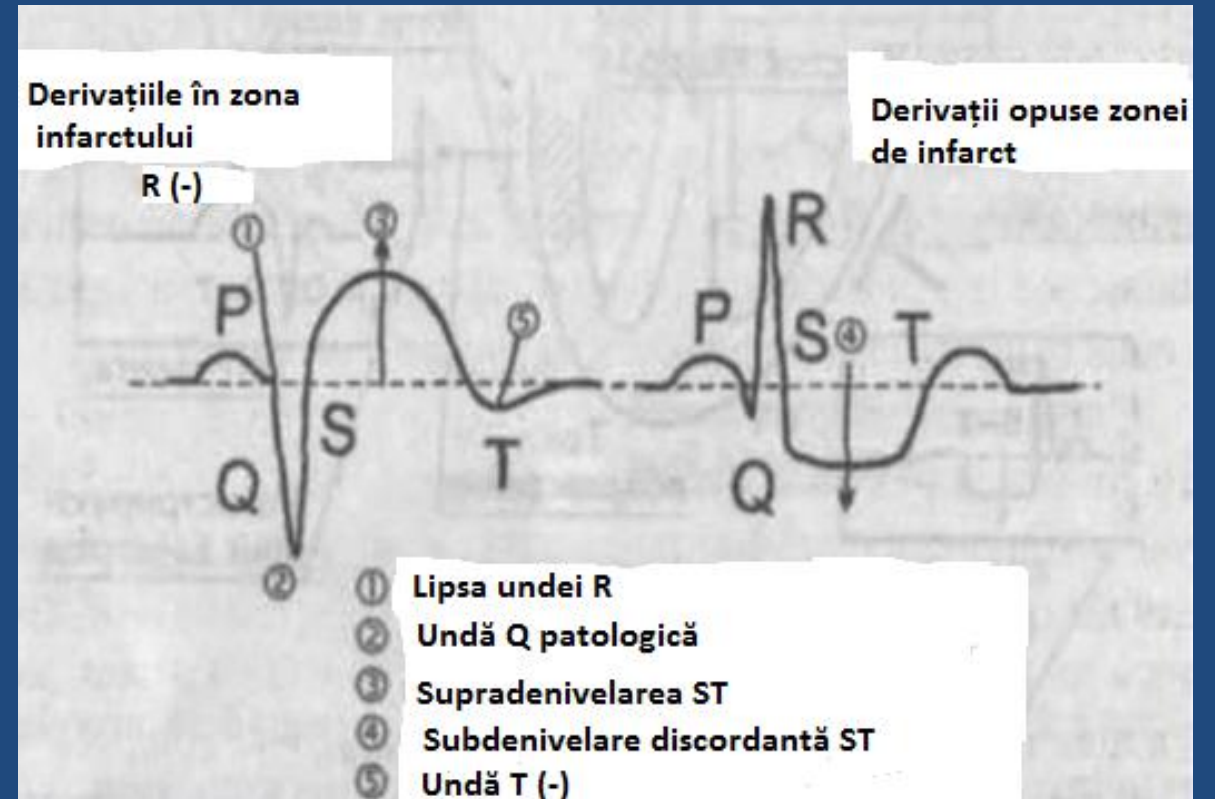


PARACLINICAL EXAMINATIONS

□ The ECG shows direct and indirect (reciprocal) signs of AMI:

- Direct signs (ST-segment elevation, T-wave (-) and Q-wave of necrosis) occur in leads that explore the ventricular wall with necrosis

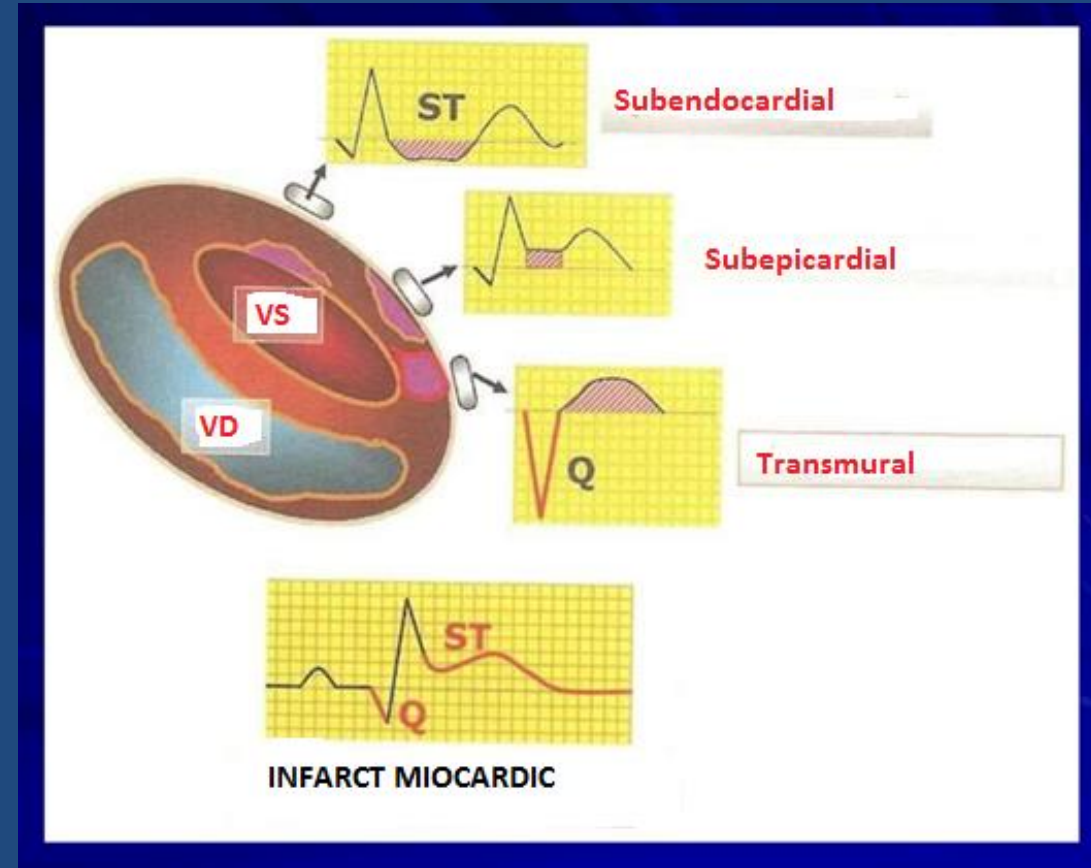
- Indirect, reciprocal signs ("in the mirror"): ST-segment depression, T-wave (+) - appear in leads that explore the wall opposite to the one with necrosis



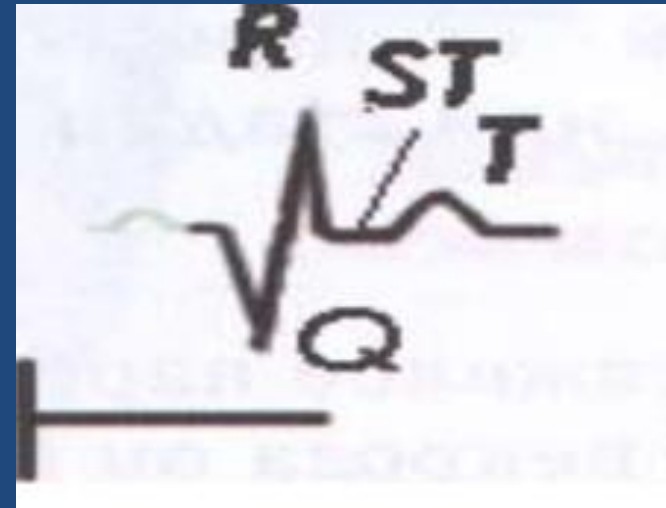
AMI CLASIFICACION

- Q-wave myocardial infarction: occurs in case of transmural necrosis, which is associated with elevated seg. ST. That's why it's called STEMI (ST-segment elevation myocardial infarction)
- Q wave of necrosis occurs: it has a duration > 0.04 sec and an amplitude > 2 mm
- the R wave decreases in amplitude and may disappear; instead of the QRS complex, the QS complex appears
- Non Q-wave myocardial infarction (non-Q) occurs in the event of subendocardial necrosis, which is associated with the ST-segment depression. That is why it is called non-STEMI (myocardial infarction without ST-segment elevation)

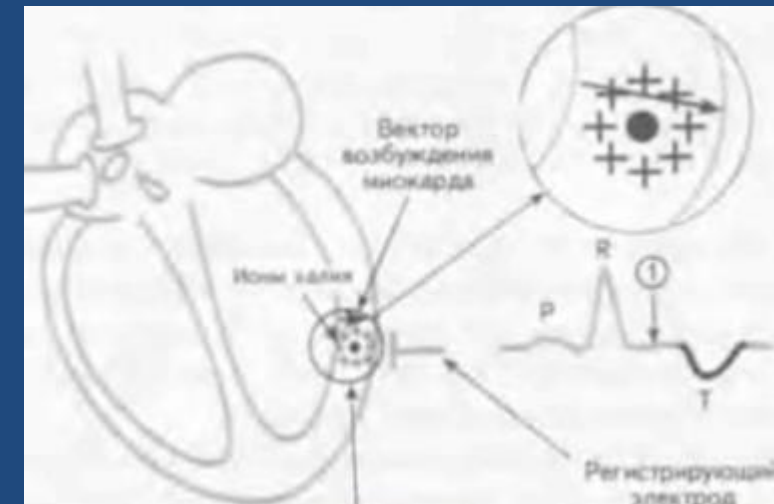
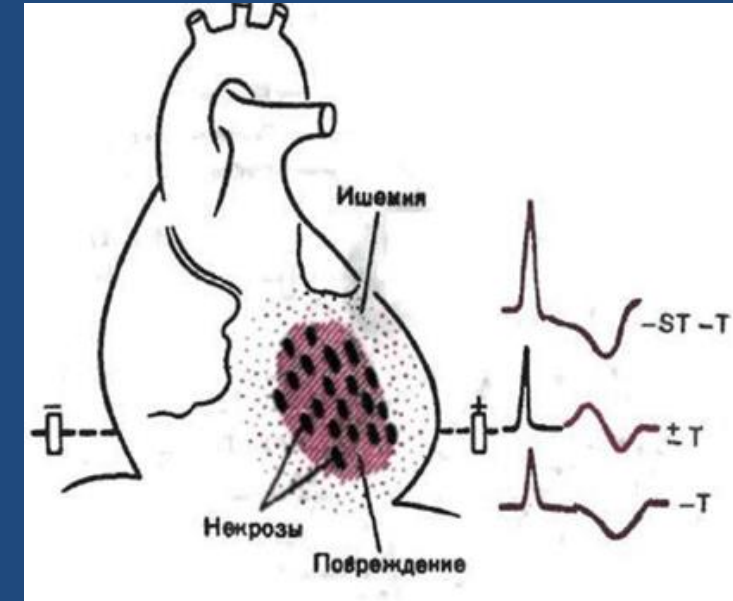
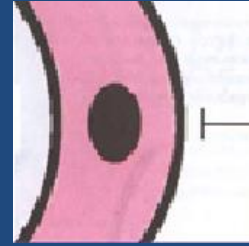
In the leads that explore the wall with infarction: the depression of ST segment (subendocardial lesion), associated with T-wave changes (myocardial ischemia)



- In nontransmural IM under the electrode a part of living cells is kept and depolarization will occur, but to a lesser extent - on the ECG will be recorded pathological Q wave and low amplitude R wave



□ In intramural MI, depolarization will bypass the necrotic area on both sides - on the ECG, the pathological Q wave may not be recorded - non-Q myocardial infarction (intramural MI with a small focus). Only the negative T wave is recorded, which is kept negative for 12-14 days, then gradually rises to isoelectric line or becomes positive.



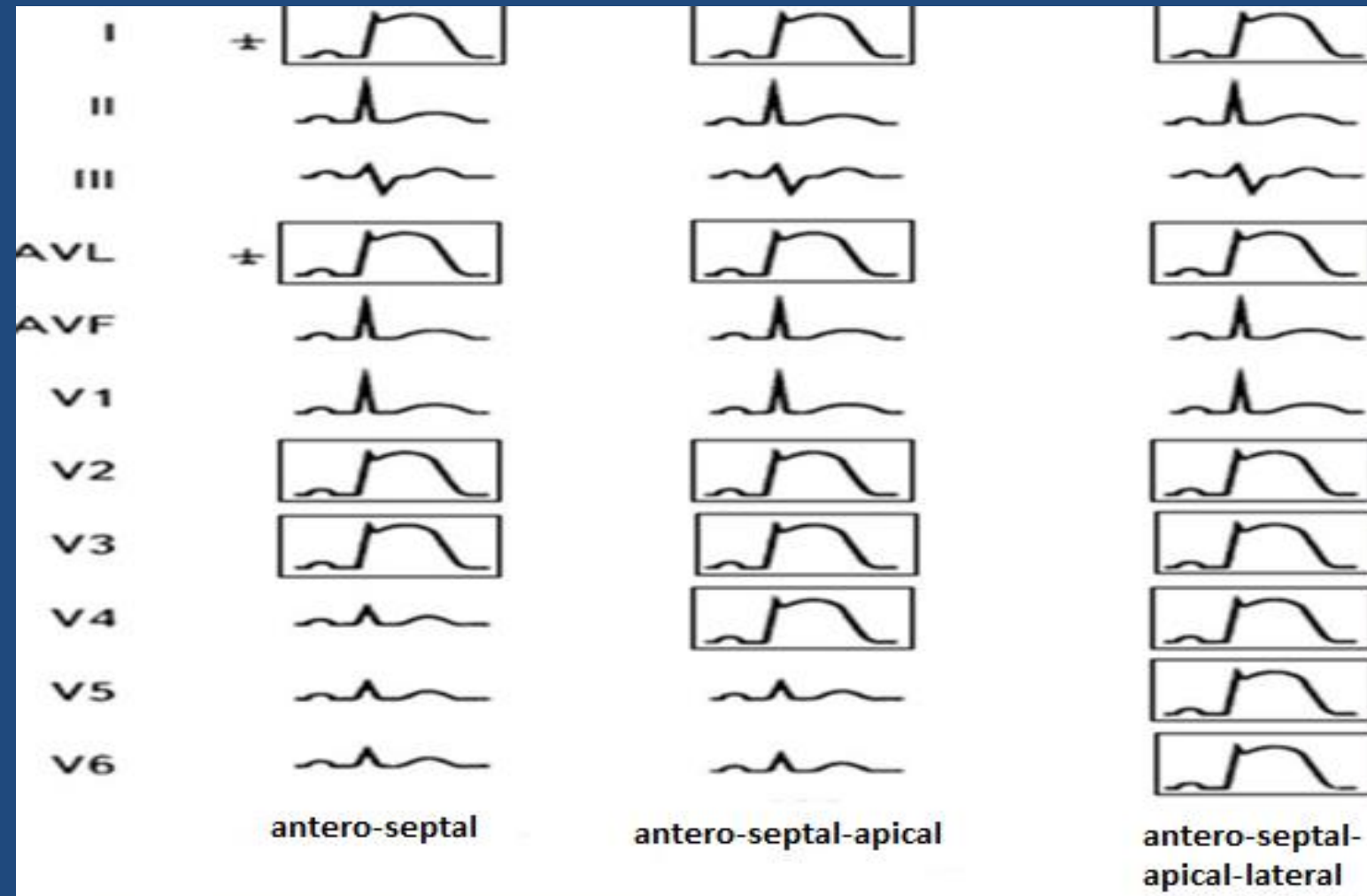
Location of the IMA: it is done according to the derivations that show the direct signs of AMI

Direct signs	↑ ST	Indirect signs ↓ ST	Location
DIII, aVF, (DII)		DI, aVL (V1-V4)	Inferior
DIII, aVF, (DII)	V5-V6		Infero-lateral
DIII, aVF, (DII)	V2-V6		Circular apical
	V7-V9	V1-V2	Postero-basal (posterior)
DI, aVL (DII)	V1-V4	DIII, aVF	Antero-septal
DI, aVL (DII)	V1-V6	DIII, aVF	Anterior-extended
DI, aVL (DII)	V5-V6		Lateral
	V3R-V4R		Right

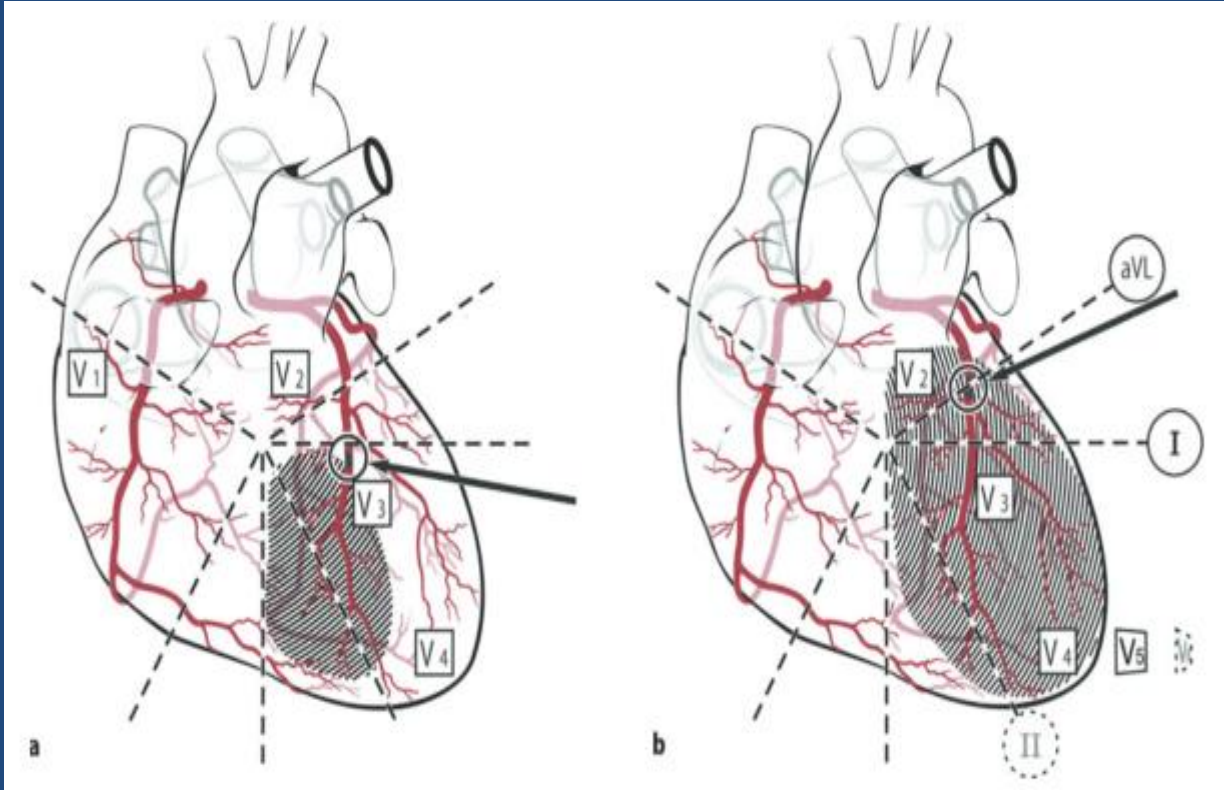
Localization of ischemic area in ST elevation Myocardial Infarction

Leads with ST segment elevations	Affected myocardial area	Occluded coronary artery (cuprit)
V1–V2	Septal	Proximal LAD.
V3–V4	Anterior	LAD.
V5–V6	Apical	Distal LAD, LCx or RCA.
I, aVL	Lateral	LCx.
II, aVF, III	Inferior	90% RCA. 10% LCx.
V7, V8, V9 (reciprocal ST depressions are frequently evident in V1–V3)	Posterolateral (also referred to as inferobasal or posterior)	RCA or LCx.

AMI LOCALISATION:

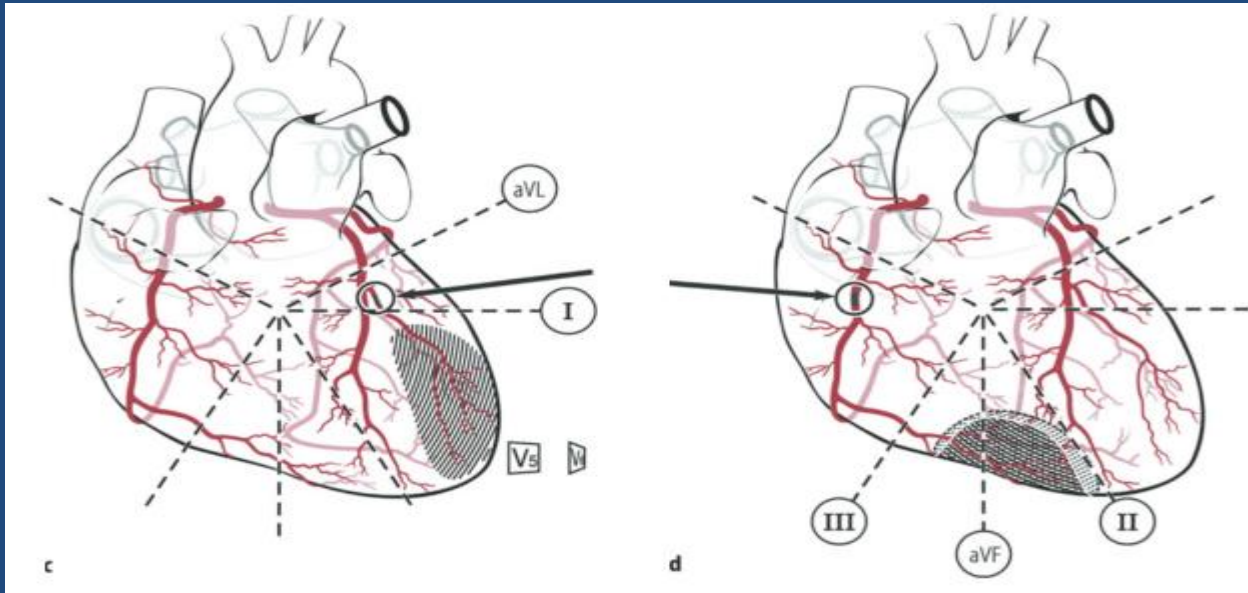


Anterior Infarction



- a. Anteroseptal infarction will produce the typical pattern in the leads: V1-V4
- b. Anterolateral infarction (extensive anterior infarction) includes infarction of the septum, the apex, and lateral portions of the LV. The infarction pattern is seen from lead (V1) V2 to V6, I + aVL

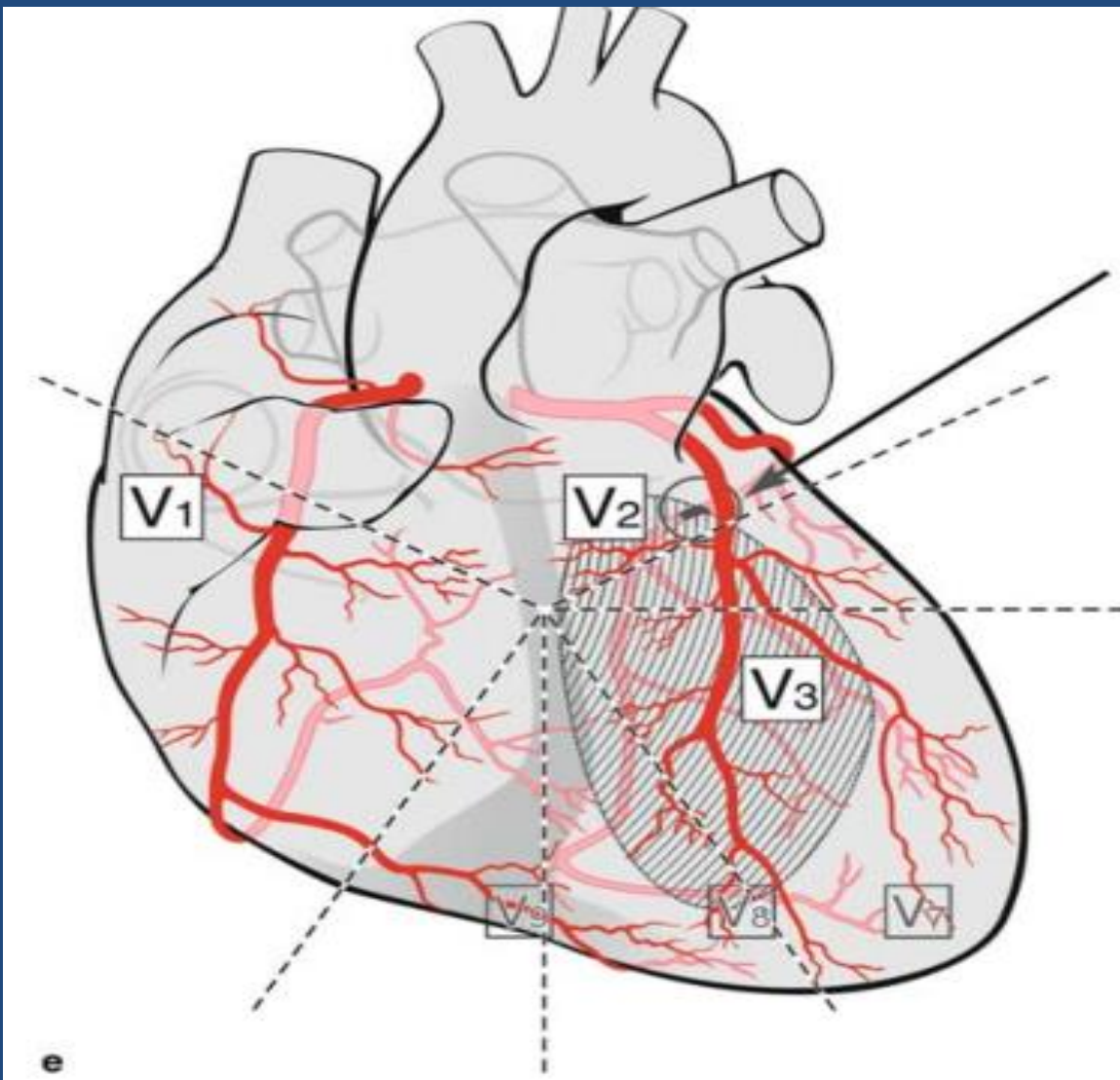
Examples



- c. Lateral Infarction (Isolated Myocardial Infarction of the lateral wall)- is rare in its isolated form. The typical pattern is seen in: V5 and V6 lead and might also be present in leads I and aVL.
- d. Inferior infarction

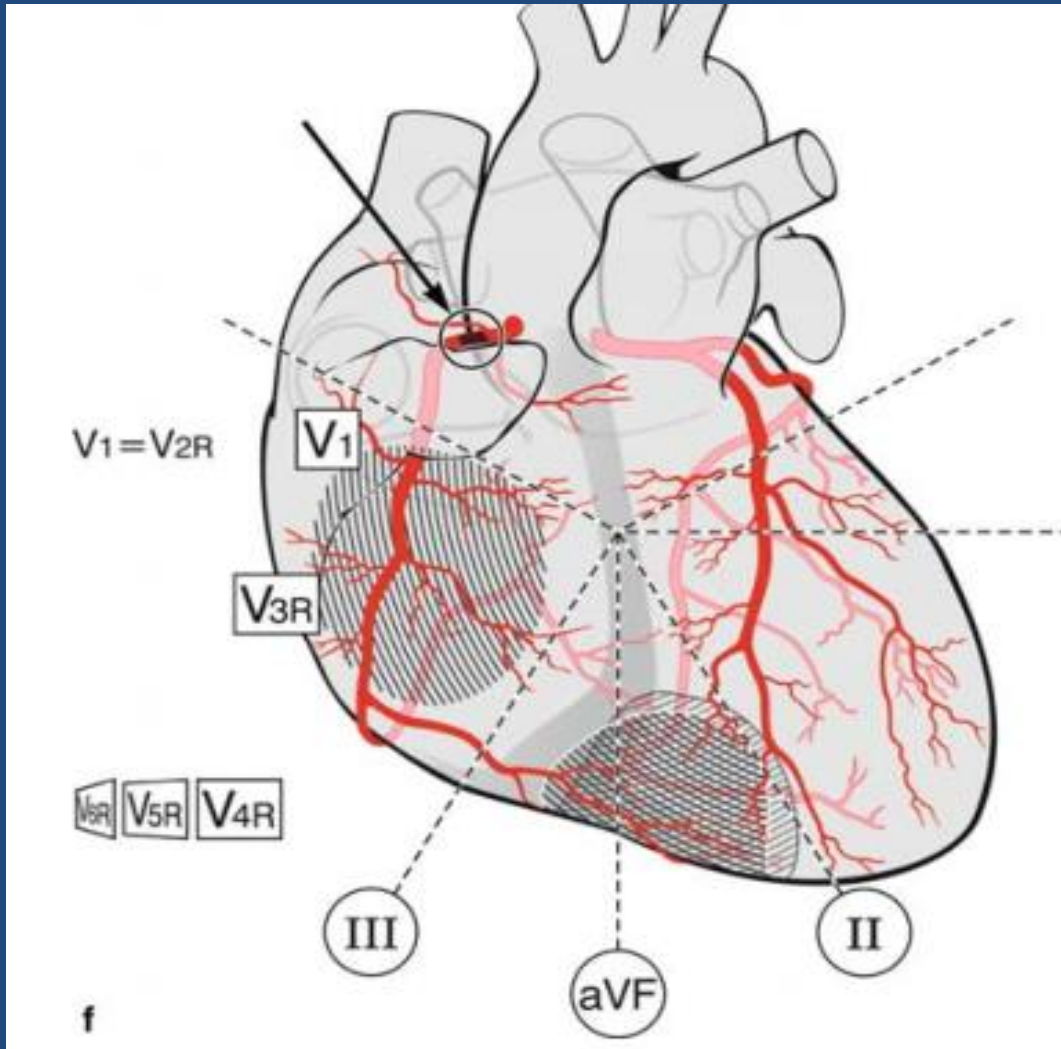
Examples

- ▣ Posterior infarction

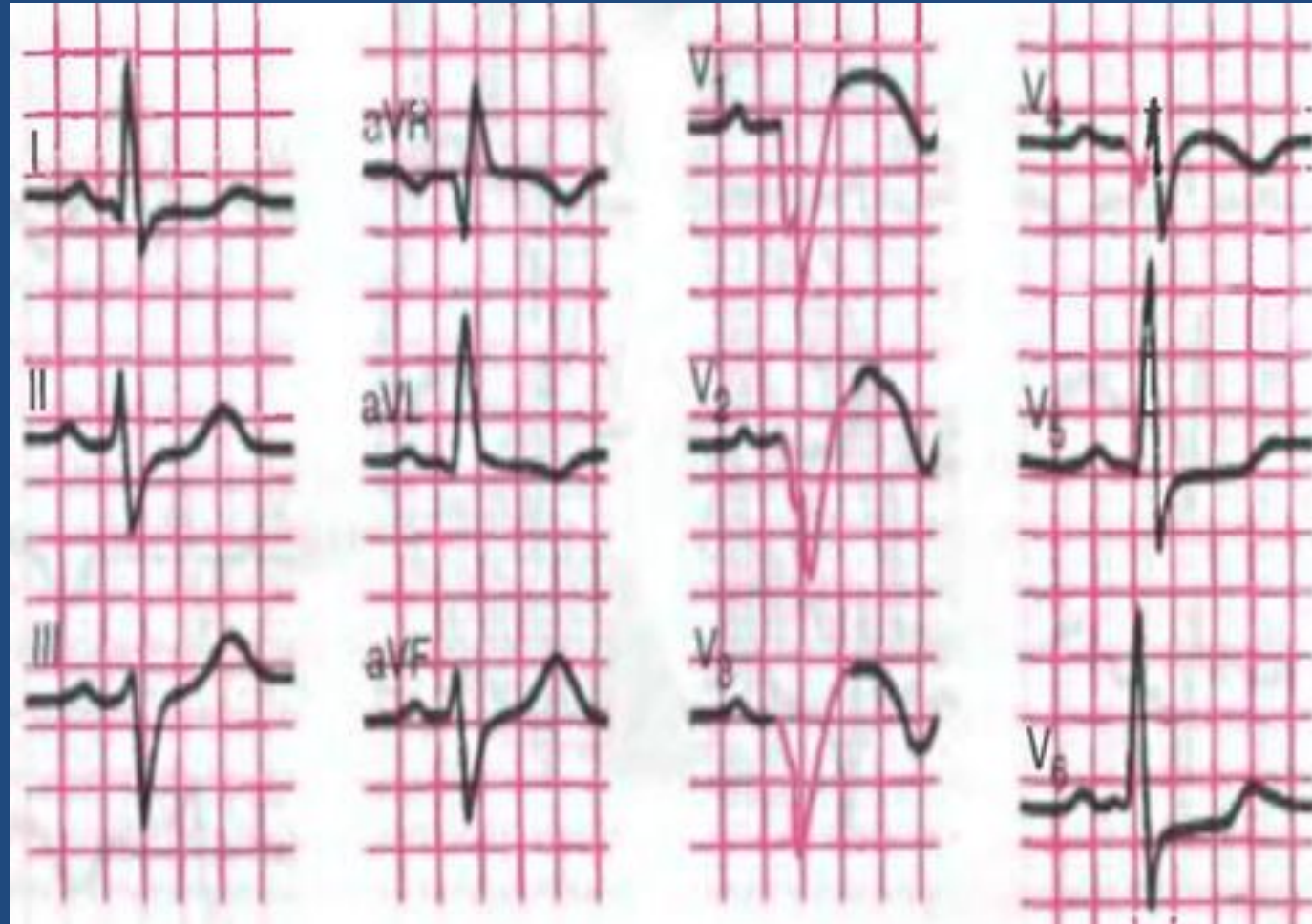


Examples

- Right ventricular 'infarction'
(combined to inferior infarction)

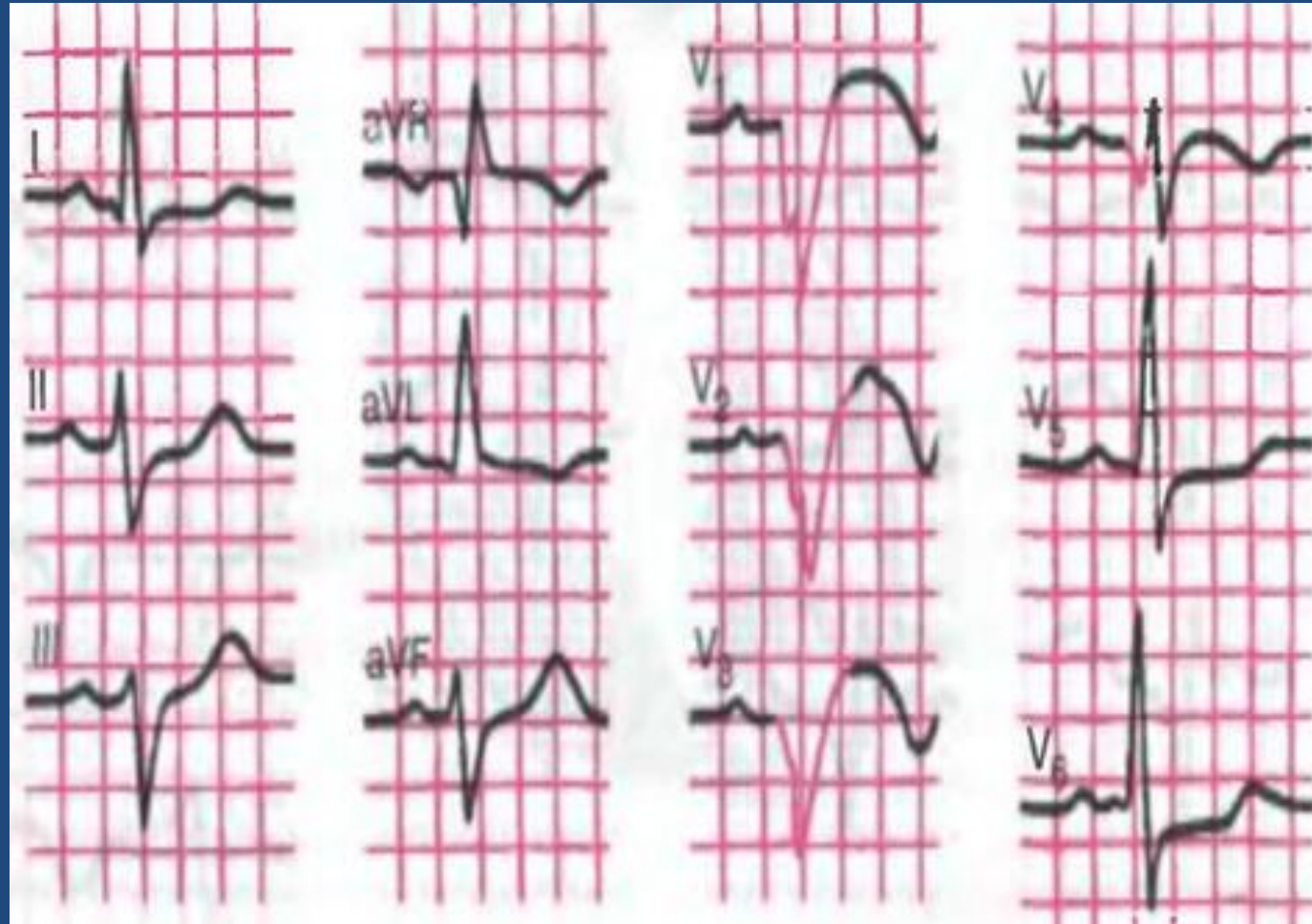


??????

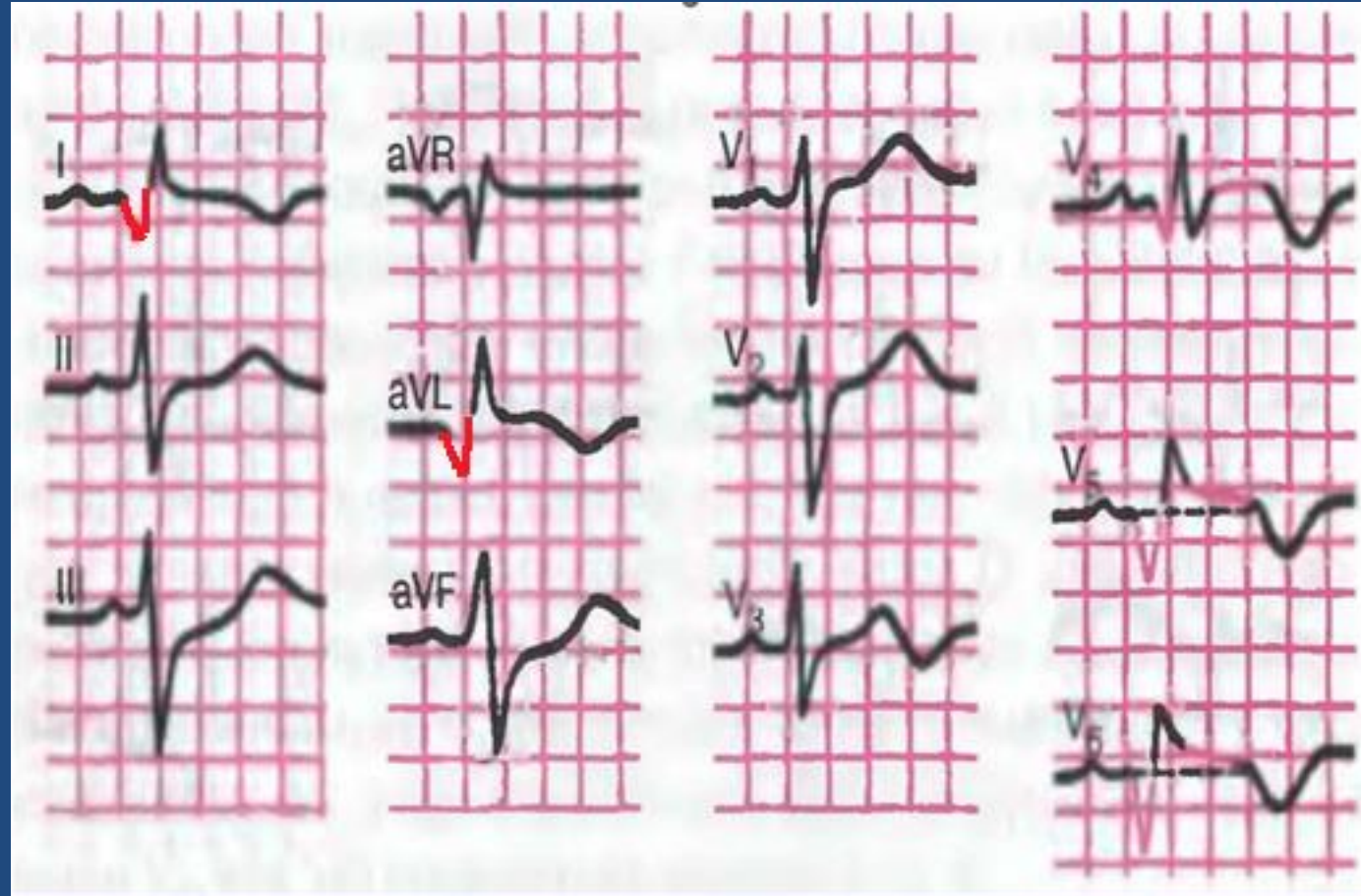


Antero-septal and apical AMI with Q wave

- Pathological Q wave V1-V4
- ST-segment elevation V1-V4 - direct changes

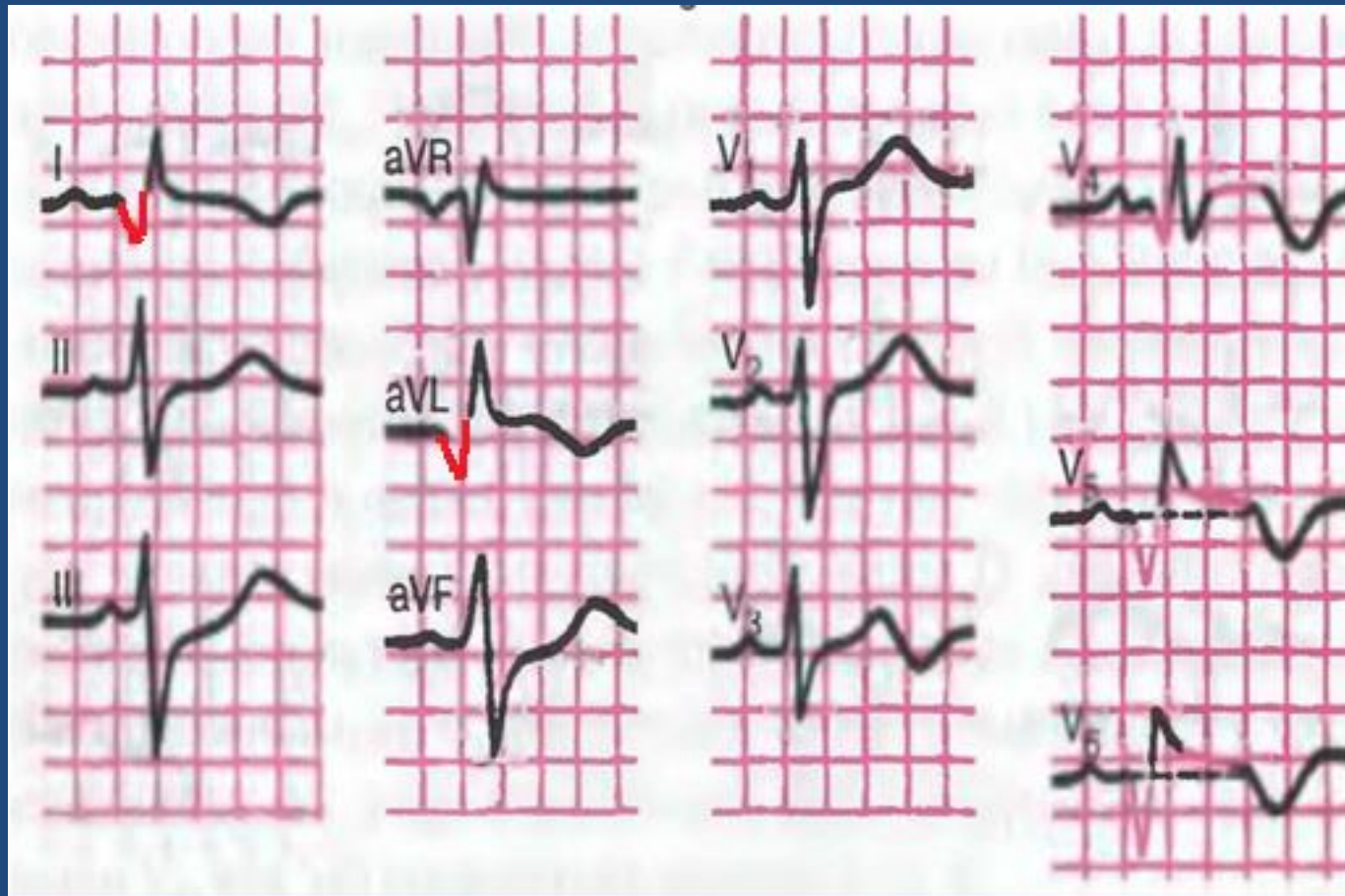


????

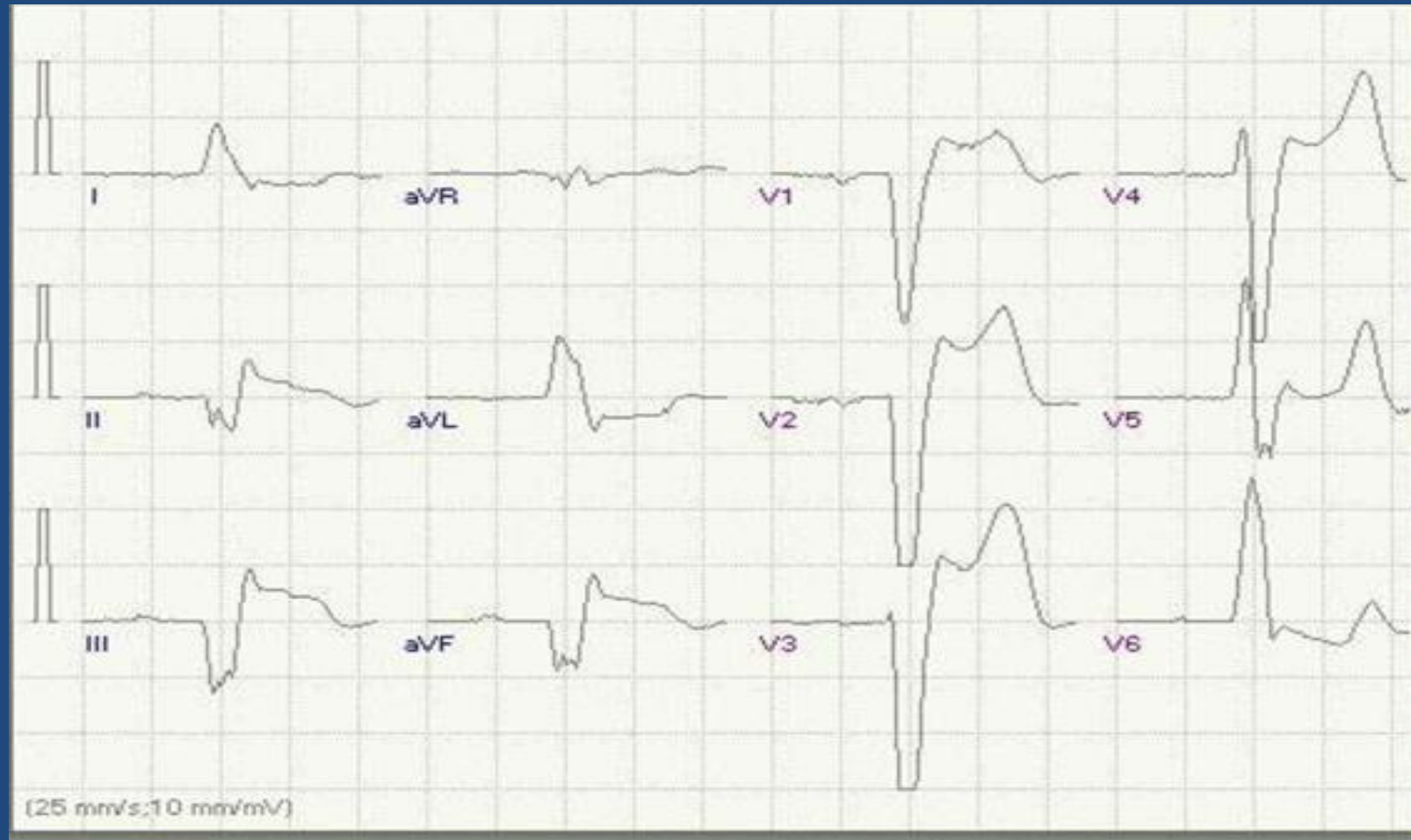


Antero-lateral AMI with Q wave

- Pathological Q wave DI, aVL, V4-V6
- ST elavation in DI, aVL, V4-V6 elevation - direct changes

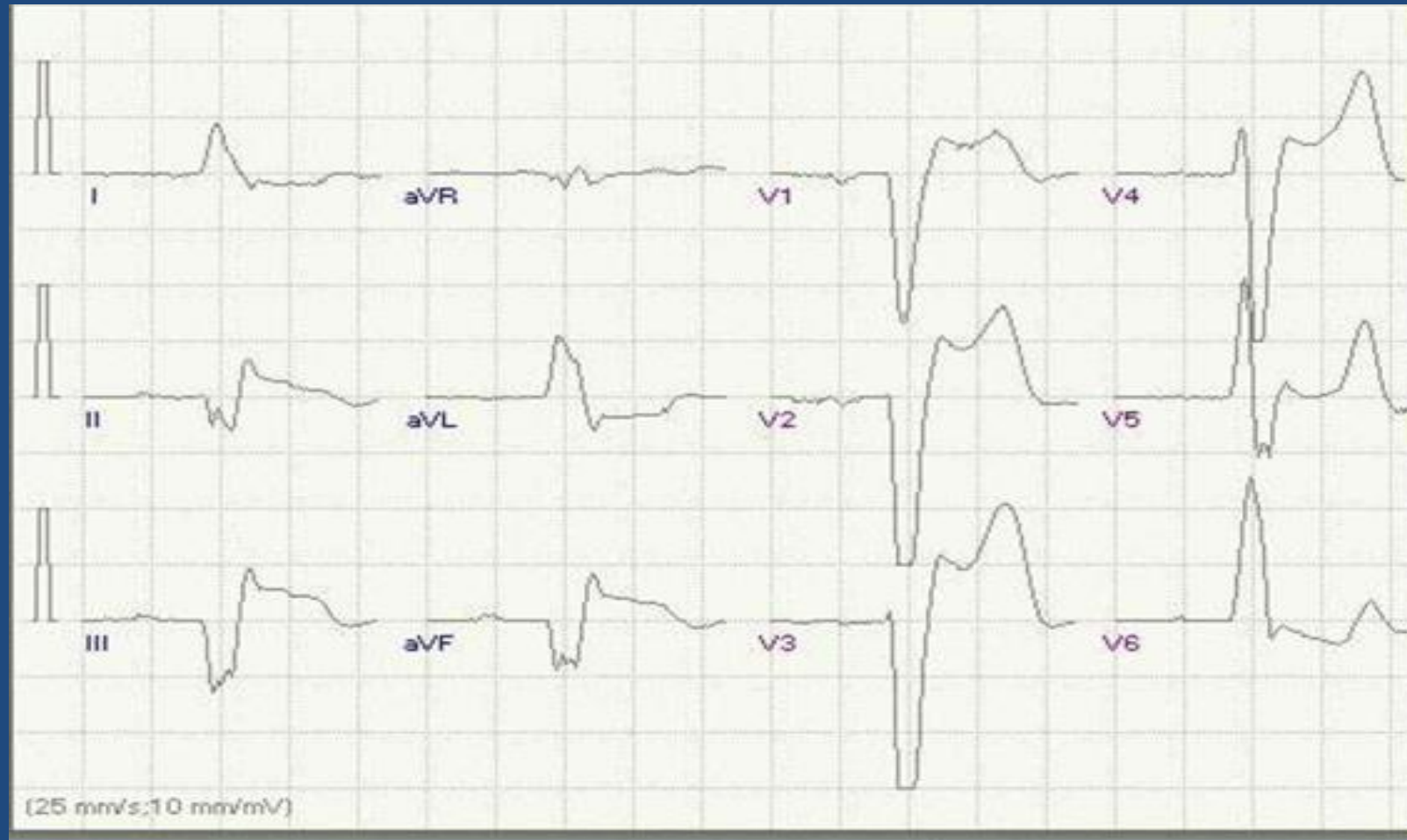


?????

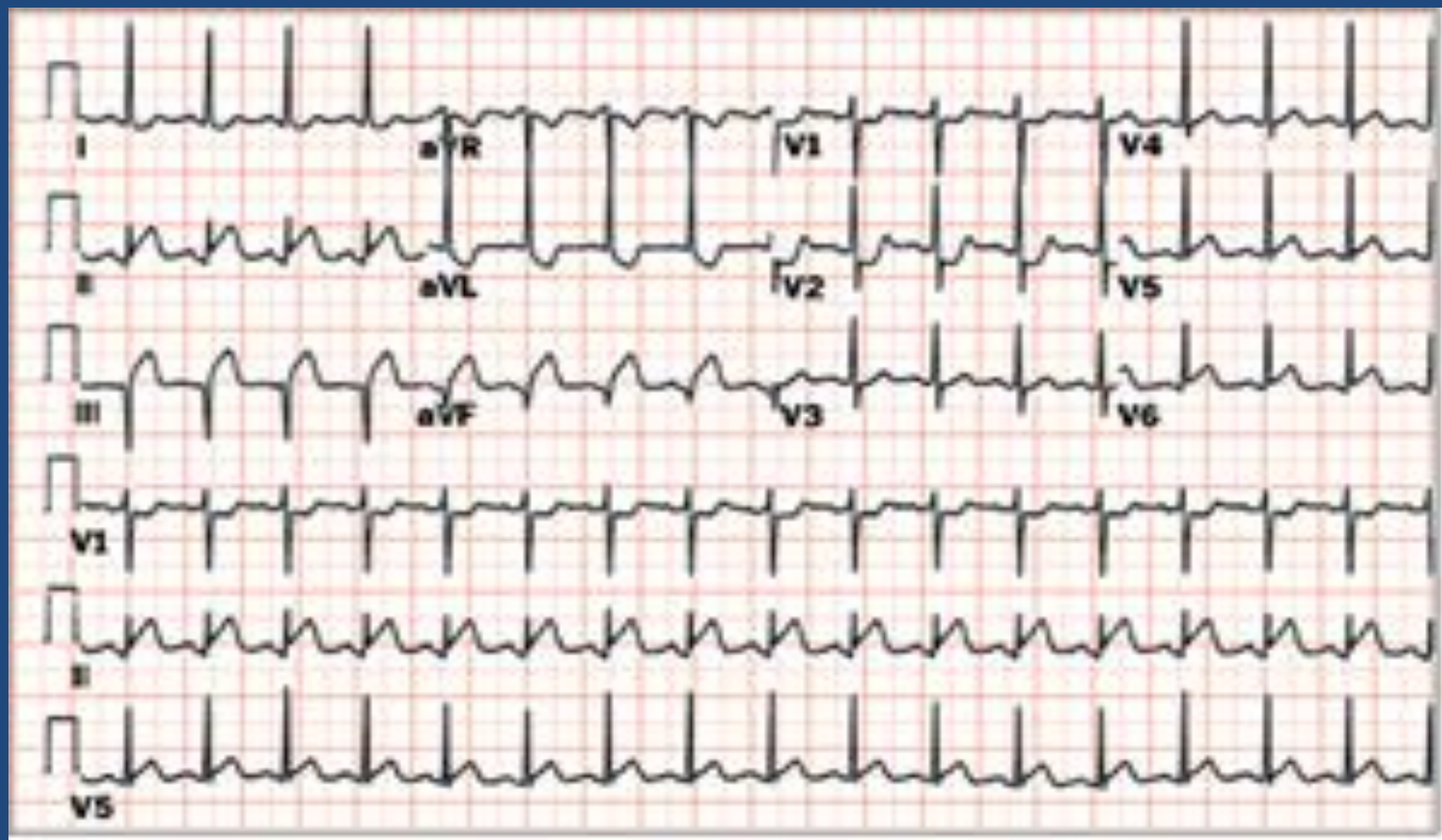


Antero-inferior (septal) AMI with Q wave

- ST elevation DII, DIII, aVF, V1-V4 - direct changes

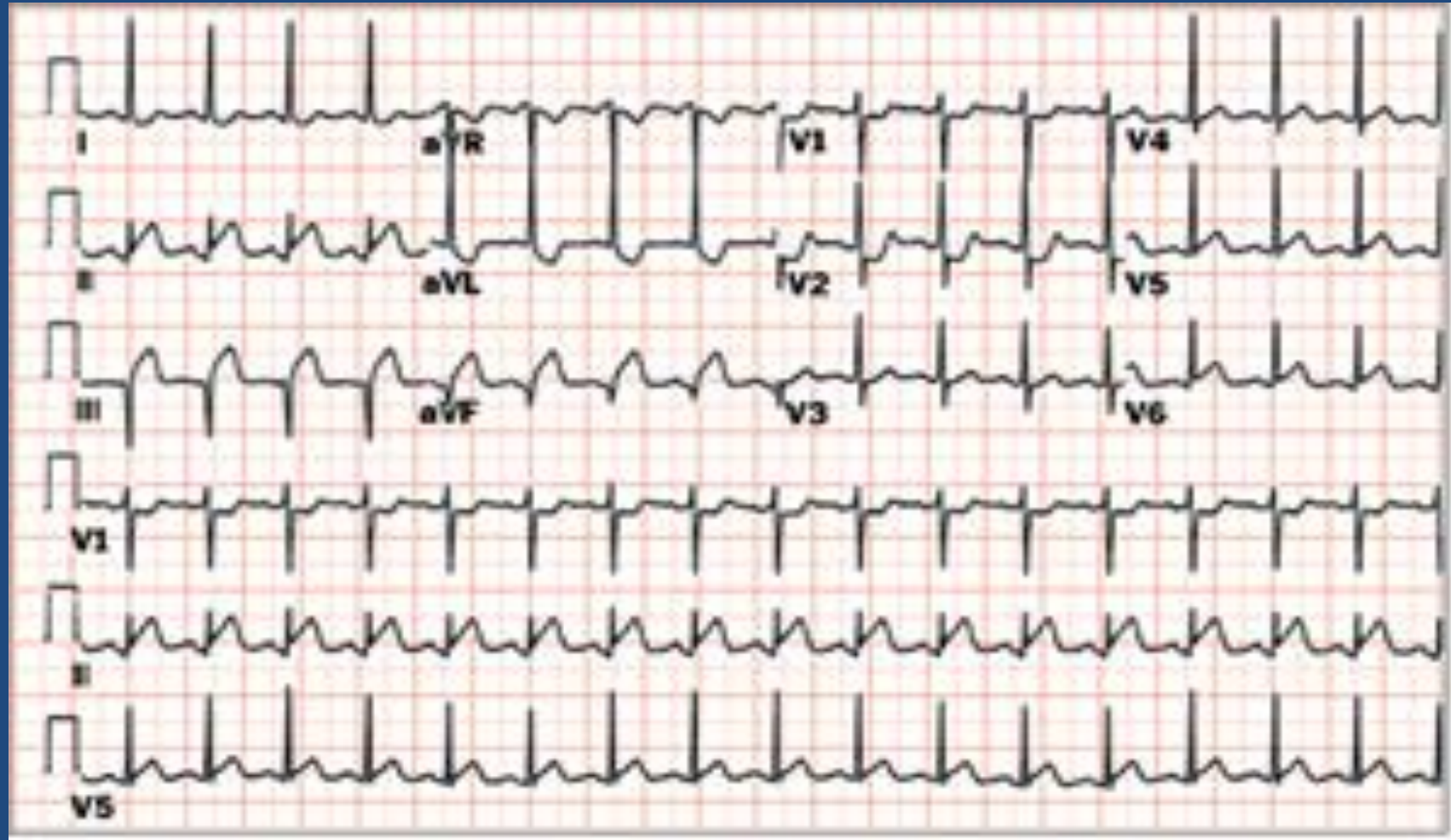


?????

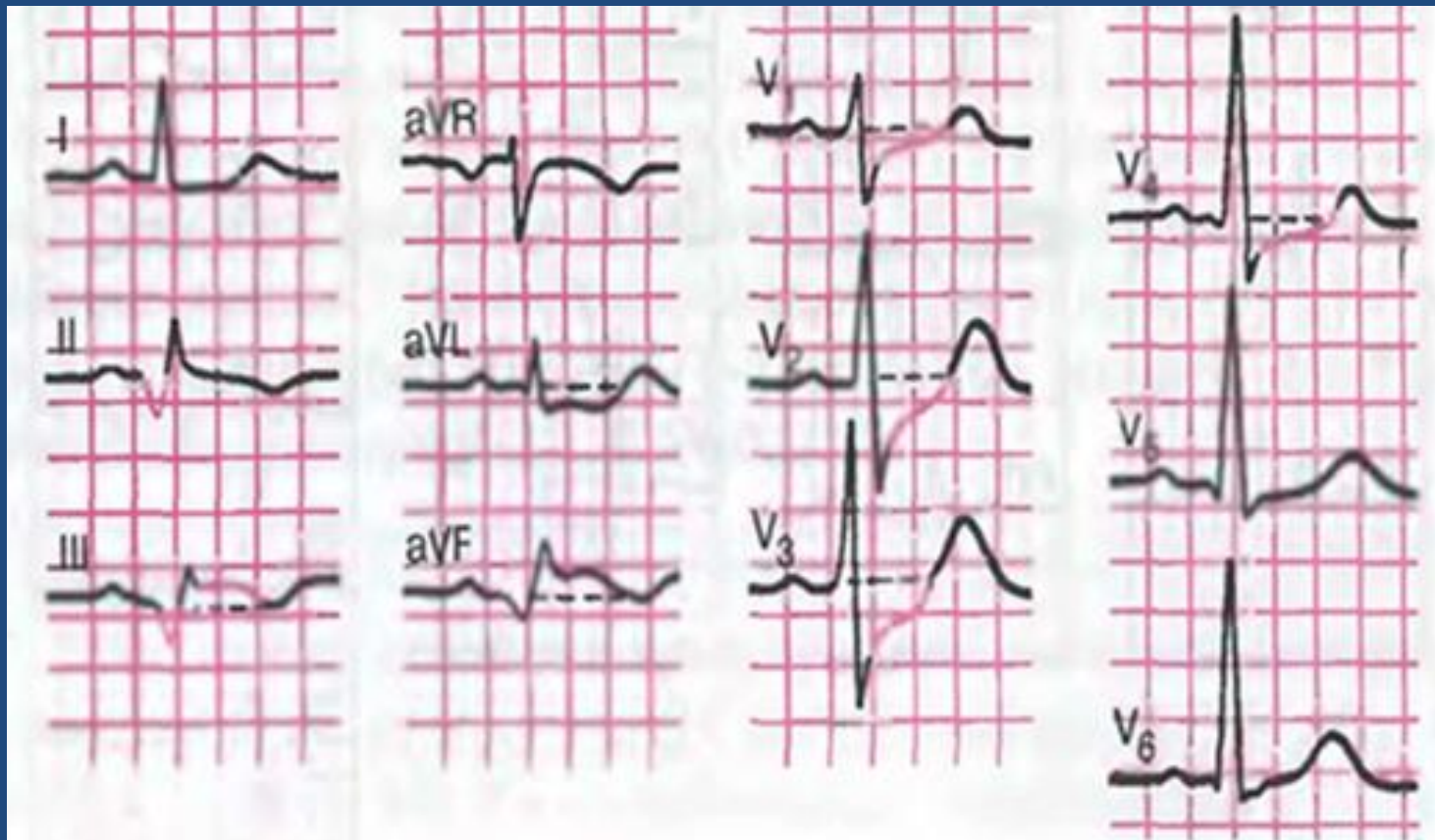


Inferior AMI with Q wave

- ST elevation DII, DIII, aVF - direct changes
- ST depression V1, V2 - mutual modifications „in the mirror“

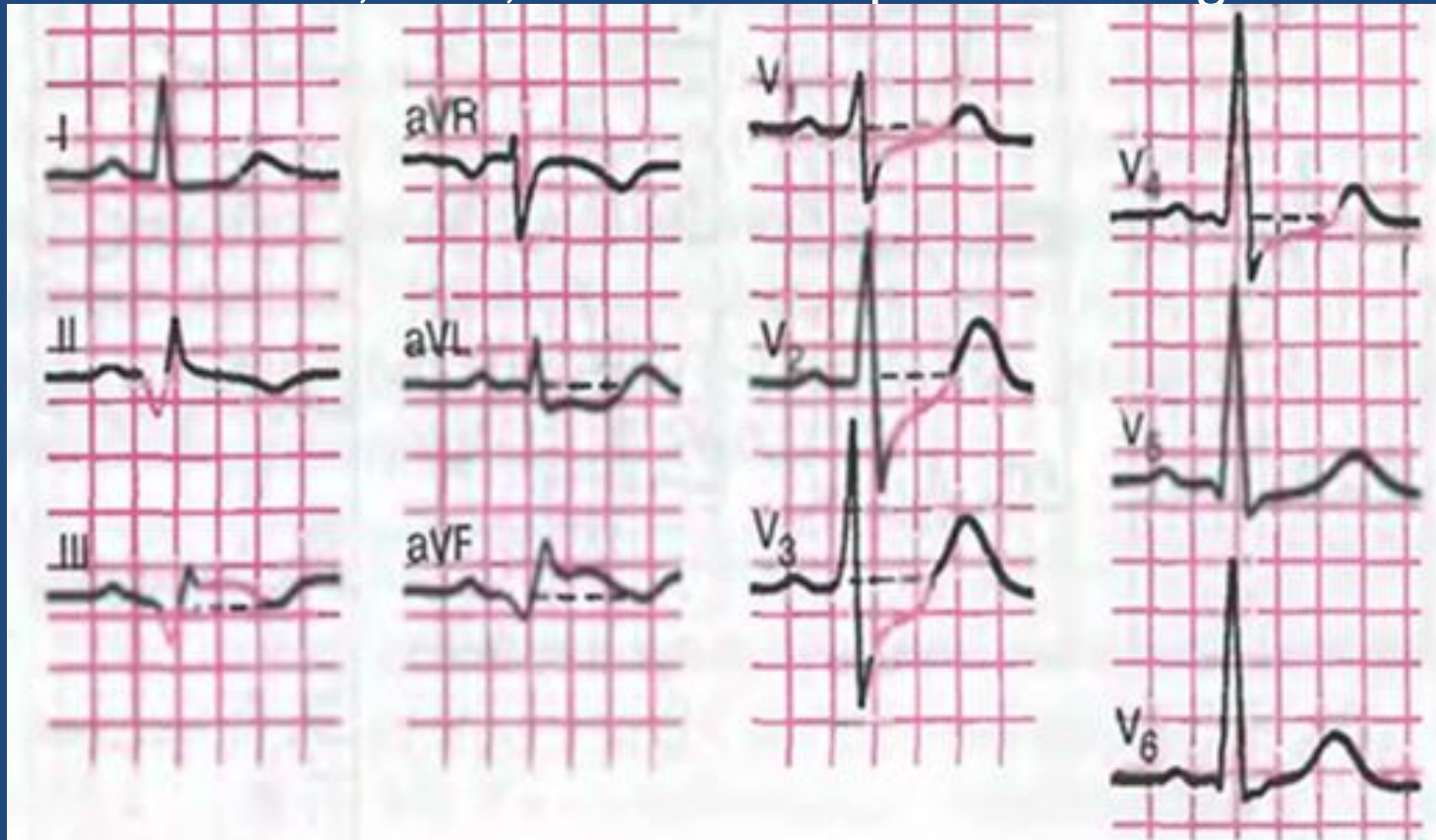


?????

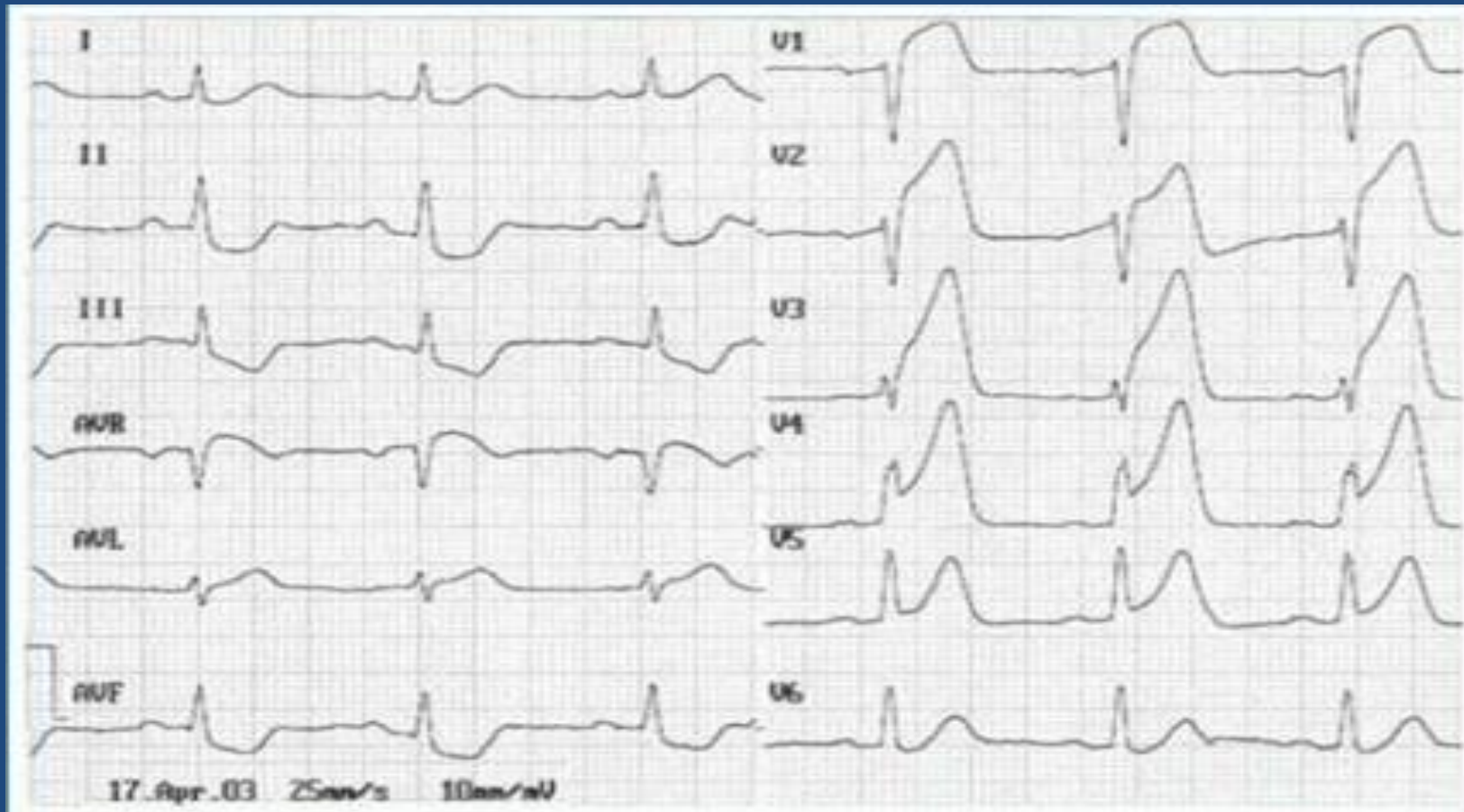


AMI inferior (postero-diafragmal) with Q wave

- Pathological Q wave DII, DIII, aVF
- ST. elevation (DII), DIII, aVF - direct changes
- ST depression in DI, aVL, V1-V4 - reciprocal changes "in the mirror"

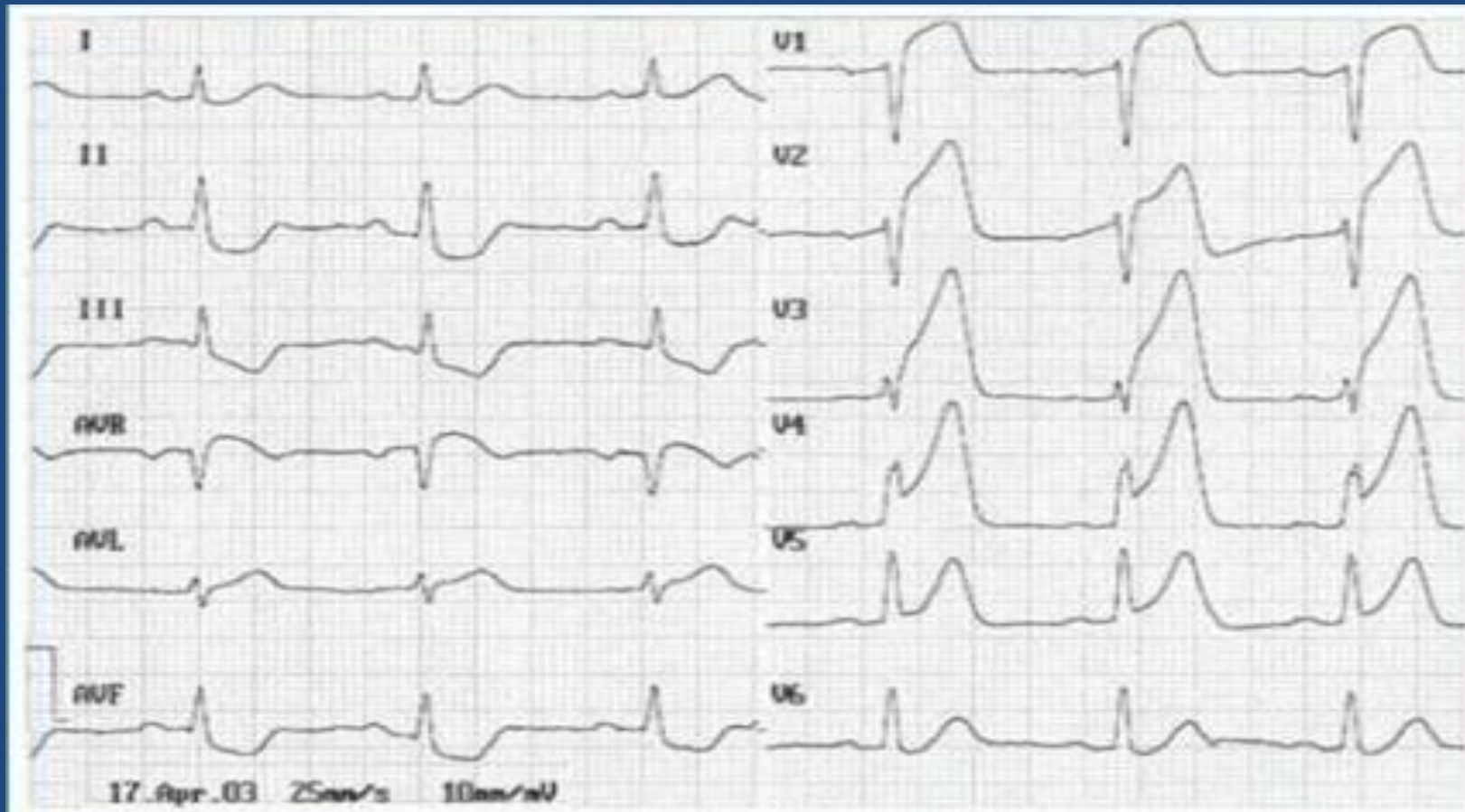


????

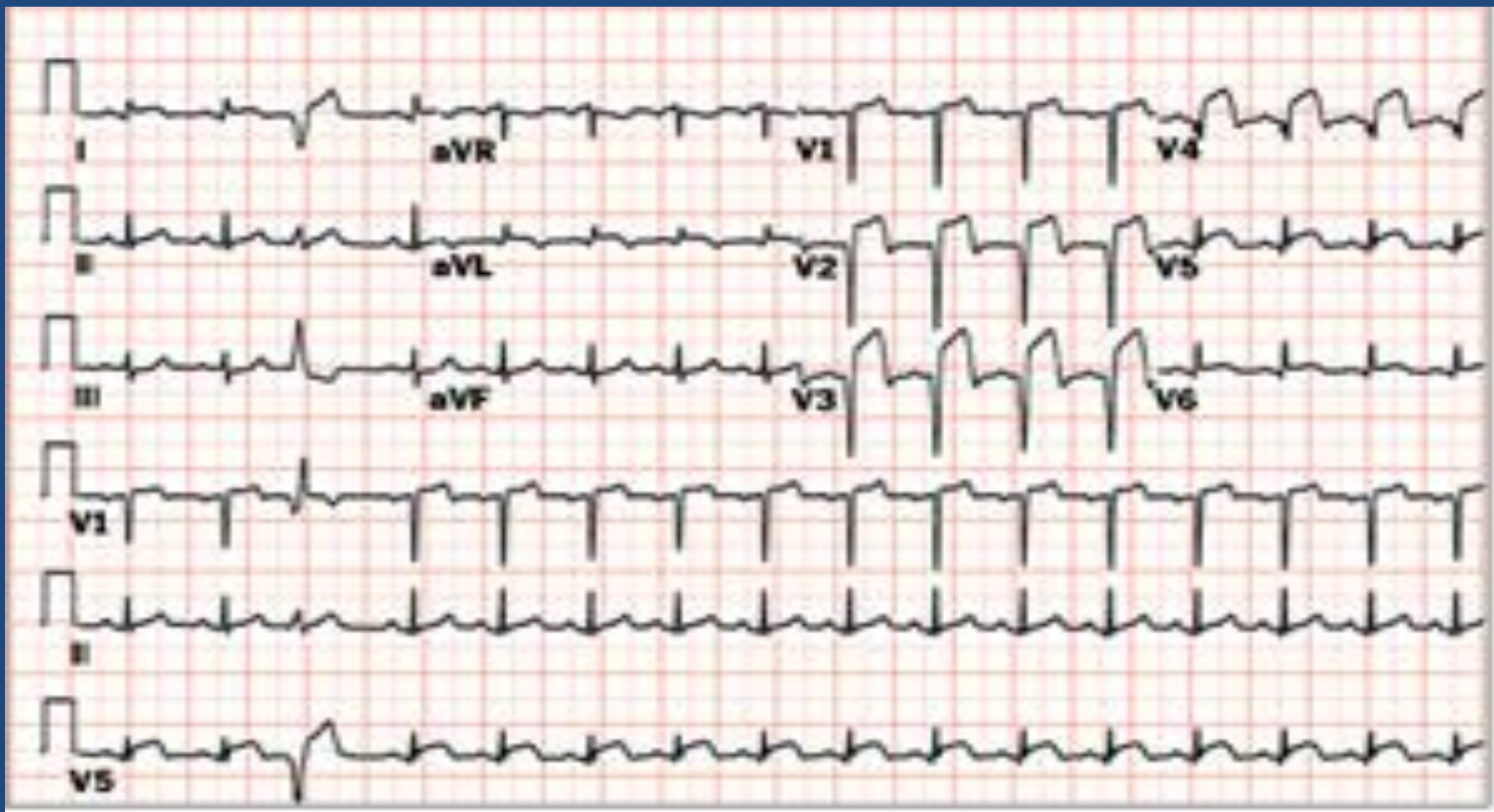


ANTERIOR EXTENDED AMI WITH Q WAVE

- ST elevation V1-V5 - direct changes
- ST depression DII, DIII, aVF - mutual modifications "mirror"

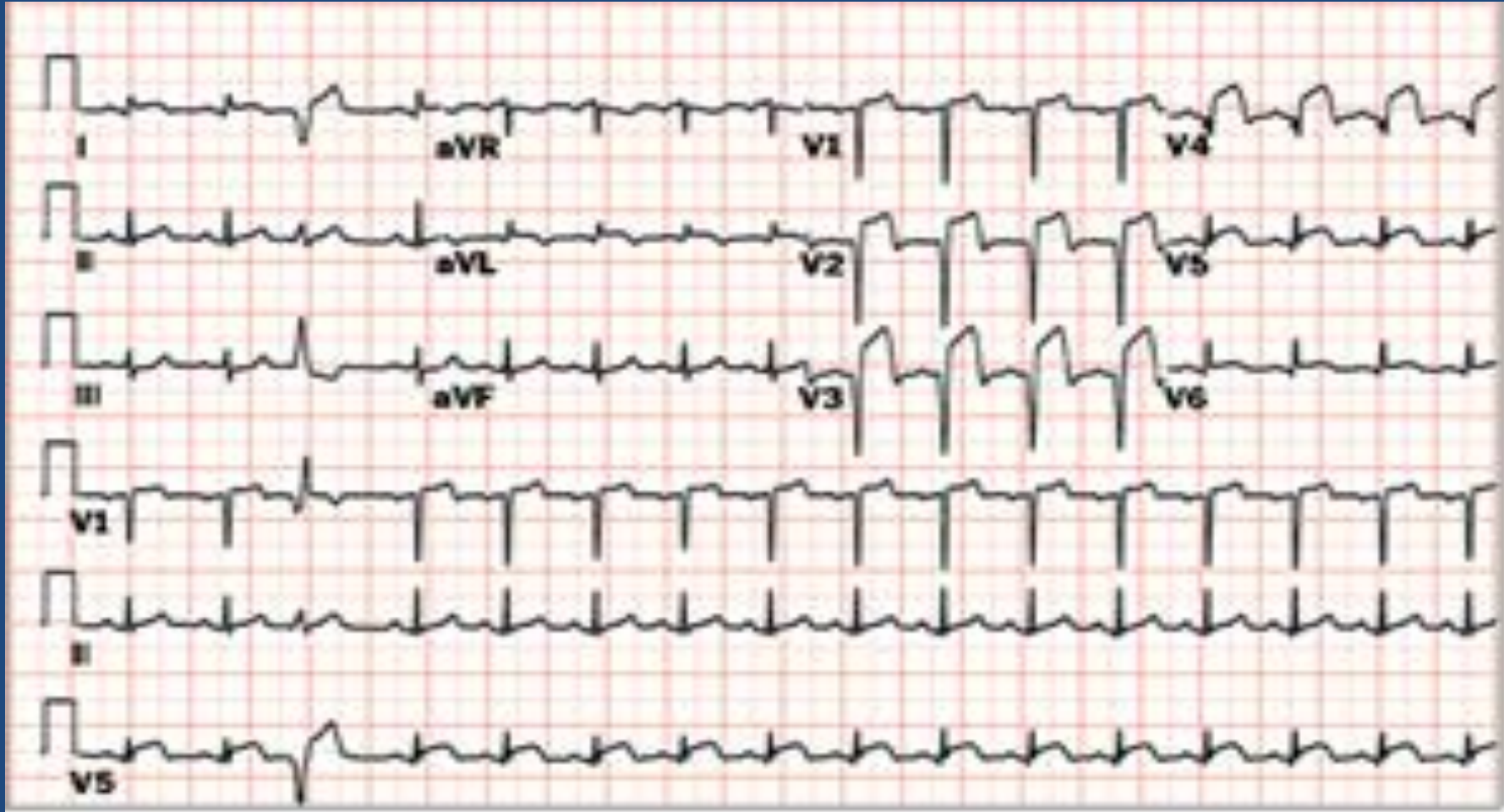


?????



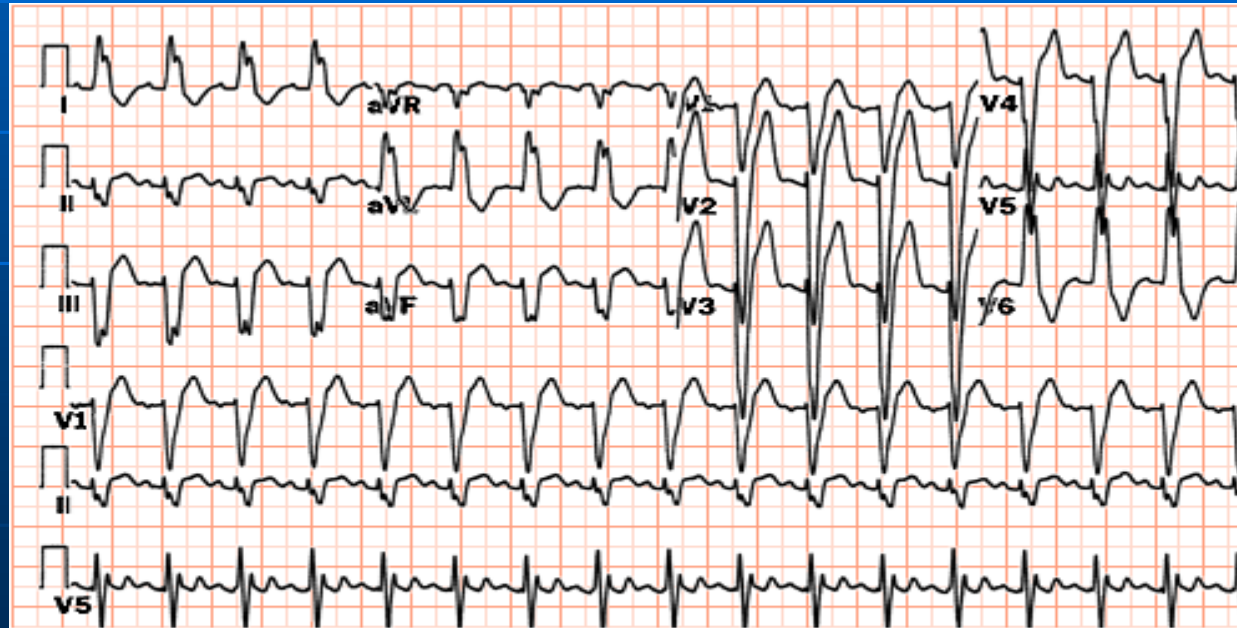
ANTERIOR AMI WITH Q WAVE

- ST-segment elevation V1-V4 - direct changes
- ST segment depression DII, DIII, aVF - mutual modifications "mirror"



complete left Hiss Bundle block

- supraventricular rhythm,
- QRS duration $\geq 0,12$ Deformed QRS, enlarged with a plate in DI, aVL, V5, V6,
- Q waves absent in V5, V6,
- intrinsic deflection ≥ 0.08 sec in V5, V6 (N = 0.04 sec)
- S-T, T are opposite to the main QRS wave,
- the electric axis is moved to the left
- If the QRS duration is between 0.1-0.12 sec the left branch block is incomplete.



ECG Figure 41. Left bundle branch block. Wide QRS complex, negative in lead V1, is associated with secondary T wave inversions.

ECG IN AMI WITH COMPLETE LEFT HISS BUNDLE BLOCK

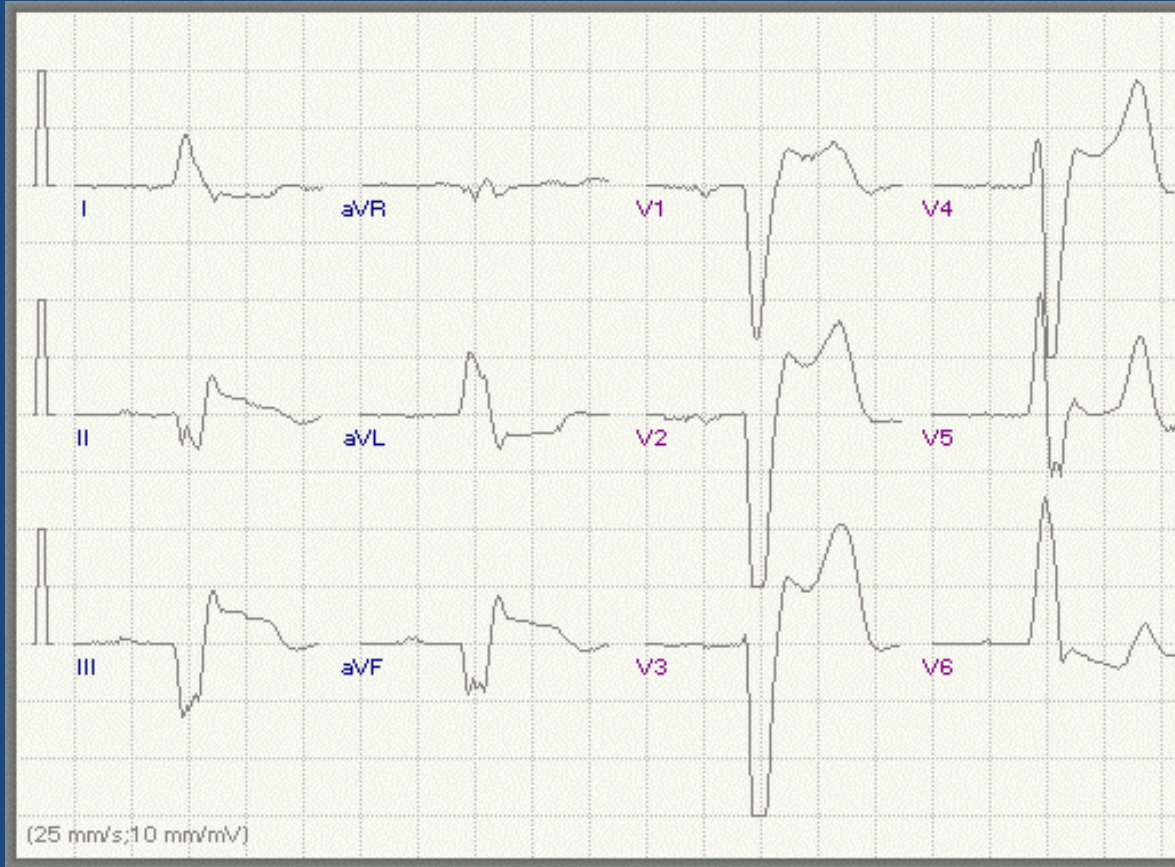
- Frequent diagnosis is difficult and sometimes impossible to establish. Direct signs of AMI are missing in most cases, the diagnosis is established by "minor" signs and by the dynamic evolution of the ECG:
- the appearance of the Q wave in V5 and V6 is an indirect sign of necrosis of the anterior wall of the LV
- absence of R-wave growing in V1-V4
- positive T wave in V5 și V6 – indicates anterior myocardial infarction on the background of the left branch block of the Hiss bundle

ECG IN AMI WITH COMPLETE LEFT HISS BUNDLE BLOCK

5 ECG criteria of AMI in LHBB:

- the dynamic evolution of the ST segment in the first 2-5 days after the onset of AMI
- ST elevation > 2 mm concordant with QRS or > 7 mm discordant with QRS
- pathological Q wave in DI, aVL, V6 or DIII, aVF
- notch on the ascending side of the S wave in V3 or V4 (sign Cabrera)
- excessive depression (> 5 mm) of ST segment in block complexes

ECG IN AMI WITH COMPLETE LEFT BUNDLE BLOCK



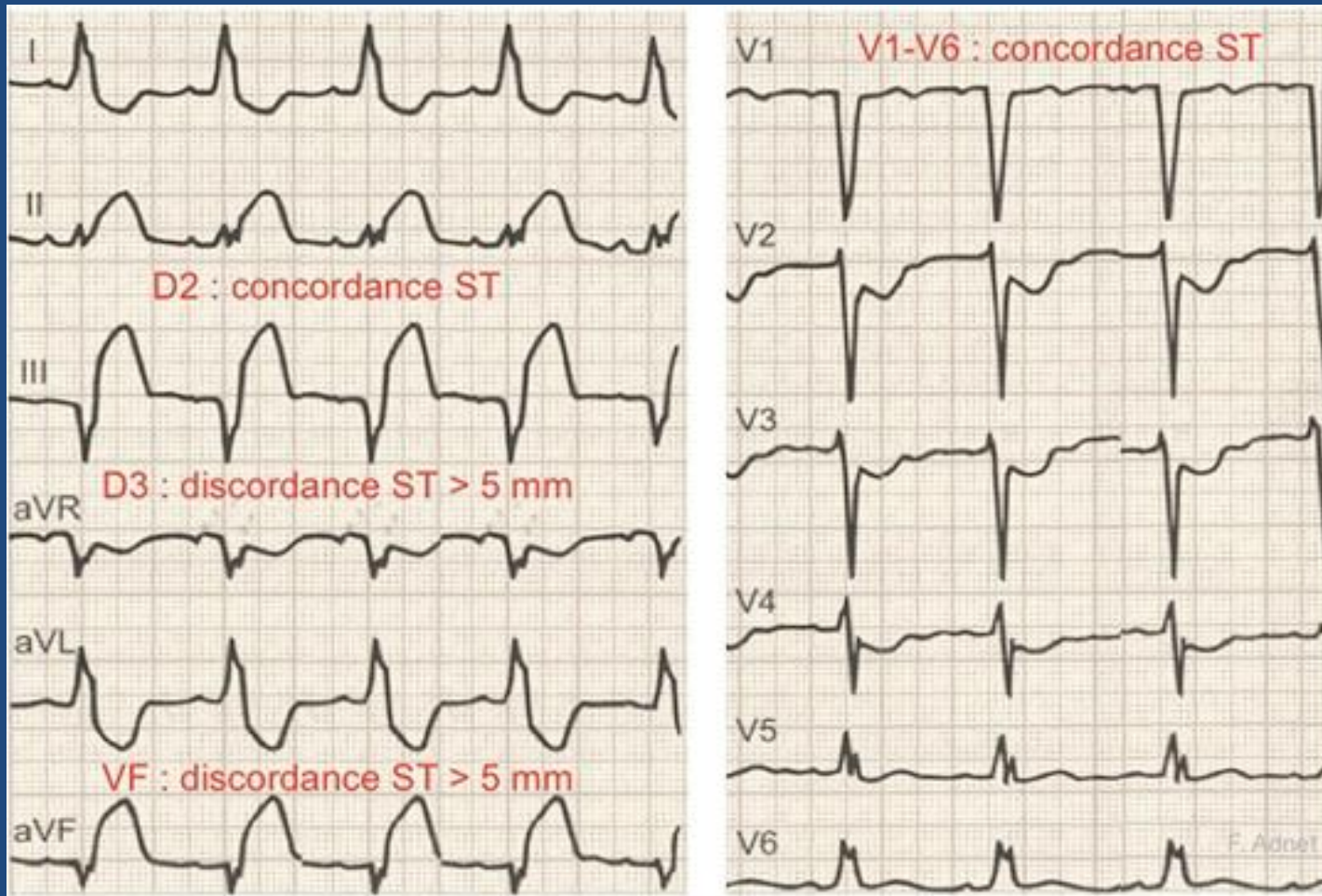
Patient, 56 years old, hypertensive and chronic coronary. An angina attack appeared 3 hours ago, which did not resolve after nitroglycerin. A medical ambulance was called.

On ECG: signs of LHBB (QRS = 0.17 sec., V6, DI, aVL type R).

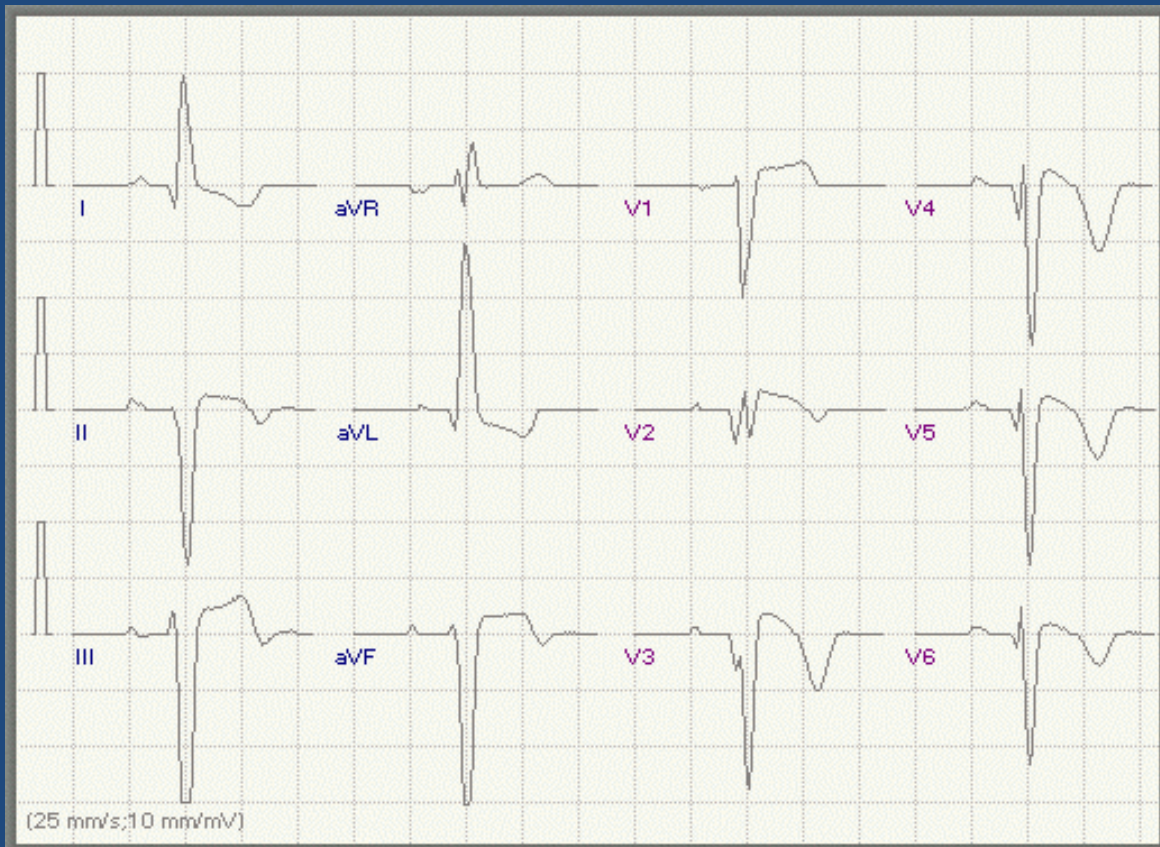- In DII, DIII, aVF pathological Q wave (QS), seg.ST elevated, which are not characteristic for BCRS and indicate at lower IMA of LV.
- Wide "coronary" T waves in V4-V6 are possibly related to ischemia of the antero-lateral regions of the LV.

ECG IN AMI WITH COMPLETE LEFT Hiss Bundle BLOCK

□ LHBB + inferior AMI



ECG ÎN IMA CU BLOC DE RAM STÂNG ANTERIOR A FASCICOLULUI HIS



Patient, 49 years old, previously healthy. Last night had access chest pain that lasted 1 hours. Nitroglycerin was not administered. In the morning he went to the doctor.

- On ECG: signs of previously extended IMA (pathological Q in DI, aVL, V2-V6)
- Lack of R wave in DII, decrease of R in V2-V6. ST elevation in V1-V6; negative T wave in DI, DII, aVL, V2-V6.
- Anterior left hemiblock of f.Hiss (alpha angle: - 60 degrees. QRS = 0.10 sec).

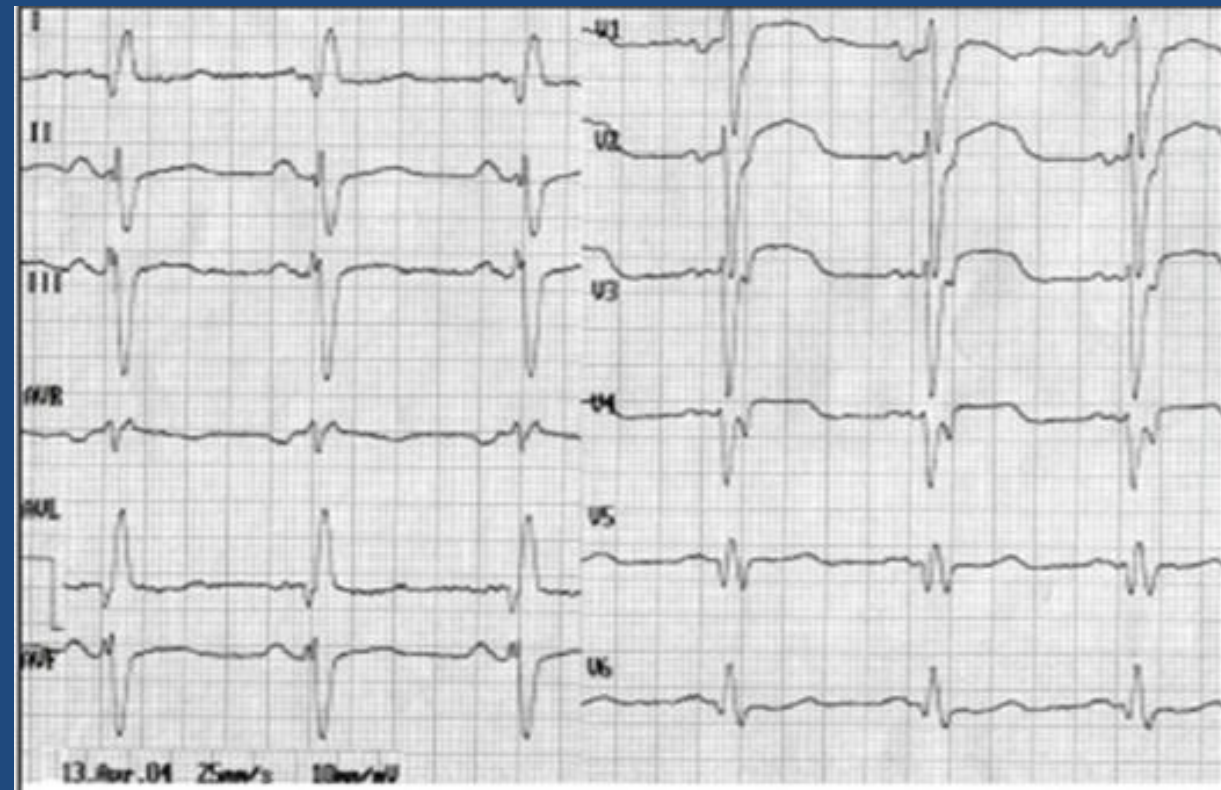
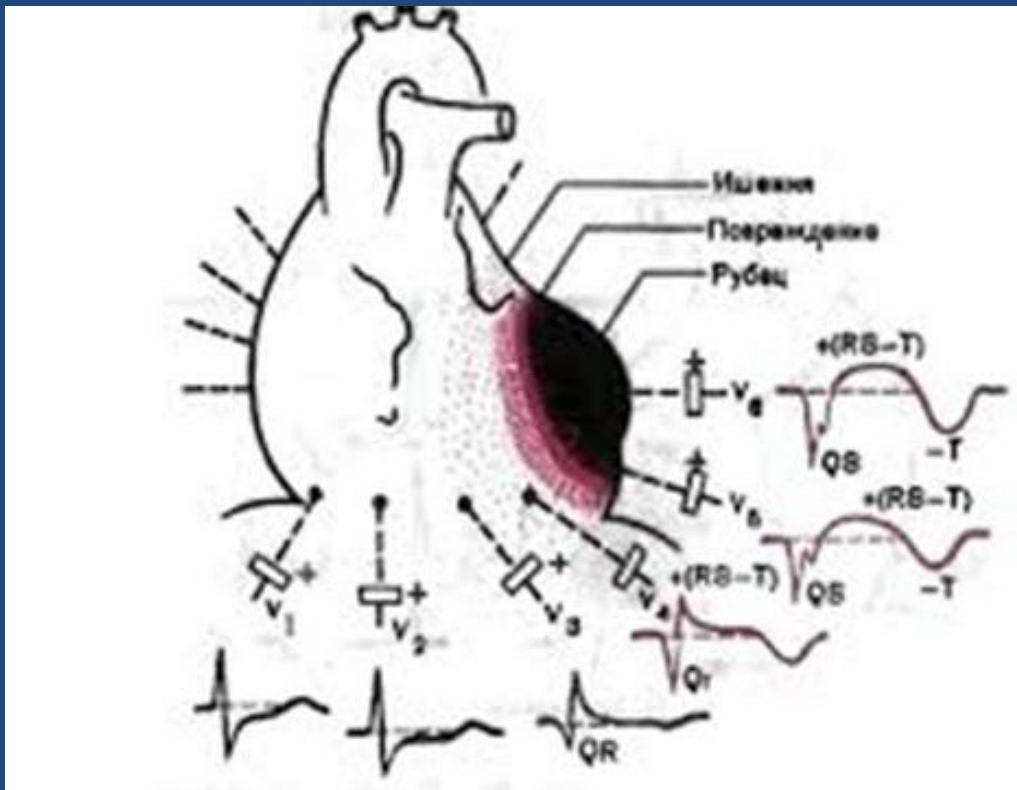
PARACLINICAL EXAMINATIONS

ECG changes are evolutionary:

- in the first minutes from onset: ECG may be normal
- in the first hours from the beginning: in the direct derivations appears “single-phase wave”: ST-level elevation, with the concavity downwards and the embedding of the T wave
- after 24h:
 - the Q wave of necrosis occurs
 - the T wave is negative
 - se reduce supradenivelarea seg. ST
- after a few weeks, the lesion and ischemia resolve:
 - ST returns to the isoelectric line
 - T wave becomes positive
 - Q wave necrosis persists
- the “frozen” aspect of the ECG, with the persistence of elevation seg. ST and T (-) wave: suggests the evolution to LV aneurysm

LEFT VENTRICULAR ANEURYSM

- Chronic apical aneurysm in VS. ST elevation ST V2-V4, pathological Q DI, aVL, V5-V6



STAGES OF IMA EVOLUTION

1. Initial acute (superacute - hours, rarely 2-3 days),
2. Acute set up (up to a week),
3. Subacute (1-2 weeks to a few weeks),
4. Cicatrisation (up to 8 weeks)

ECG in ST elevation myocardial infarction (STEMI)

A STEMI is a type of myocardial infarction that is characterised by ST elevation on the ECG in certain lead areas termed territories.

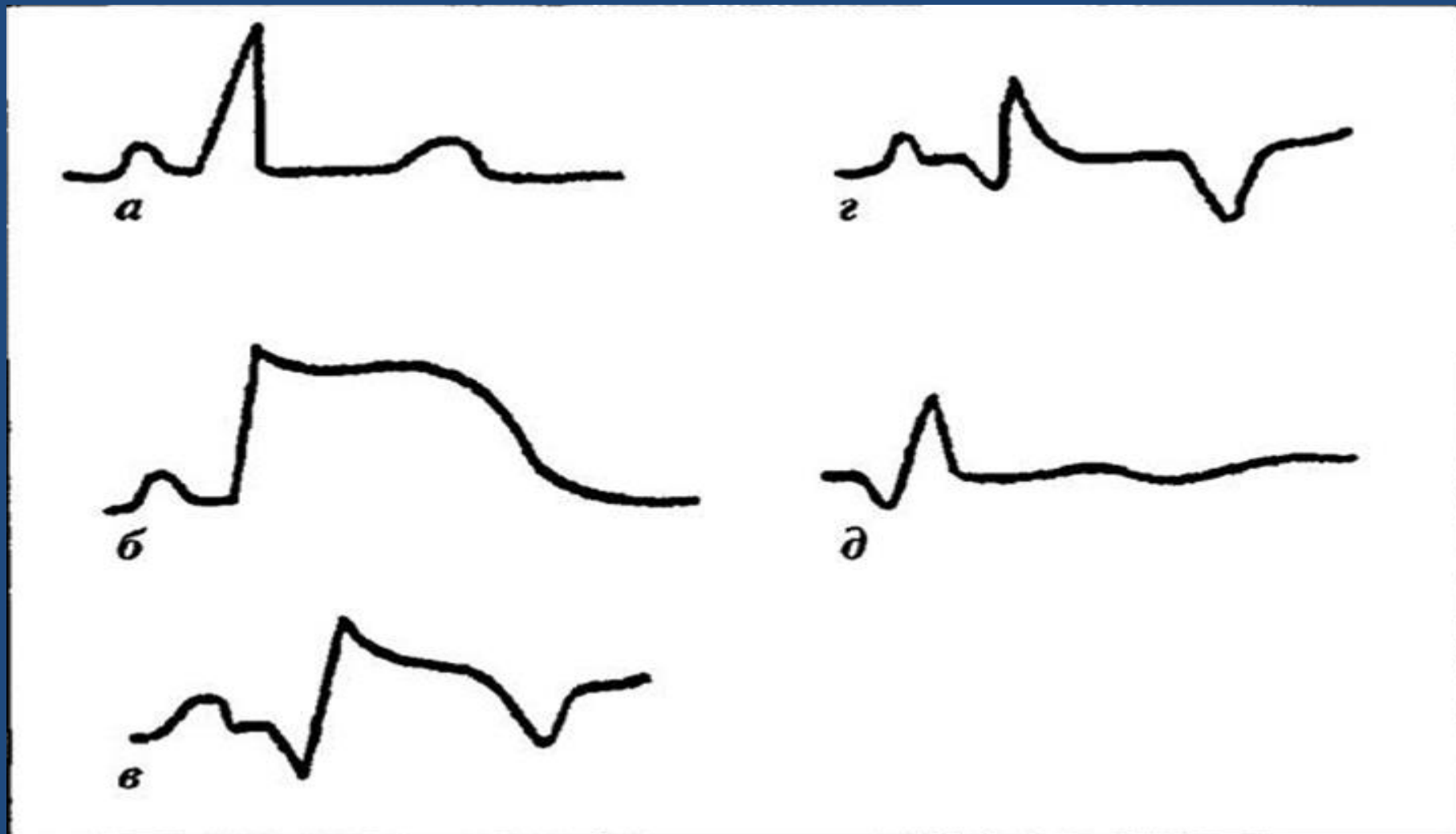
ST elevation indicates myocardial injury as the injured area or zone that surrounds the zone of infarction remains electrically positive, leading to ST elevation.

Regarding the electrophysiologic evolution, three stages can be distinguished, each one characterized by typical alterations of repolarization and depolarization:

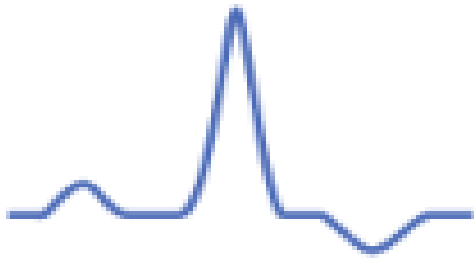
- ▣ 1. Acute stage: marked ST elevation (generally >3 mm, up to 12 mm). This represents transmural lesion (also referred to as transmural injury).
- ▣ 2. Subacute stage: moderate ST elevation plus Q waves or QS waves. This represents minor injury and necrosis. The T wave is generally negative and symmetric, representing ischemia.
- ▣ 3. Chronic or old stage: “classical” Q waves (duration ≥ 0.04 s) or QS waves, with isoelectric ST segment. A Q wave or QS wave attributable to infarction represents necrosis. The T wave remains negative or has normalized.

STAGES OF IMA EVOLUTION:

A- ECG normal; B-supraacut (acute initially); C-acut; D-subacut; E- cicatrisation.




Morphological changes to the ECG waveform from ischemia to necrosis



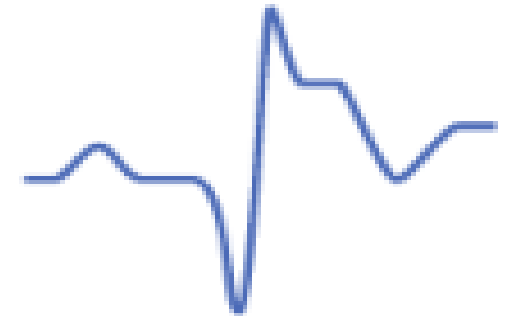
Ischemia

T wave and/or ST segment changes caused by altered repolarisation



Injury

ST elevation indicates myocardial injury




Infarction

Pathological Q waves indicating infarction and necrosis of cardiac tissue

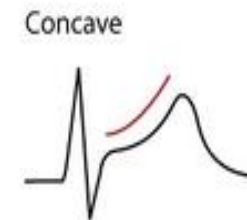
Characteristics of ischemic ST elevations

A Characteristics of ST-segment elevations caused by ischemia




ST-segment elevations caused by ischemia typically displays a convex or straight ST-segment. Such ST-segment elevations in presence of chest discomfort are strongly suggestive of transmural myocardial ischemia. Note that the straight downsloping variant is unusual.

B Typical non-ischemic ST-segment elevation



Non-ischemic ST-segment elevations are extremely common in all populations. They are characterized by a concave ST-segment and a greater distance between the J point and the T wave apex.

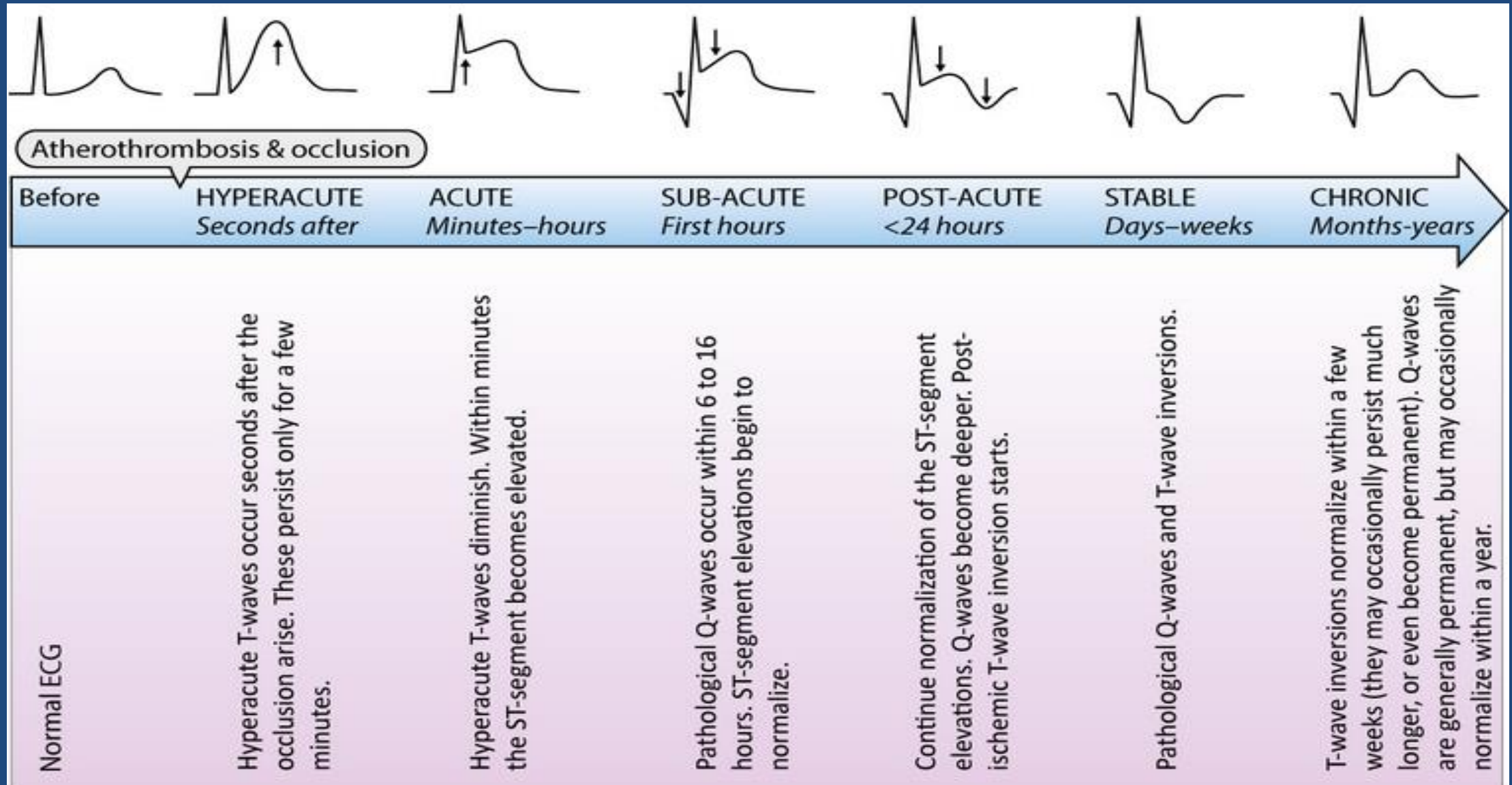
C Examples of ST-segment elevations caused by ischemia



ST-segment elevation can vary markedly in appearance. These six examples were retrieved from six different patients with STEMI.

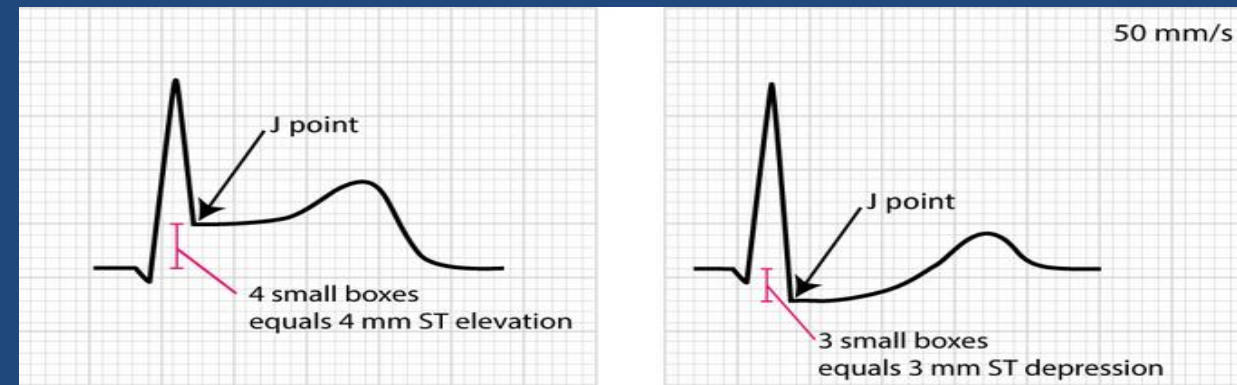ST segment elevations with straight (horizontal, upsloping or downsloping) or convex ST segment strongly suggest acute transmural ischemia

The electrocardiographic natural course in STEMI



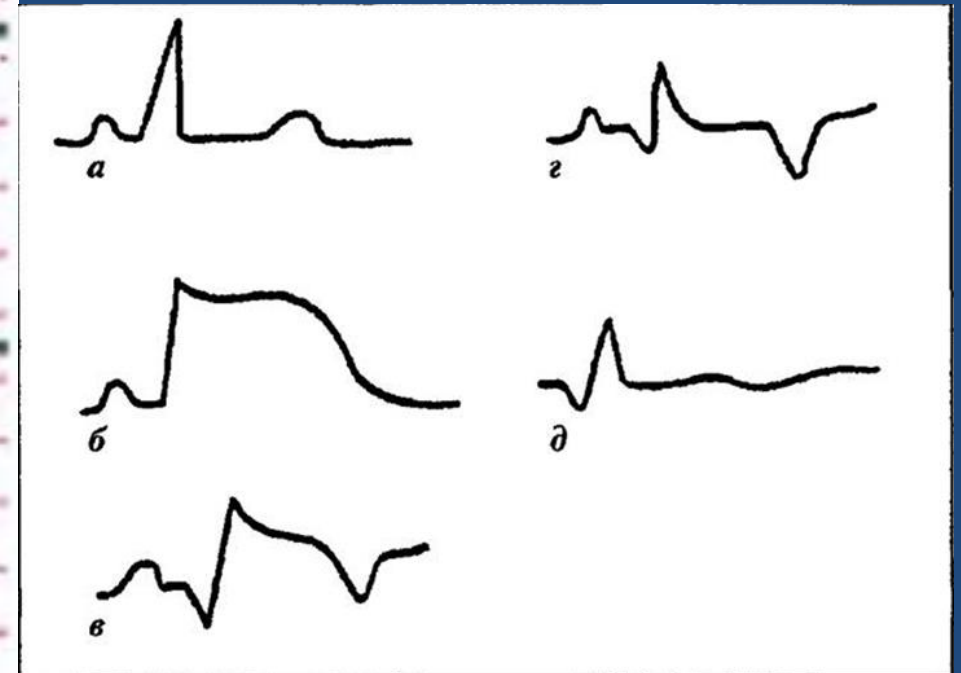
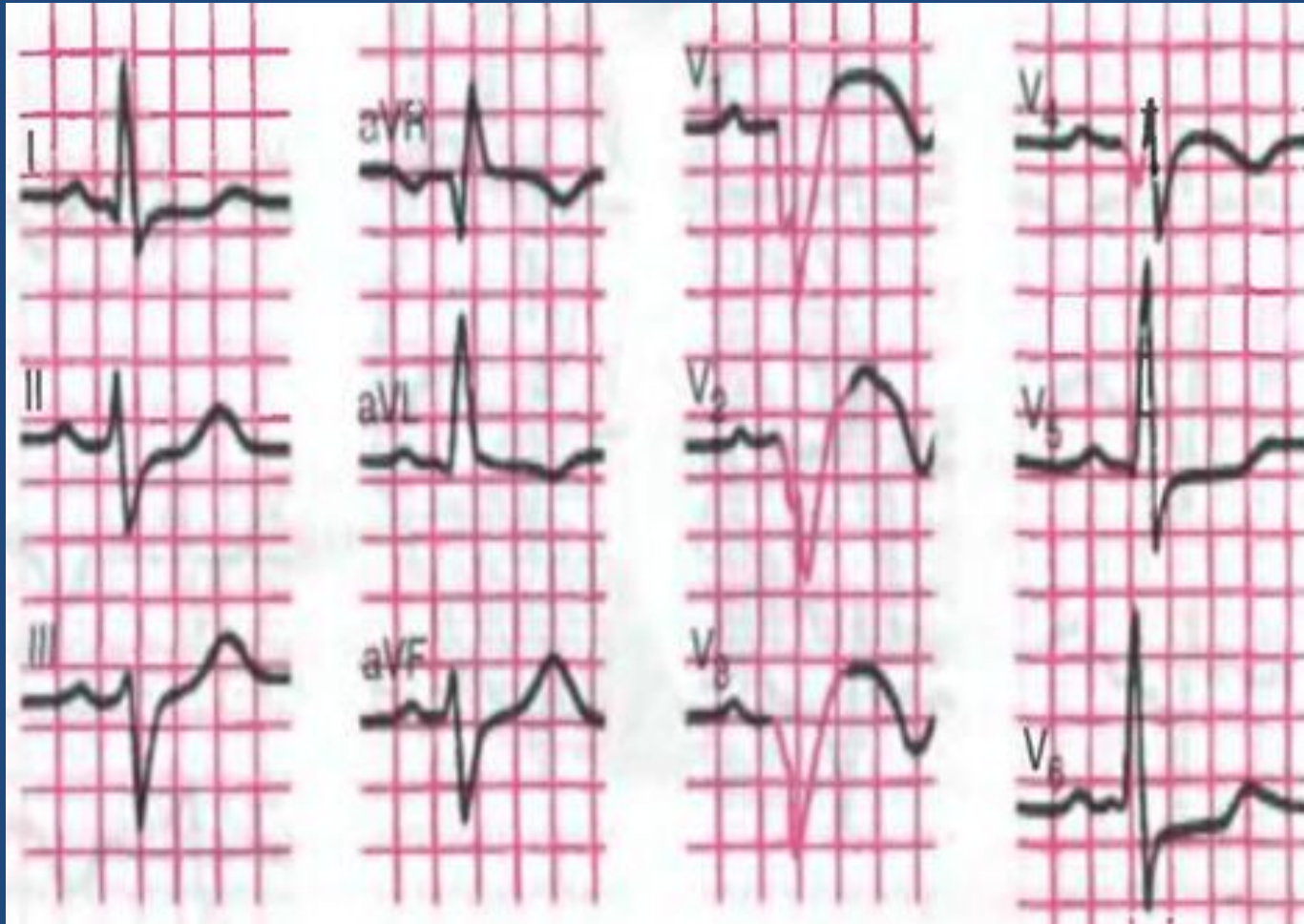
ECG criteria for the diagnosis of acute STEMI:

- ST segment elevation is measured in the **J-point** and the elevation must be significant in at least 2 contiguous ECG leads:
 - **Men age ≥ 40 years:** ≥ 2 mm in V2-V3 and ≥ 1 mm in all other leads.
 - **Men age < 40 years:** $\geq 2,5$ mm in V2-V3 and ≥ 1 mm in all other leads
 - **Women (any age):** $\geq 1,5$ mm in V2-V3 and ≥ 1 mm in all other leads.
 - **Men & women V4R and V3R:** $\geq 0,5$ mm, except from men < 30 years in whom the criteria is ≥ 1 mm.
 - **Men & women V7-V9:** $\geq 0,5$ mm.



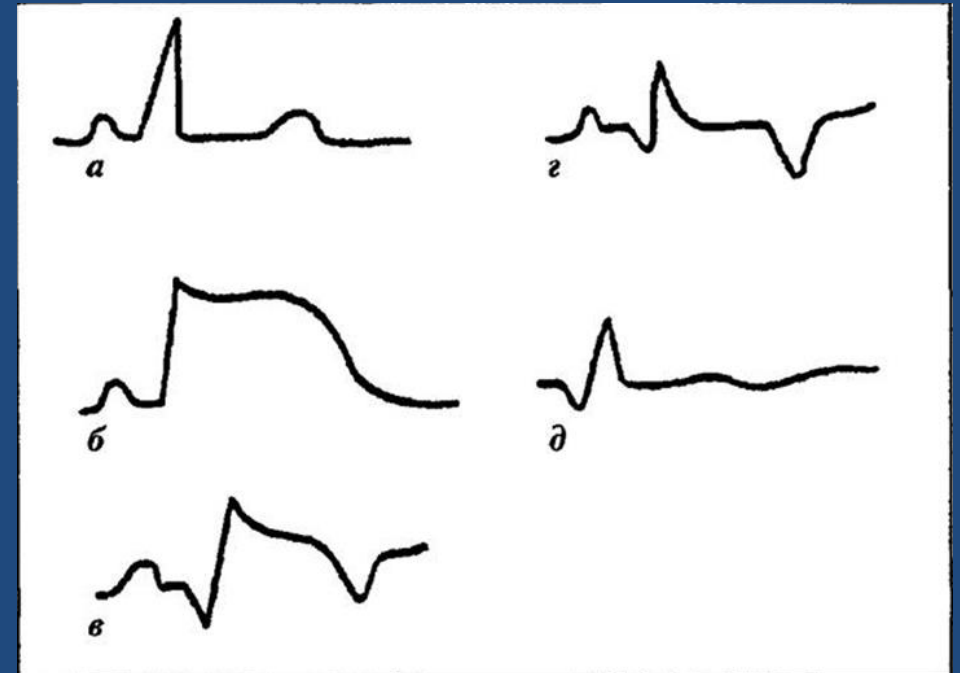
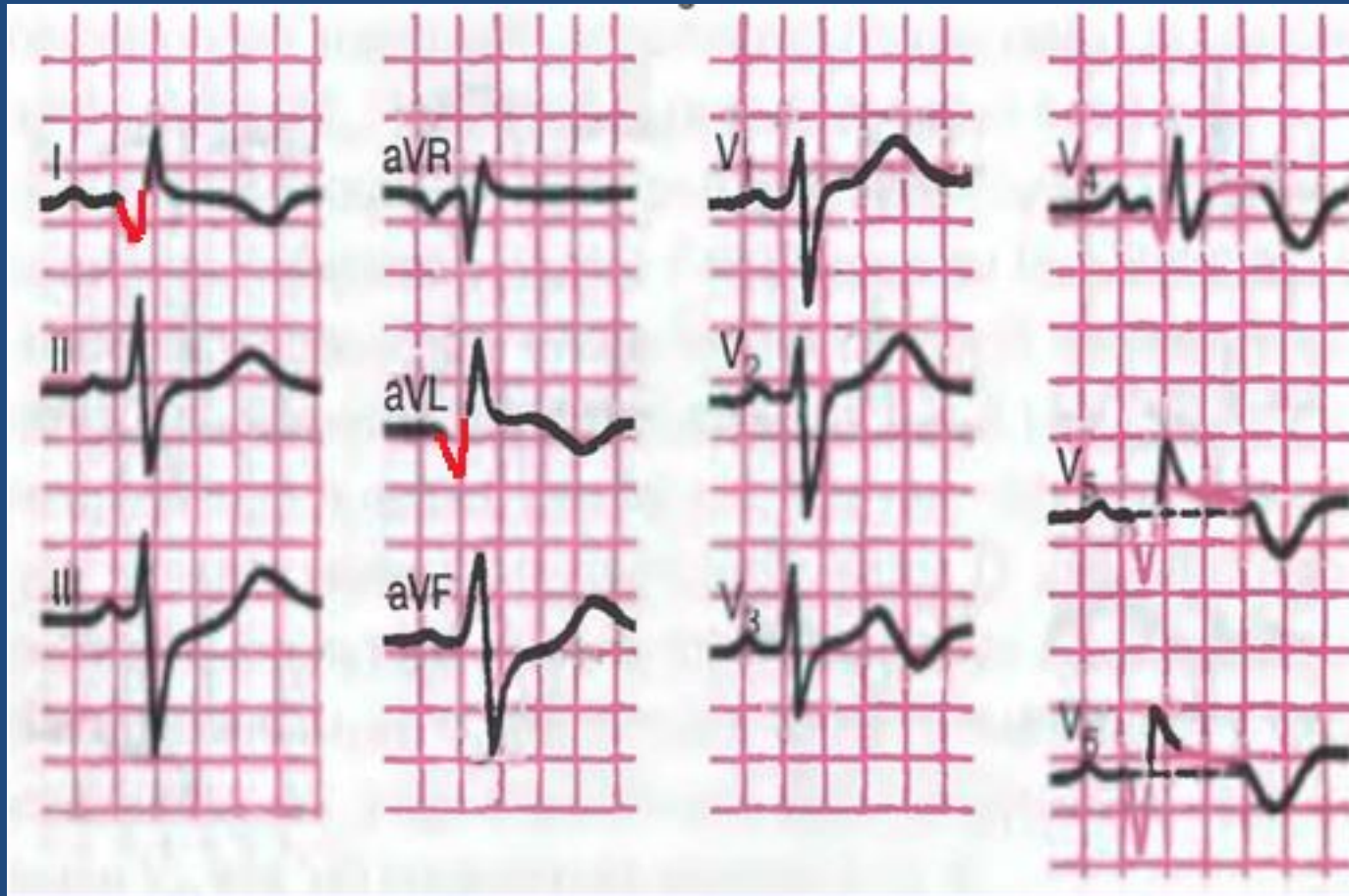
Q-WAVE MI ANTERO-SEPTAL AND APICAL

- Pathological Q wave V1-V4
- ST elevation V1-V4 - direct changes



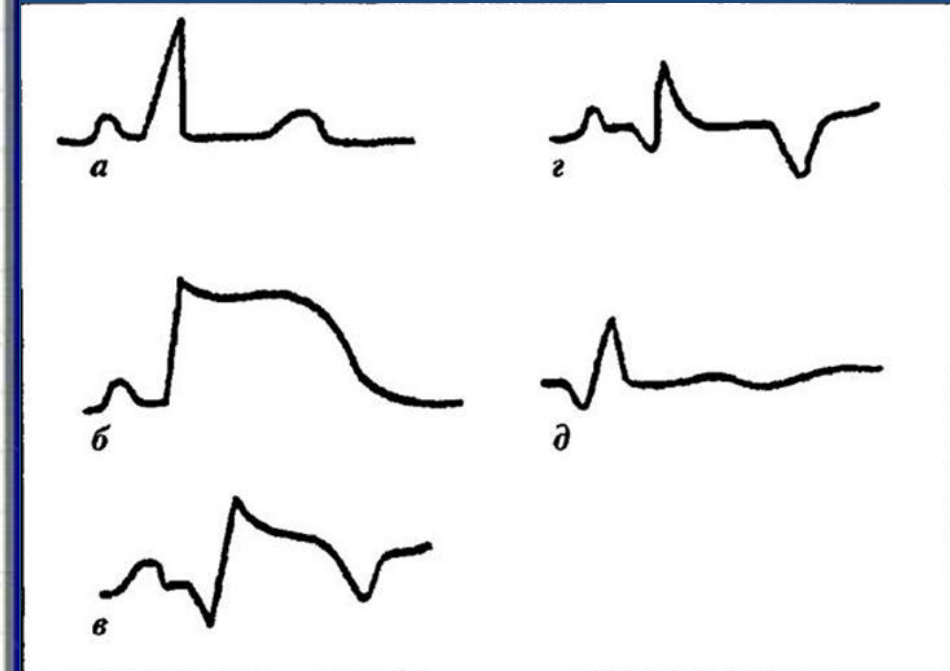
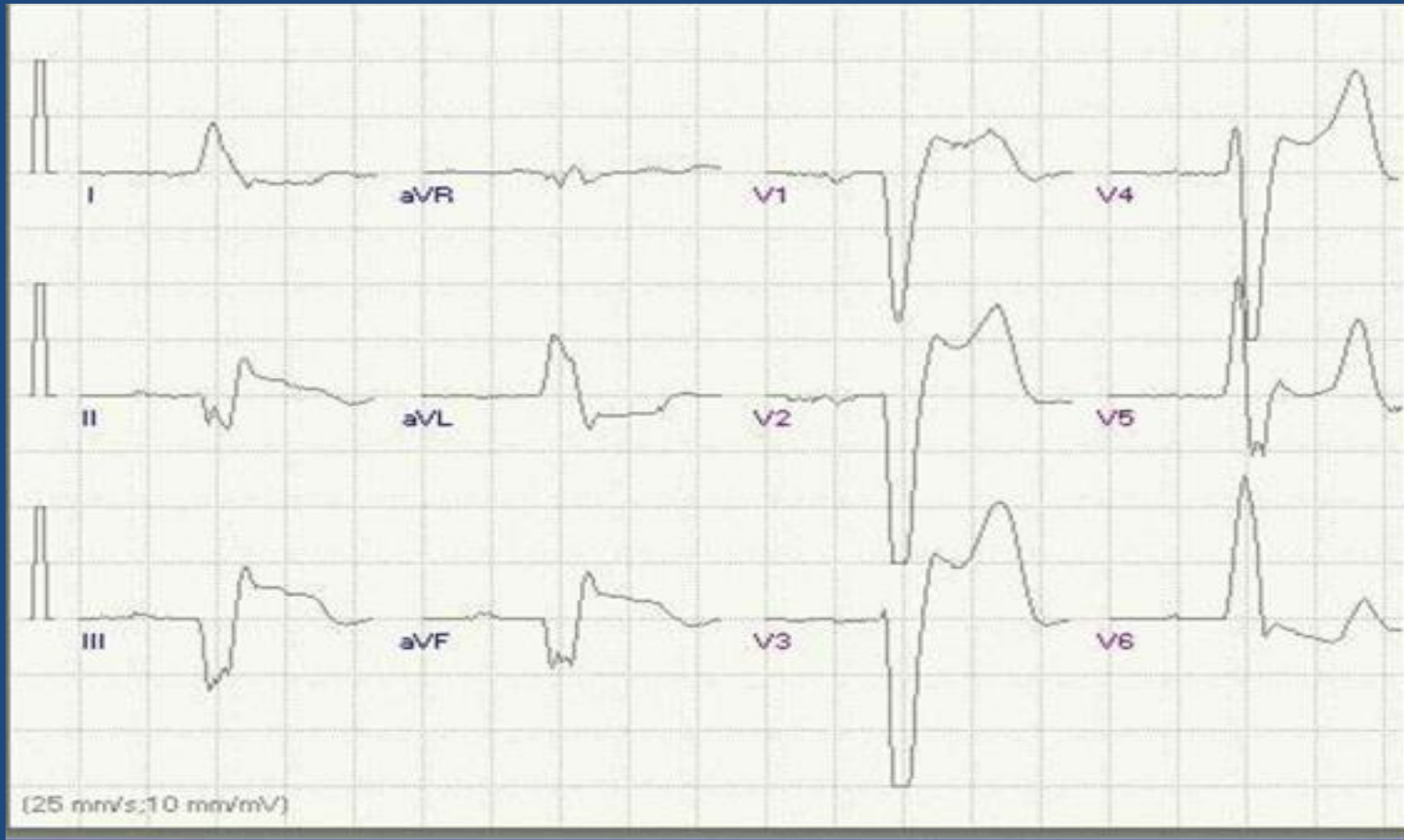
Q wave anterior lateral AMI

- Pathological Q in DI, aVL, V4-V6
- ST elevation DI, aVL, V4-V6 - direct changes



Q wave anterior(septal) AMI

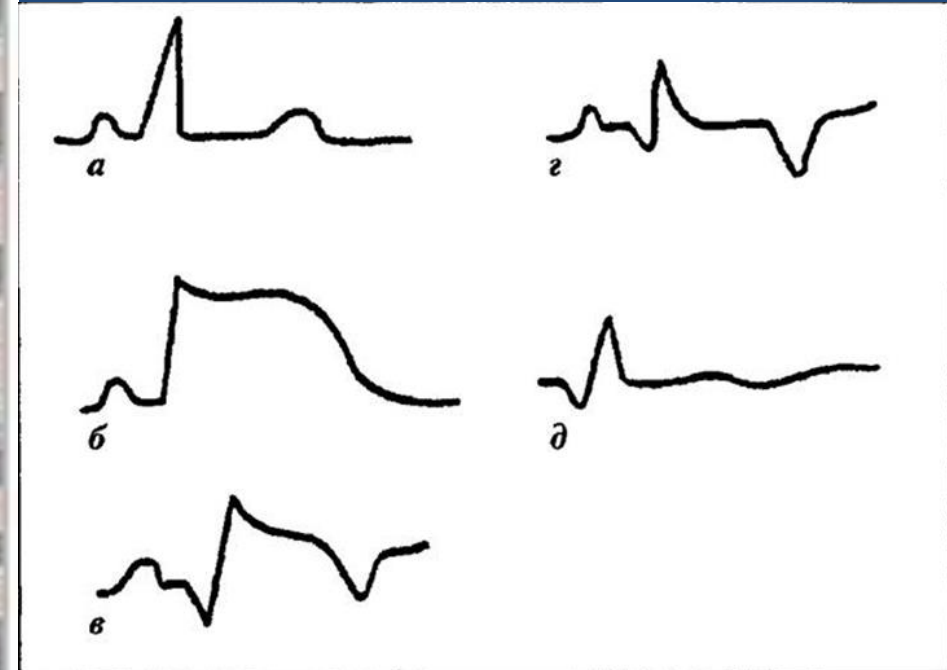
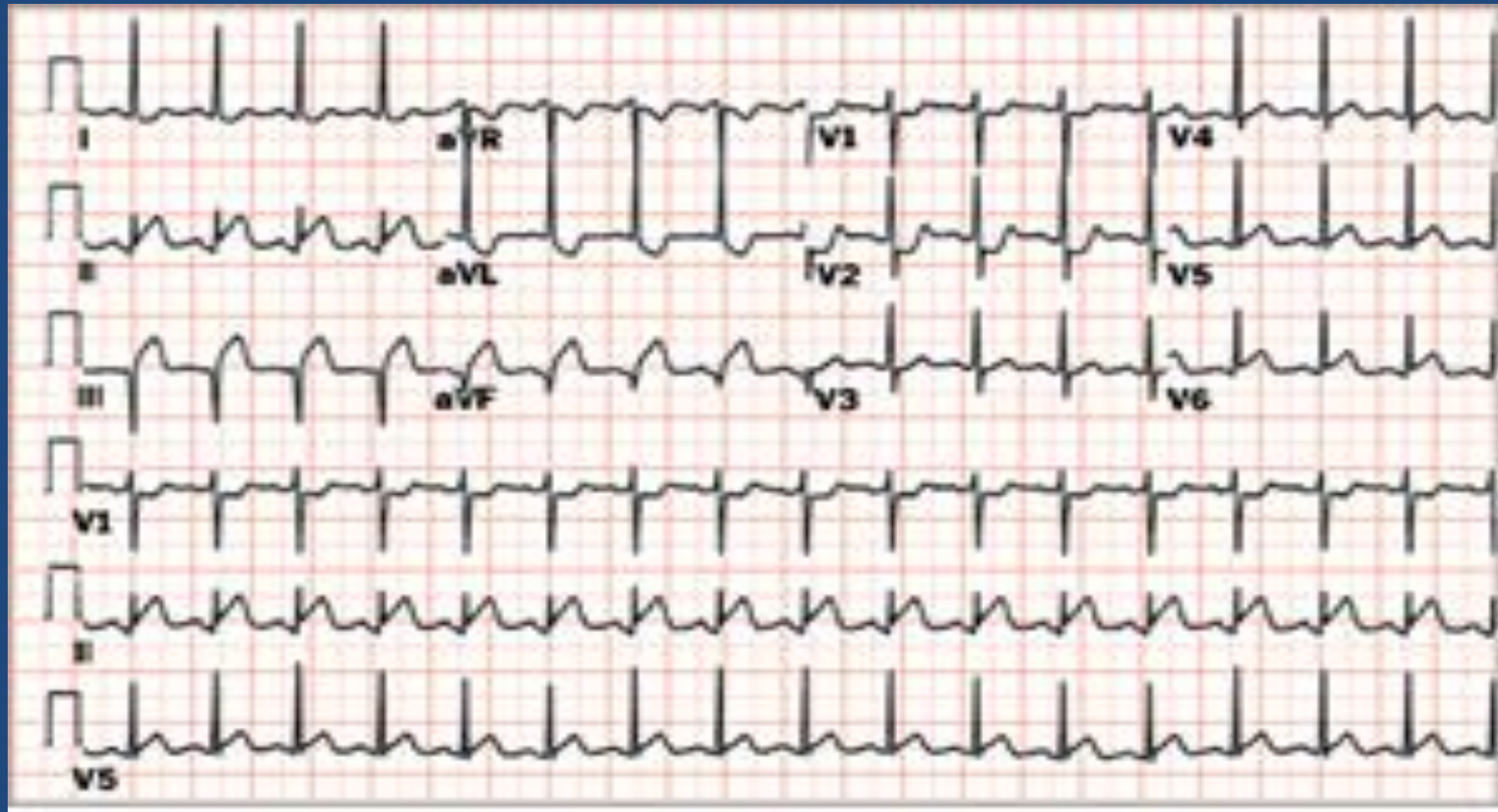
□ST elevation DII, DIII, aVF, V1-V4 - direct changes



Q WAVE INFERIOR AMI

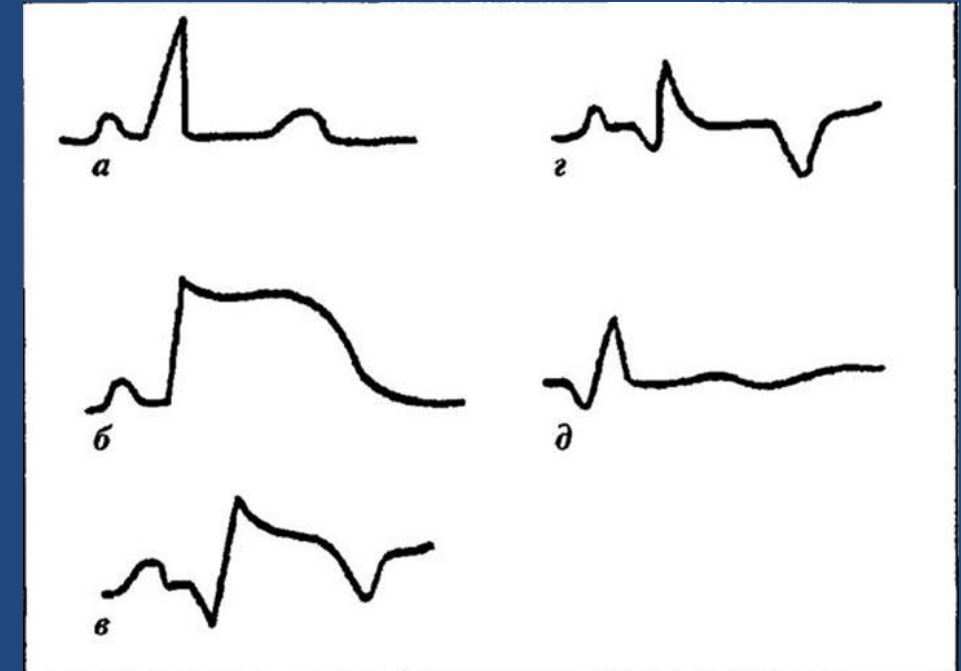
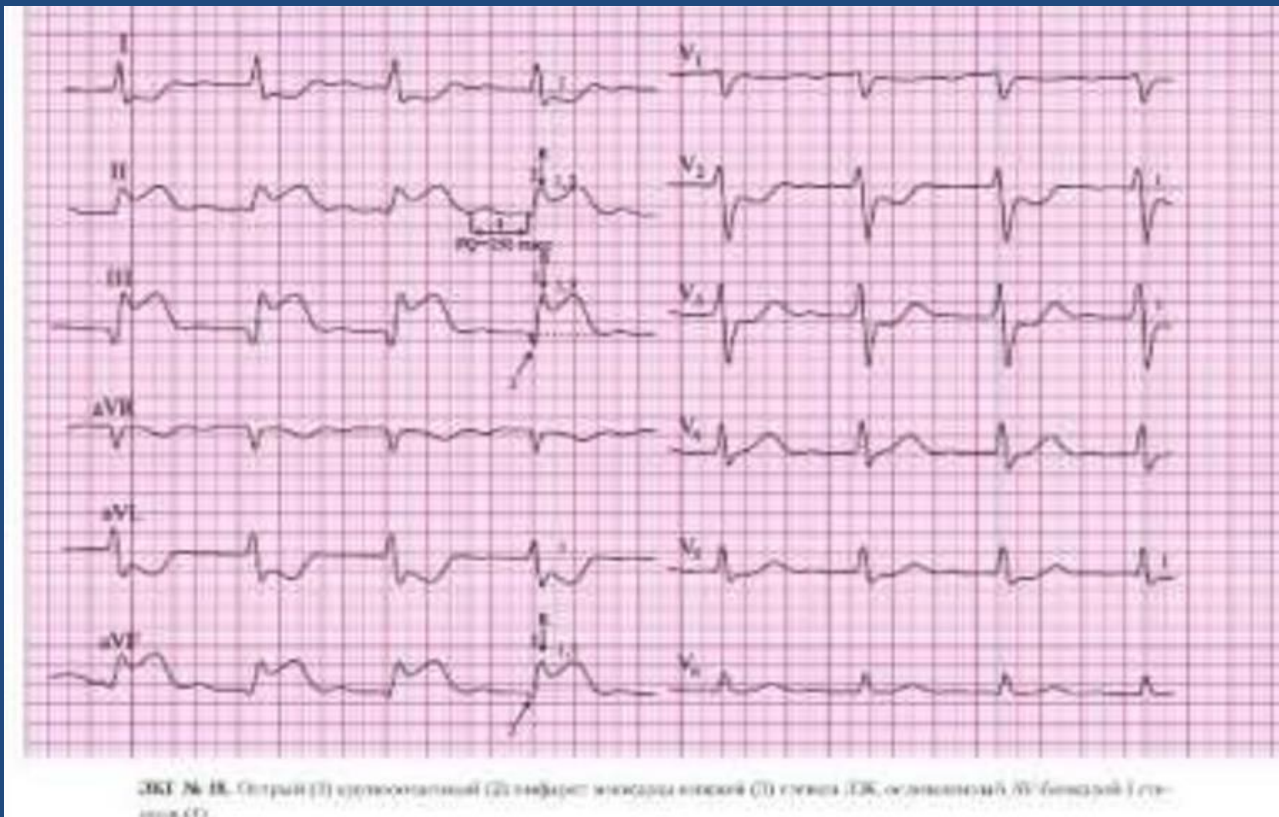
ST-segment depression DII, DIII, aVF -- direct changes

□ ST-segment depression V1, V2 - reciprocal changes "in the mirror"



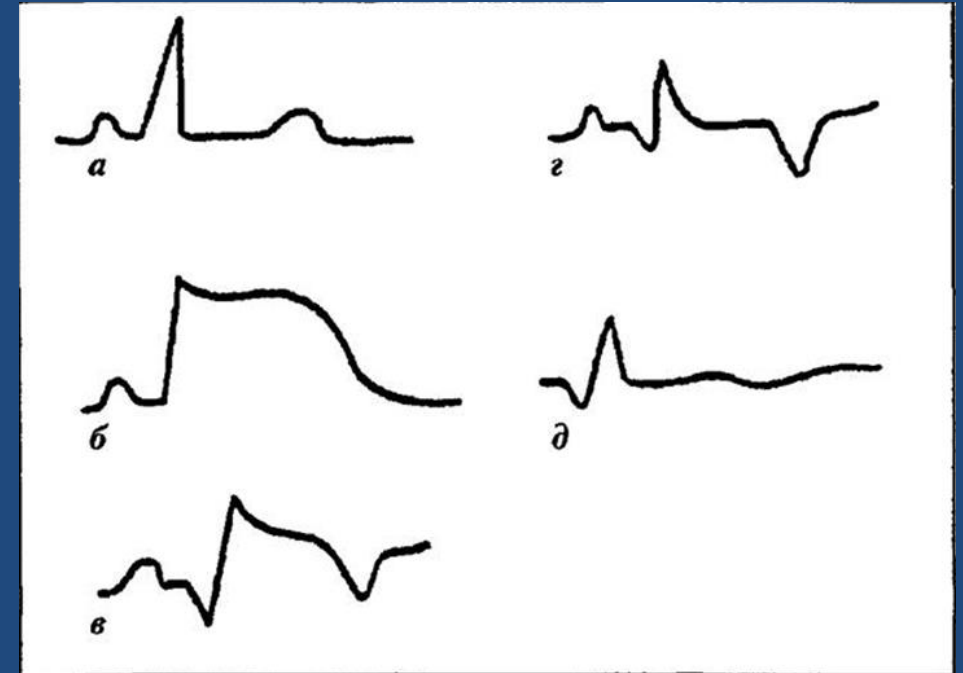
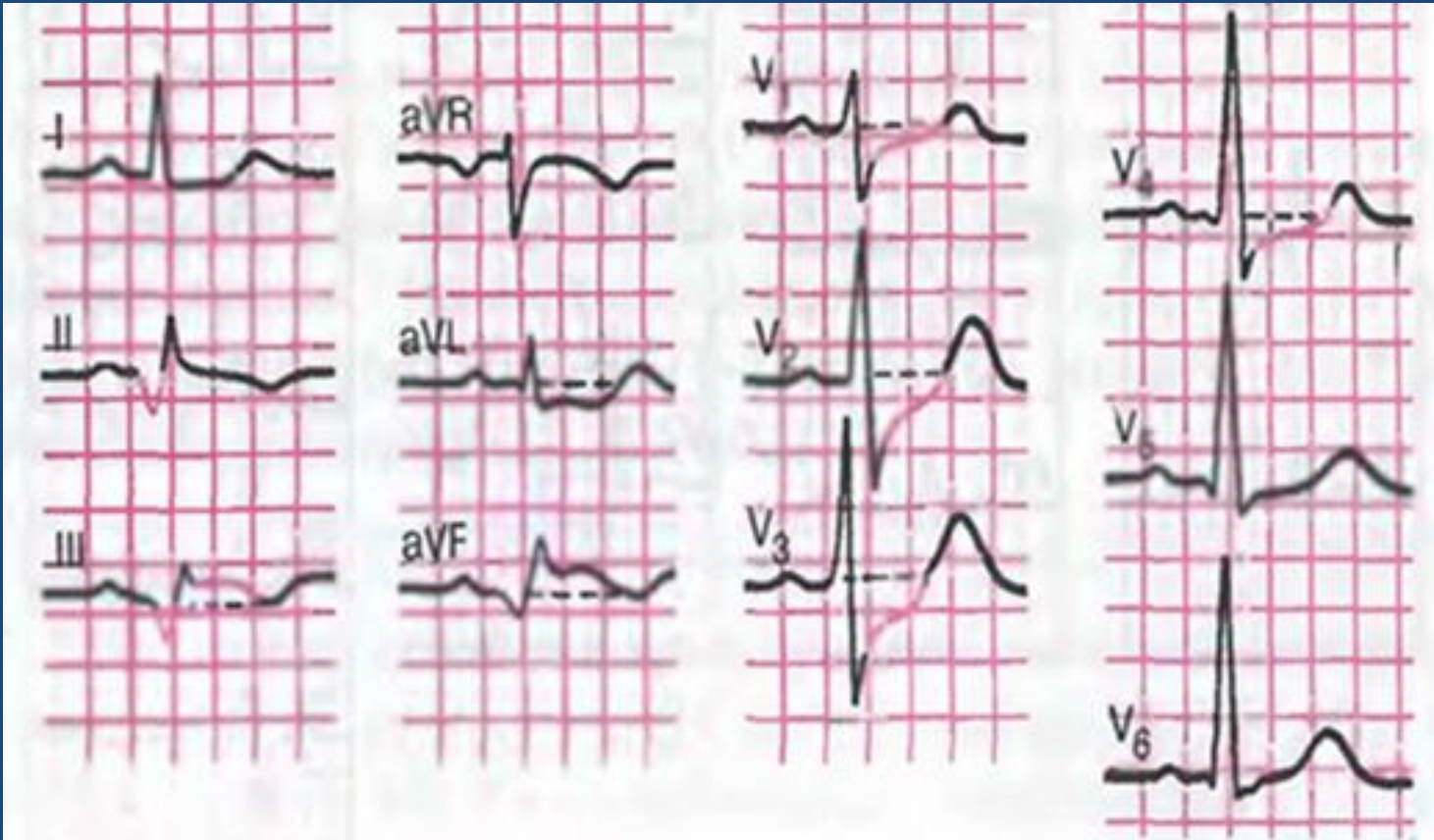
Q WAVE INFERIOR AMI (POSTERO-DIAFRAGMAL)

- ST-segment depression (DII), DIII, aVF -- direct changes
- ST- segment depression DI, aVL, V1-V4 - reciprocal changes "in the mirror"



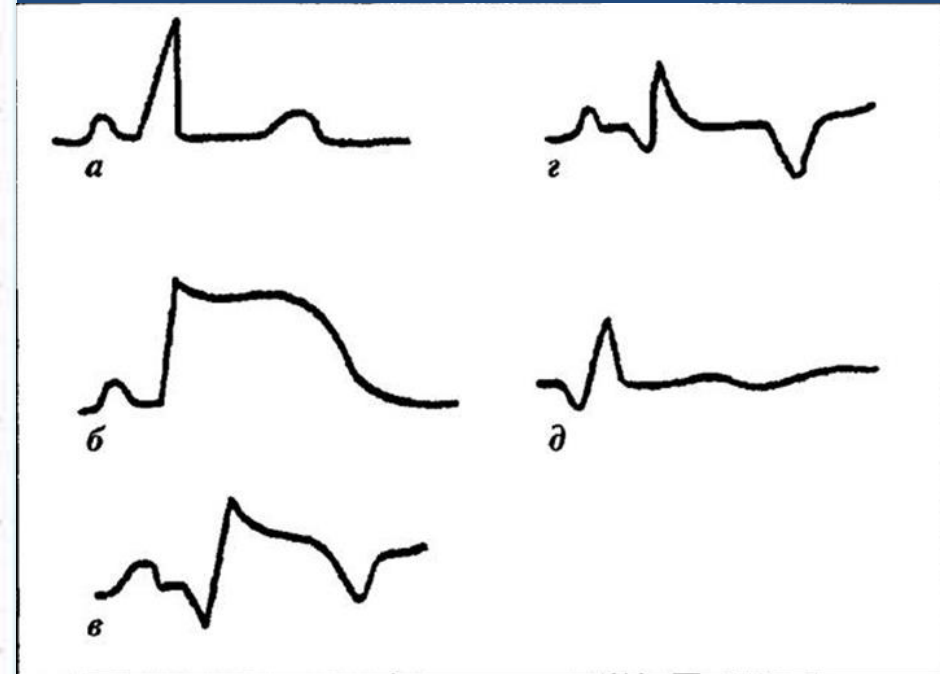
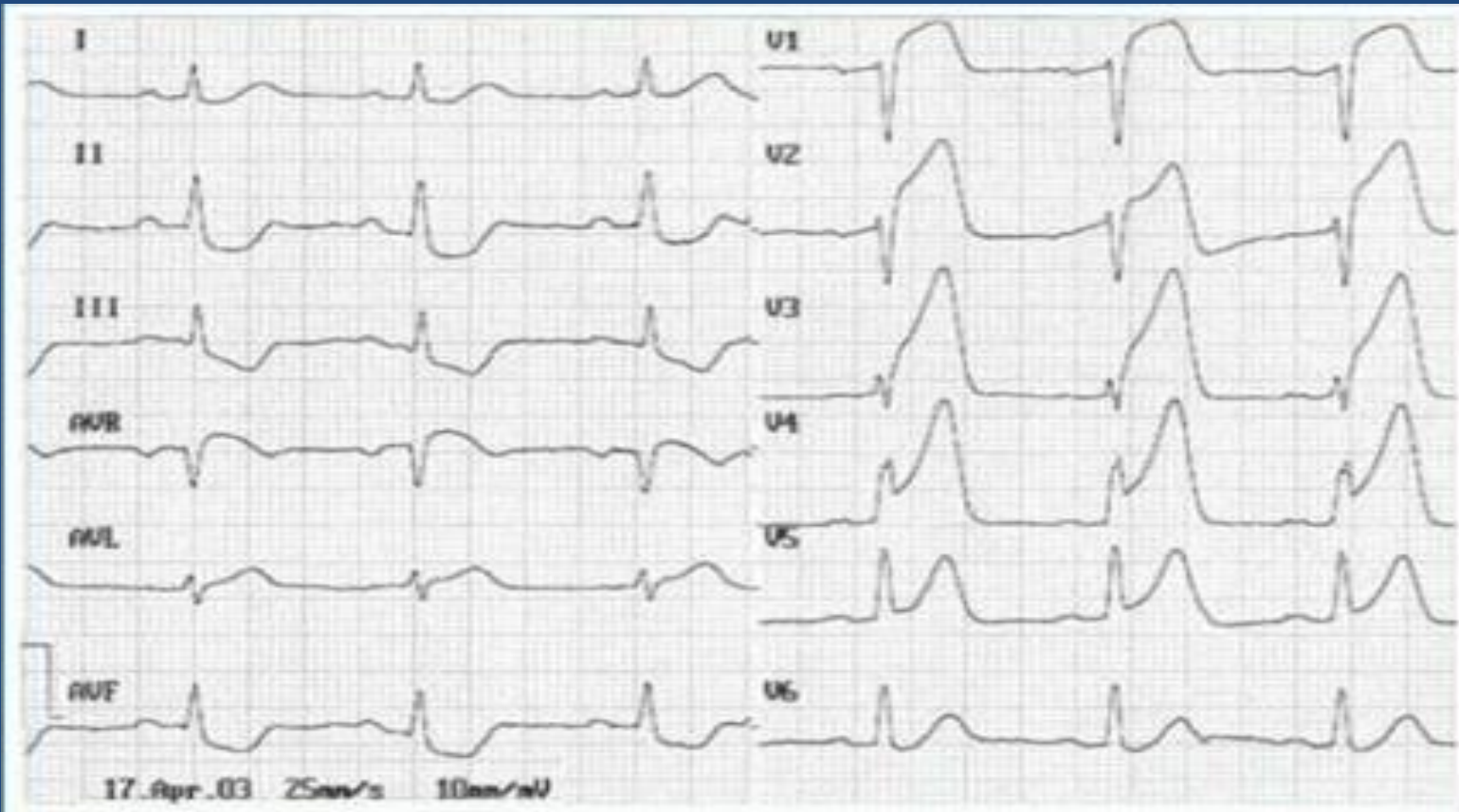
Q WAVE INFERIOR AMI (postero-diafragmal)

- Pathological Q wave in DII, DIII, aVF
- ST-segment depression (DII), DIII, aVF -- direct changes
- ST- segment depression DI, aVL, V1-V4 - reciprocal changes "in the mirror"



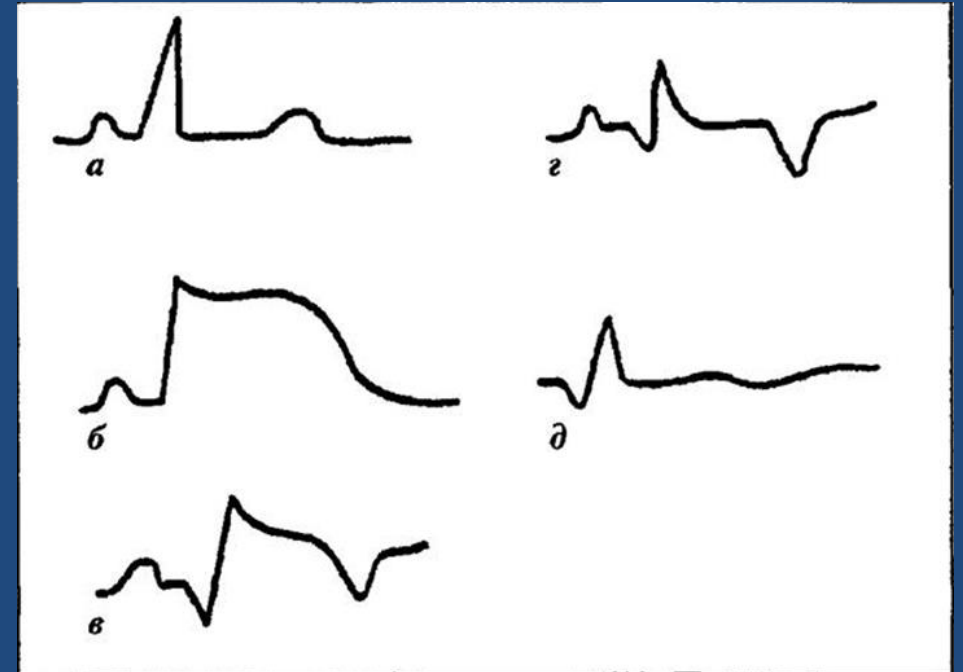
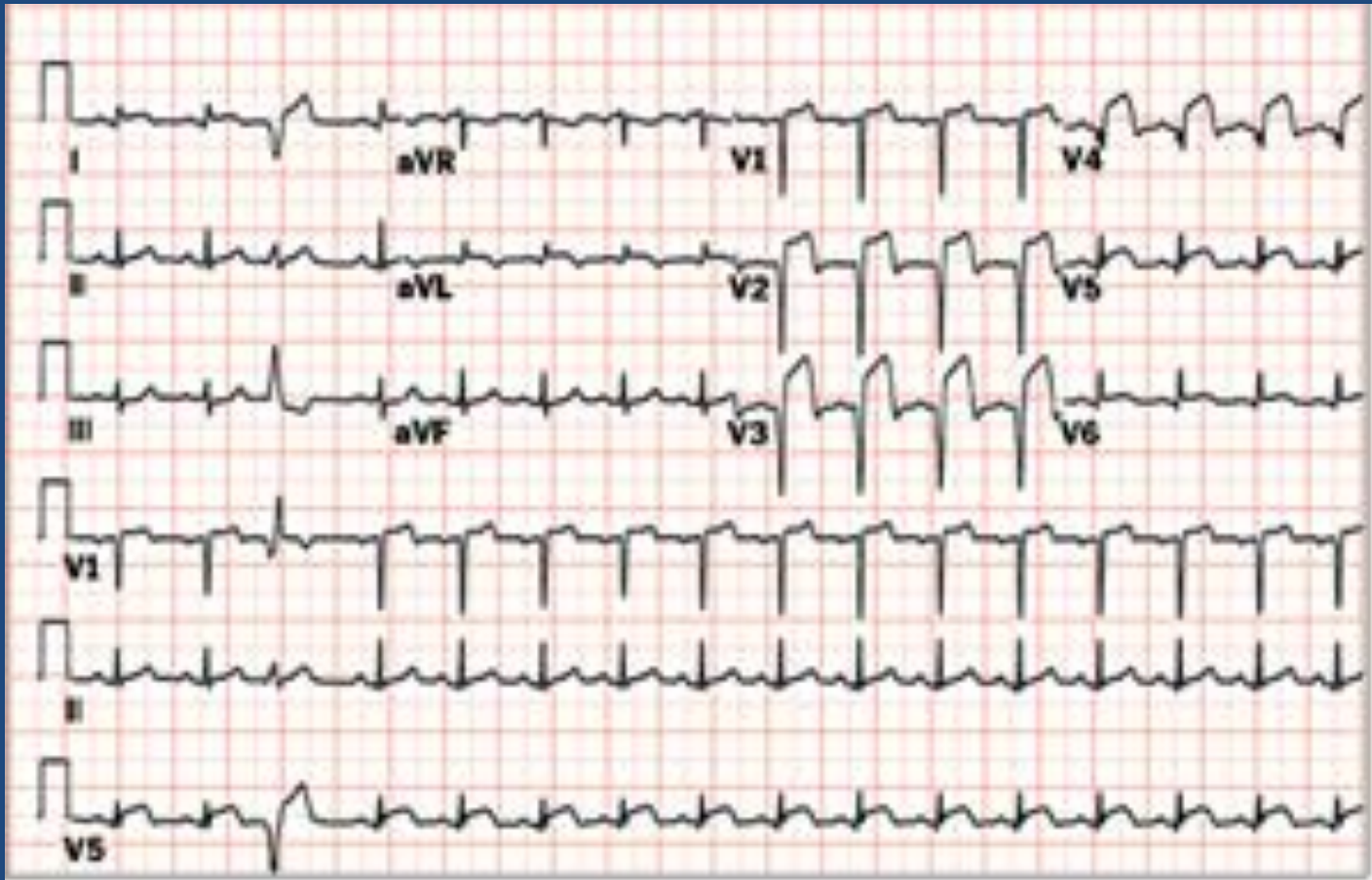Q WAVE ANTERIOR Extended AMI

- ST-segment elevation V1-V5 - direct changes
- ST-segment depression DII, DIII, aVF - reciprocal changes "in the mirror"



Q anterior AMI with Q wave

- ST-segment elevation V1-V4 - direct changes
- ST- segment depression DII, DIII, aVF - reciprocal changes "in the mirror"



AMI DIAGNOSIS

It is sure in the presence of 3 and probably in the presence of 2 of the following 3 criteria:

1. Clinic: typical chest pain lasting ≥ 20 min
2. ECG: evolutionary changes in at least 2 adjacent leads (ST elevation ≥ 2 mm in precordial leads or ≥ 1 mm in peripheral leads)
3. Biologic: increase in serum enzymes to $\geq 2x$ normal values

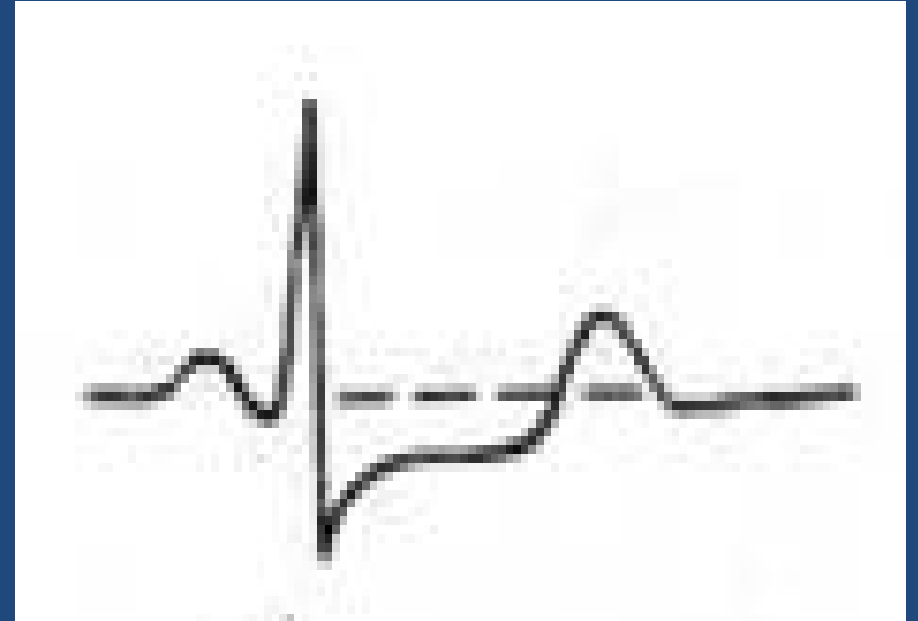
ECG changes in chronic ischemic heart disease

- ▣ In the chronic IC at the ECG there are characteristic changes from the **seg. ST and T wave**
- ▣ Coronary insufficiency and myocardial blood irrigation disorder usually cause elevation and change in the shape of the segm.ST

Variants of displacement of the ST segment in chronic IC

Subdenivelare orizontală (≥ 1 mm):

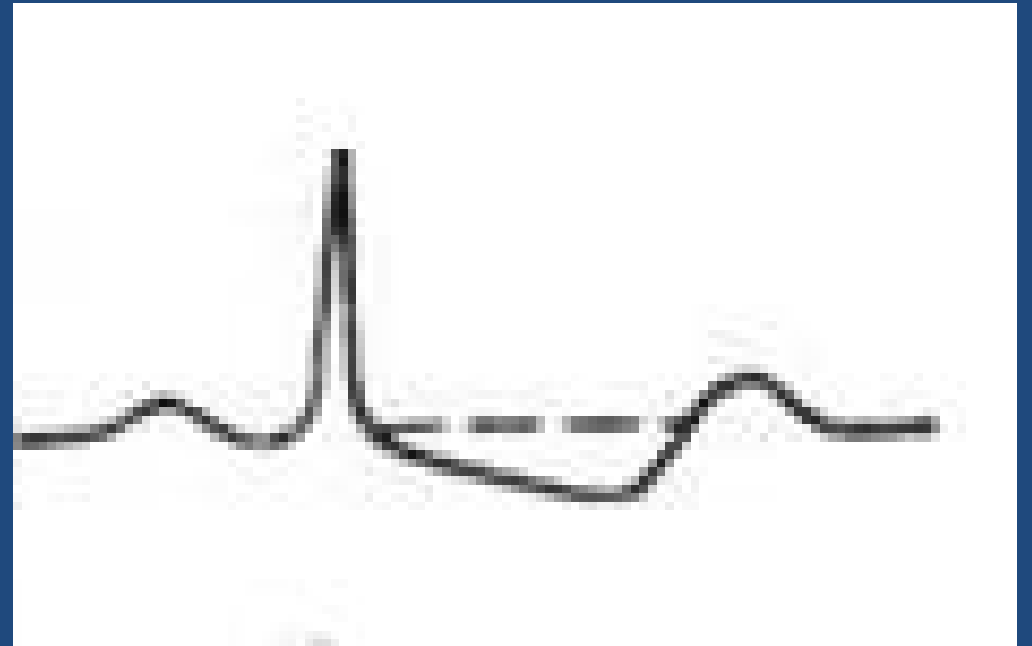
- ▣ Seg.ST passes into the positive, biphasic, flattened or negative T wave



Variants of displacement of the ST segment in chronic IC

Subdenivelare oblic descendentă (≥ 1 mm):

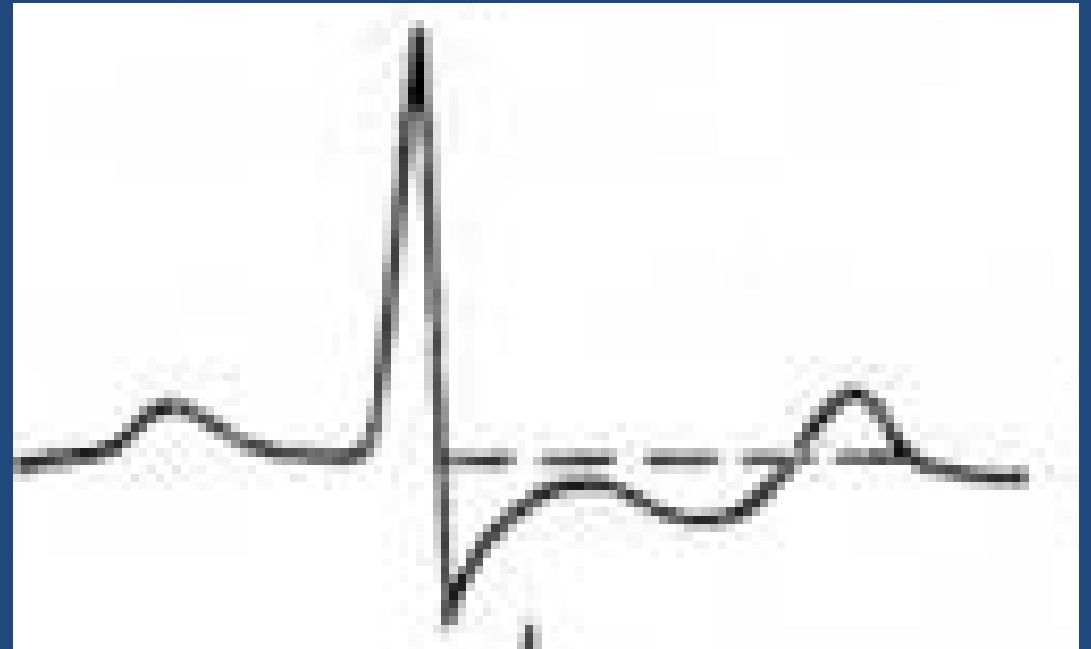- ▣ Seg.ST passes into the positive, biphasic, flattened or negative T wave



Variants of displacement of the ST segment in chronic IC

Depression in the form of a convex curve (≥ 1 mm):

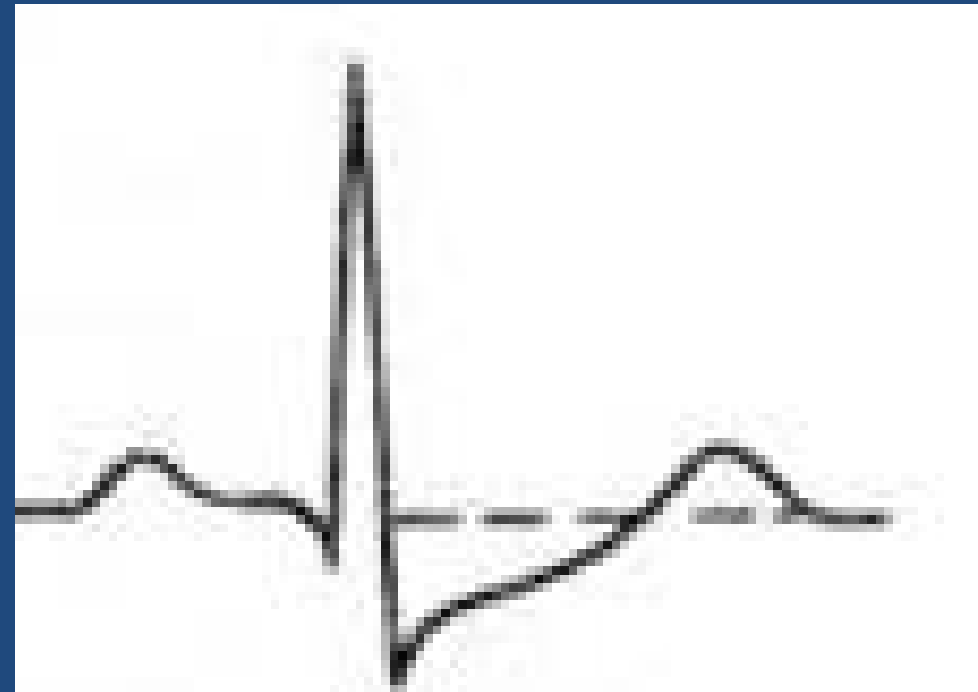
- ▣ Seg.ST passes into the biphasic positive, flattened or negative T wave



Variants of displacement of the ST segment in chronic IC

Angular upward elevation of the segment (≥ 1 mm):

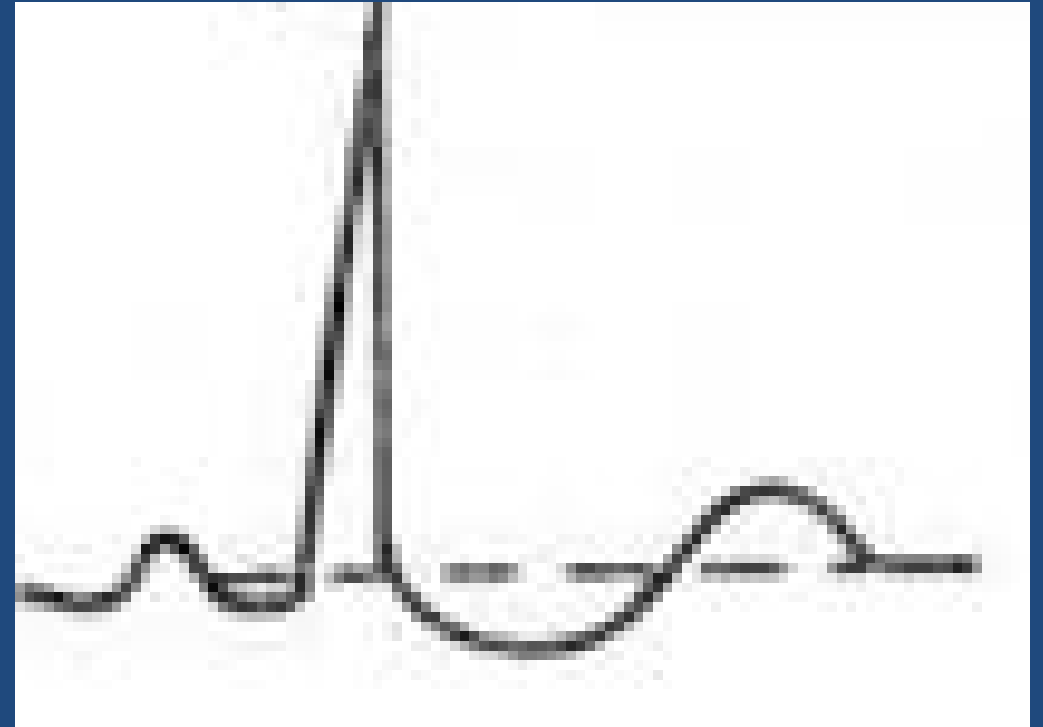- ▣ Seg.ST usually passes into the positive or flattened T wave



Variants of displacement of the ST segment in chronic IC

The curved concave depression (≥ 1 mm):

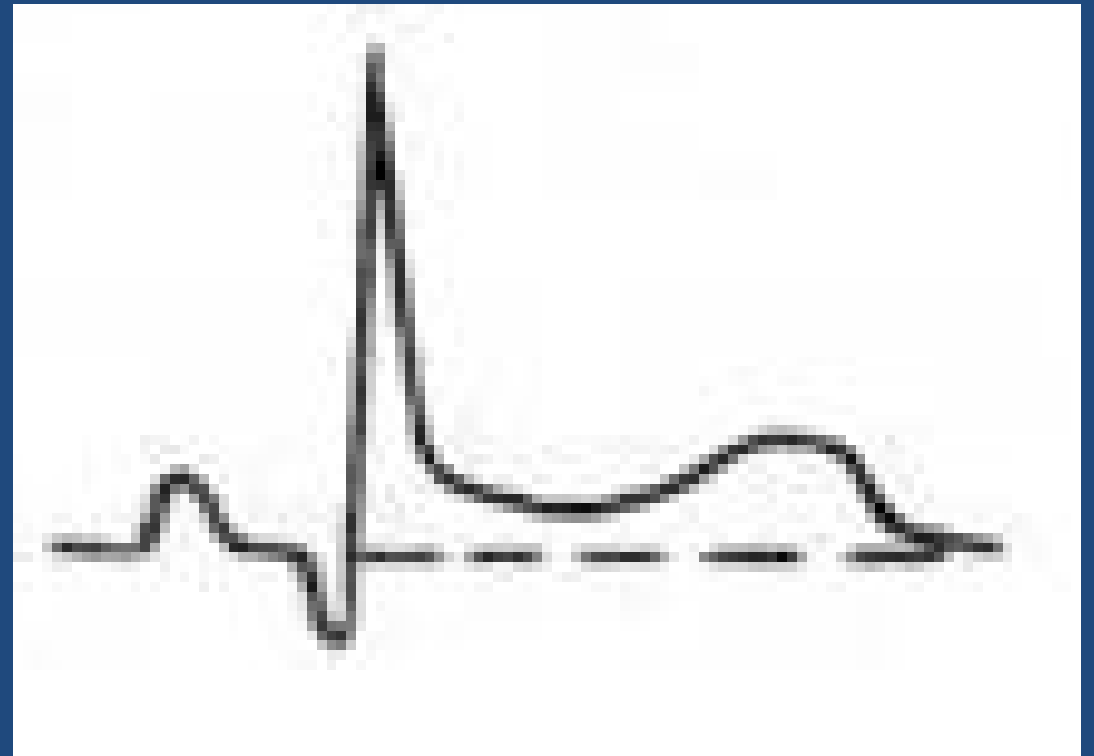- ▣ Seg.ST usually passes into the positive or flattened T wave



Variants of displacement of the ST segment in chronic IC

Elevation of ST segm. (≥ 1 mm):

- ▣ Segm.ST has the shape of a concave curve
- ▣ Segm.ST usually passes into the positive or flattened T wave



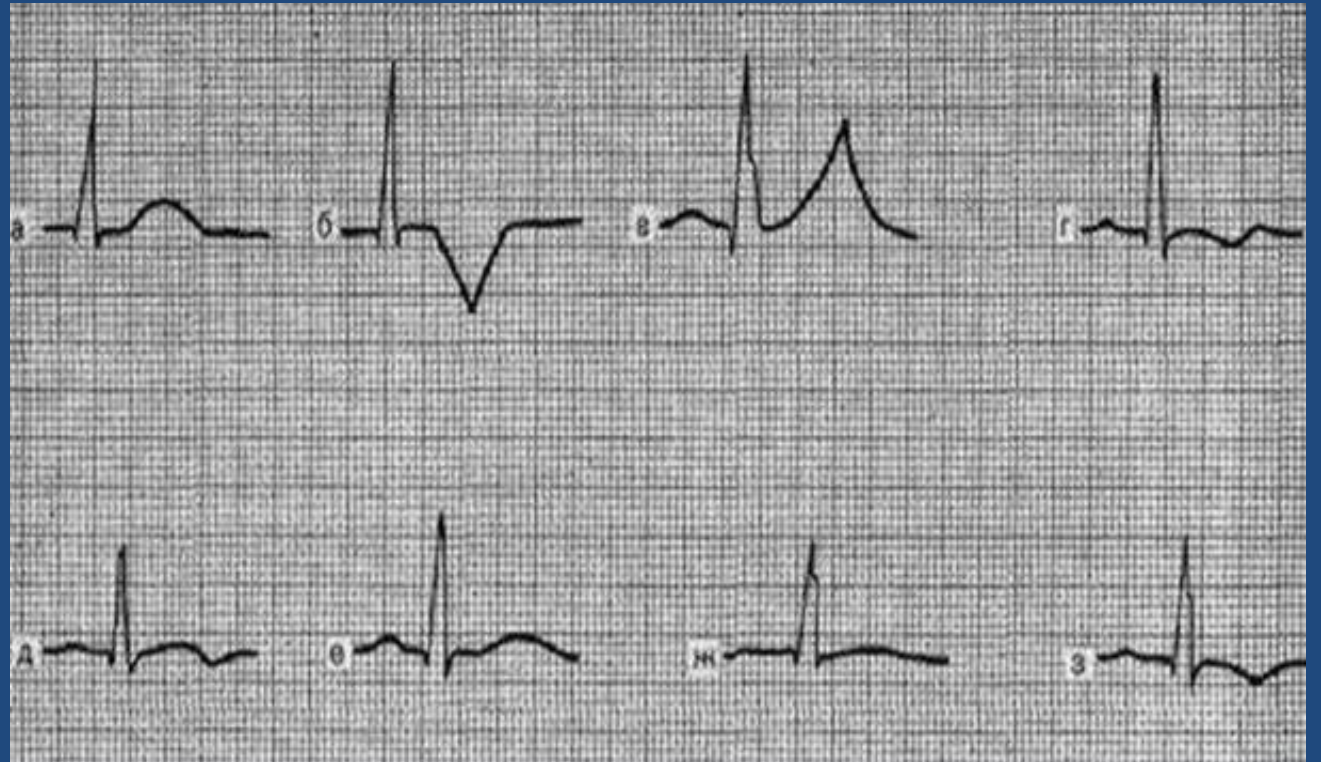
Variants of displacement of the ST segment in chronic IC

For chronic IC the most specific displacements of segm ST are:

- ▣ **Horizontal depression**
- ▣ **Obliquely downward depression**

T-wave changes in chronic IC

- ▣ They can be various: flattened, biphasic, negative
- ▣ The most specific are T (-), symmetrical, sharp-shaped waves with an amplitude > 5 mm ("coronary T") - transmural ischemia
- ▣ T waves can be (+), symmetrical, sharp in large amplitude ("coronary T") - subendocardial ischemia



EKG CHANGES IN ANGINA PECTORIS

In classical angina pectoris, the ECG signs are mainly related to changes in the ST segment and the T wave:

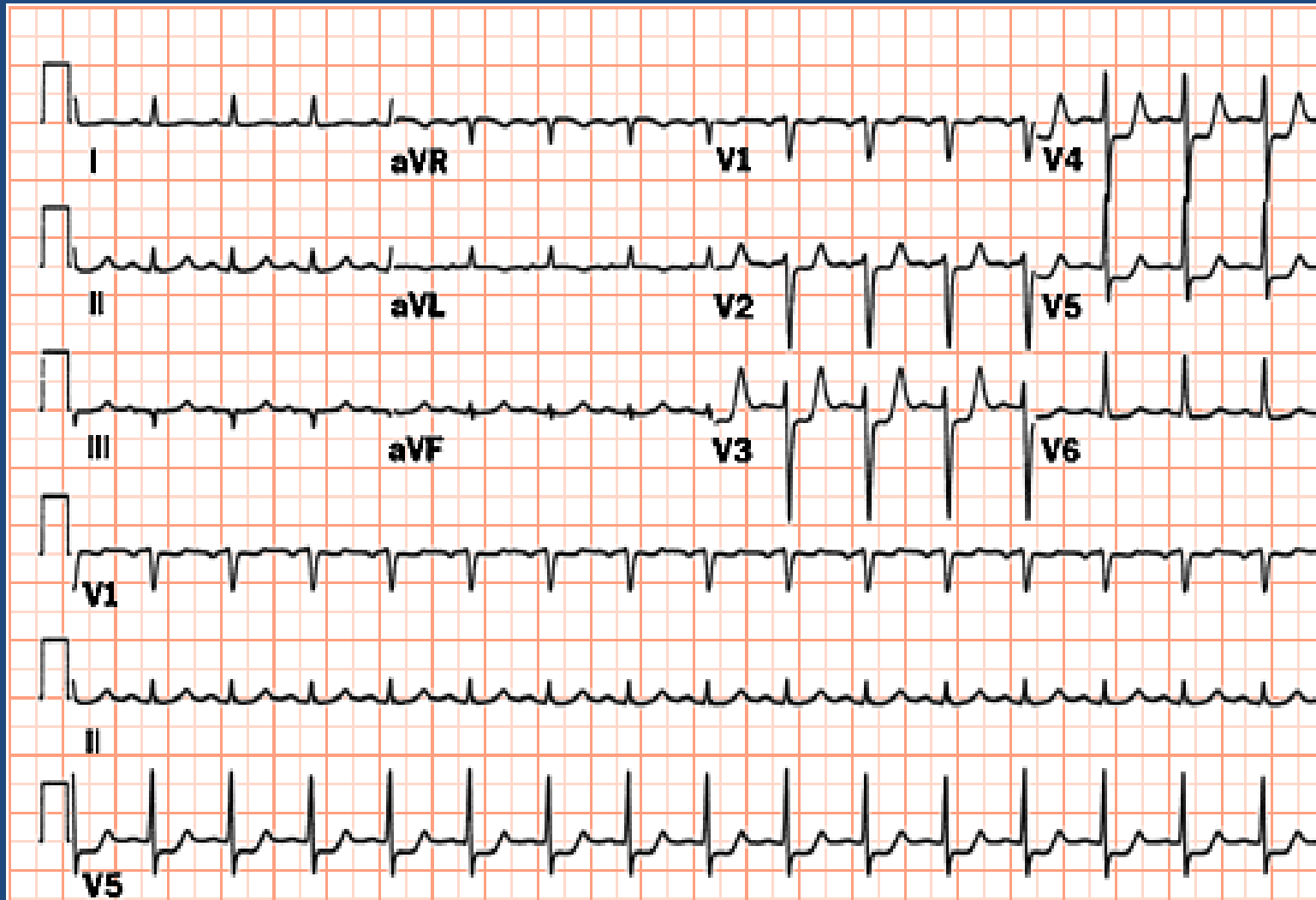
BETWEEN CRISES:

- Normal appearance in over 1/3 of cases
- ST sublevels (subendocardial lesions)
- Negative T-wave (subepicardial ischemia)
- High T wave (subendocardial ischemia)
- QT elongation

DURING CRISES:

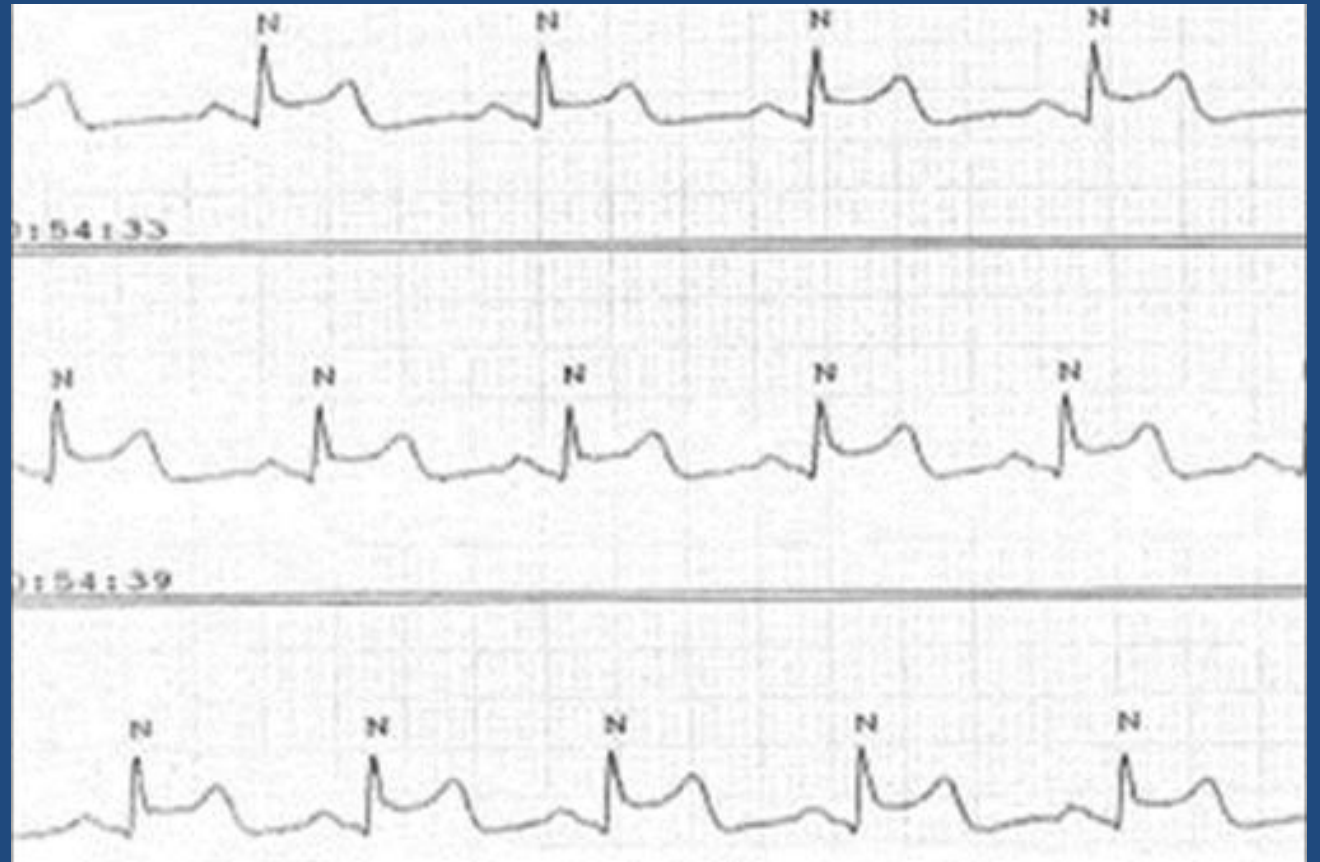- ▣ Normal appearance in 1/3 of cases
- ▣ Sublevels ST
- ▣ Negative or flattened T wave
- ▣ Intraventricular blocks

ECG during acces of angina pectoris

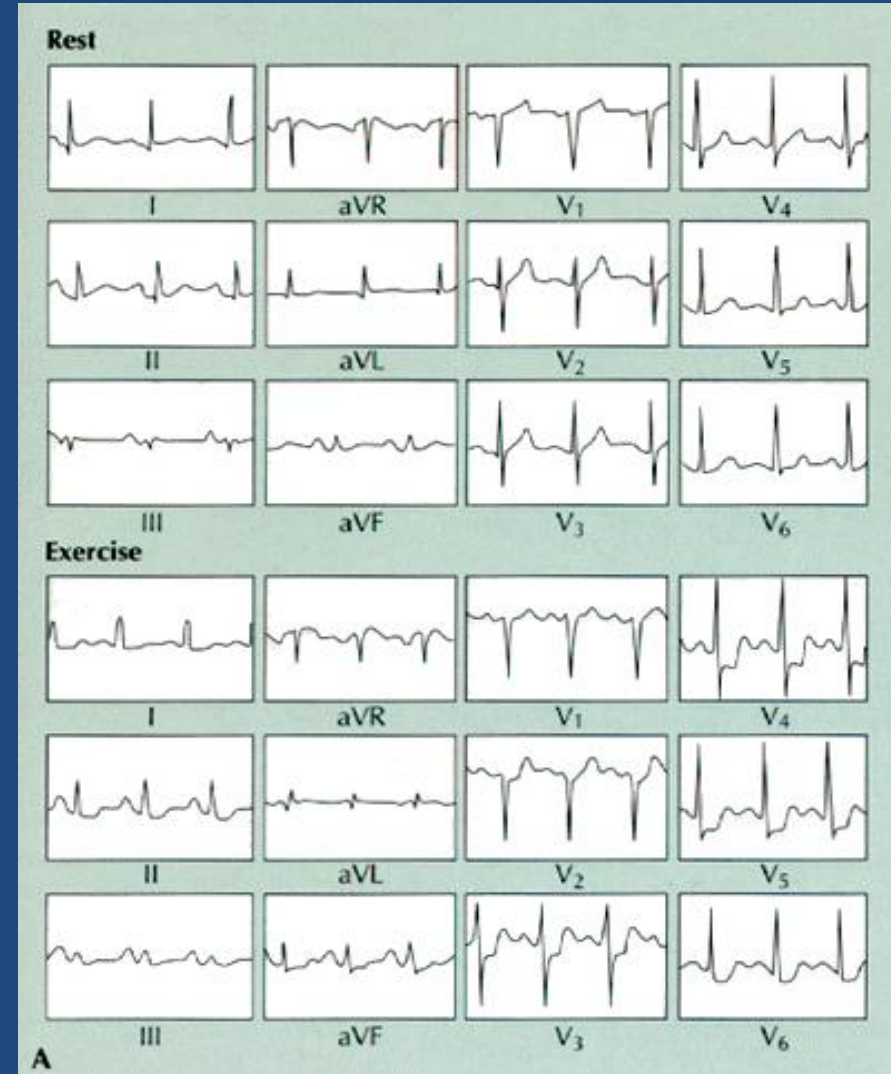
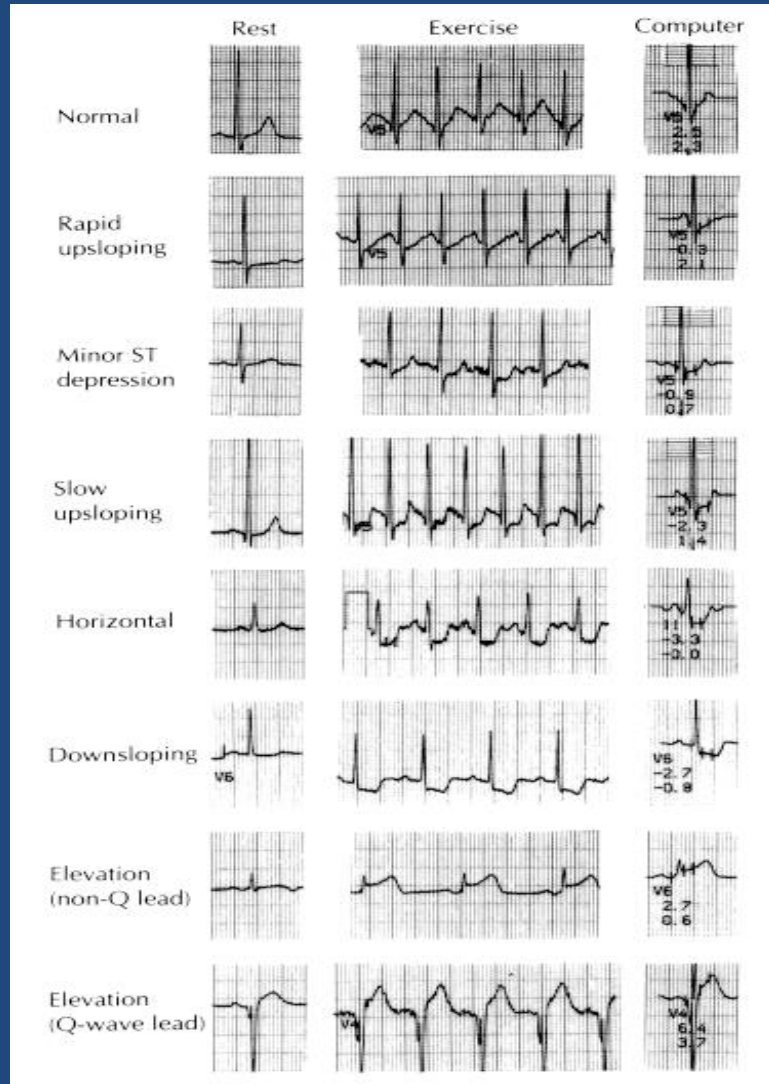


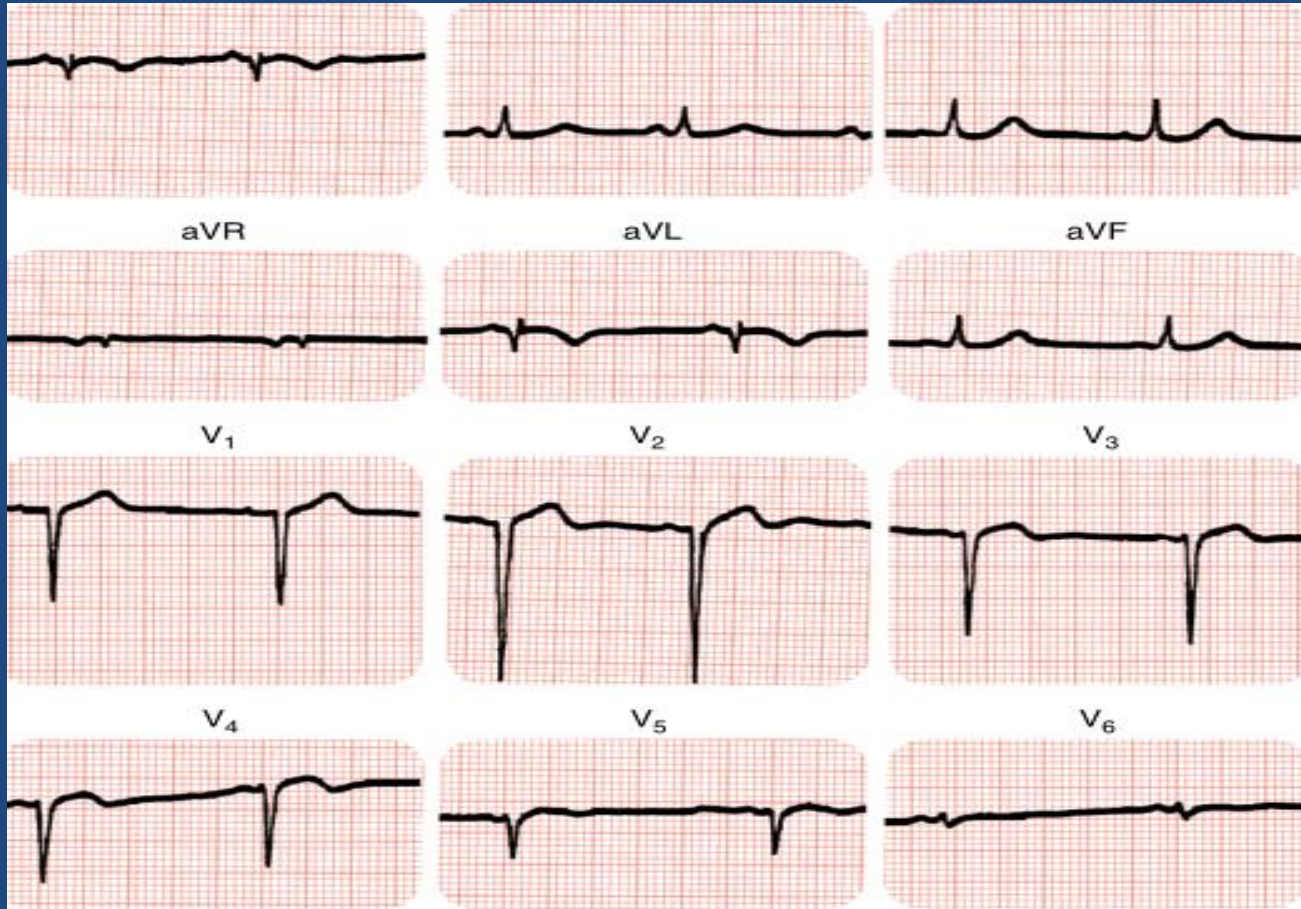
ECG in angina Prinzmetal (vasospastic)

- Signs characteristic of the acute or subacute stage of AMI are recorded: horizontal elevation of the ST segment, which lasts a few seconds or minutes
- Rapid ECG returns to normal as opposed to IMA, in which ST elevation persists longer



ECG during the exercise test (cycloergometry) in a patient with angina pectoris



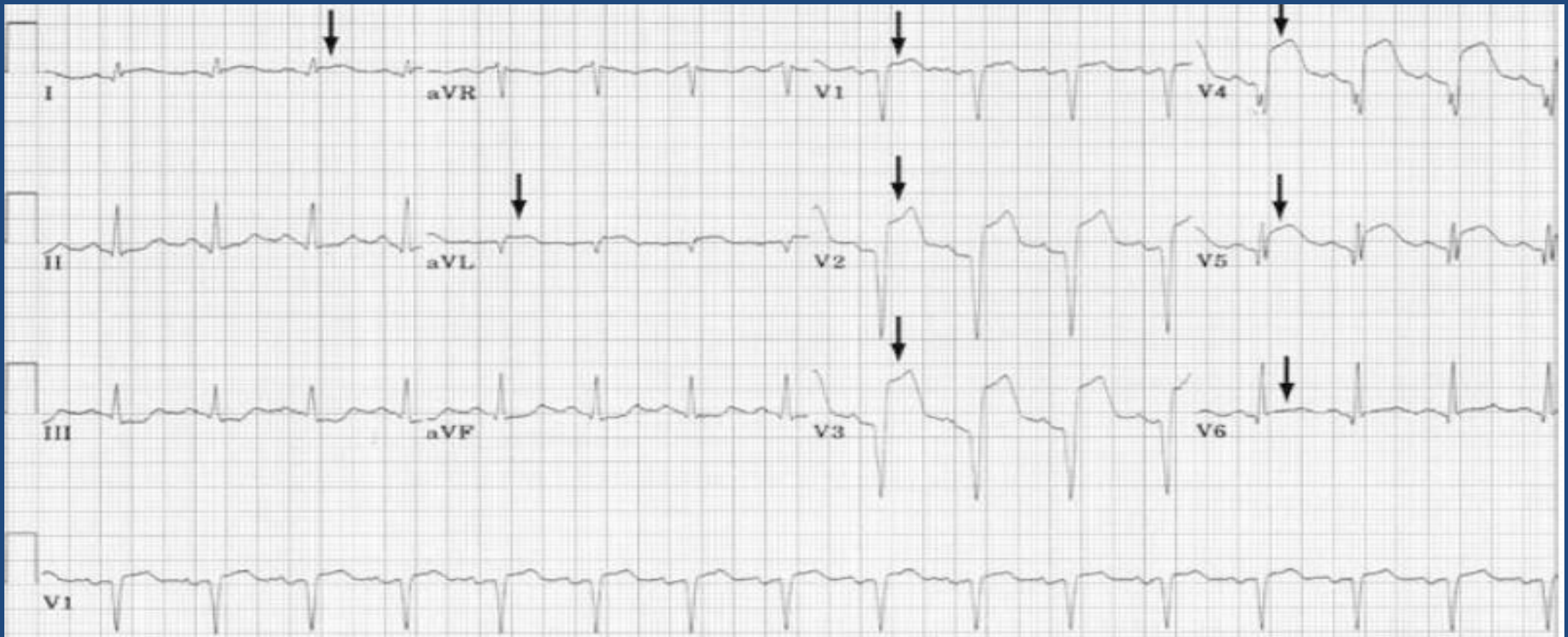

Evolving extensive anterolateral wall infarction. Notice the poor R wave progression in leads V1 to V5 with Q waves in leads I and aVL.

The T waves are slightly inverted in these leads. In this ECG, right axis deviation is the result of loss of lateral wall forces, with Q waves seen in leads I and aVL.

Anterior myocardial infarction involving the proximal left anterior descending artery. Although the ST segment elevation is most prominent in V1–V6, ST segment elevation is observed in all of the anterior leads and I and aVL.

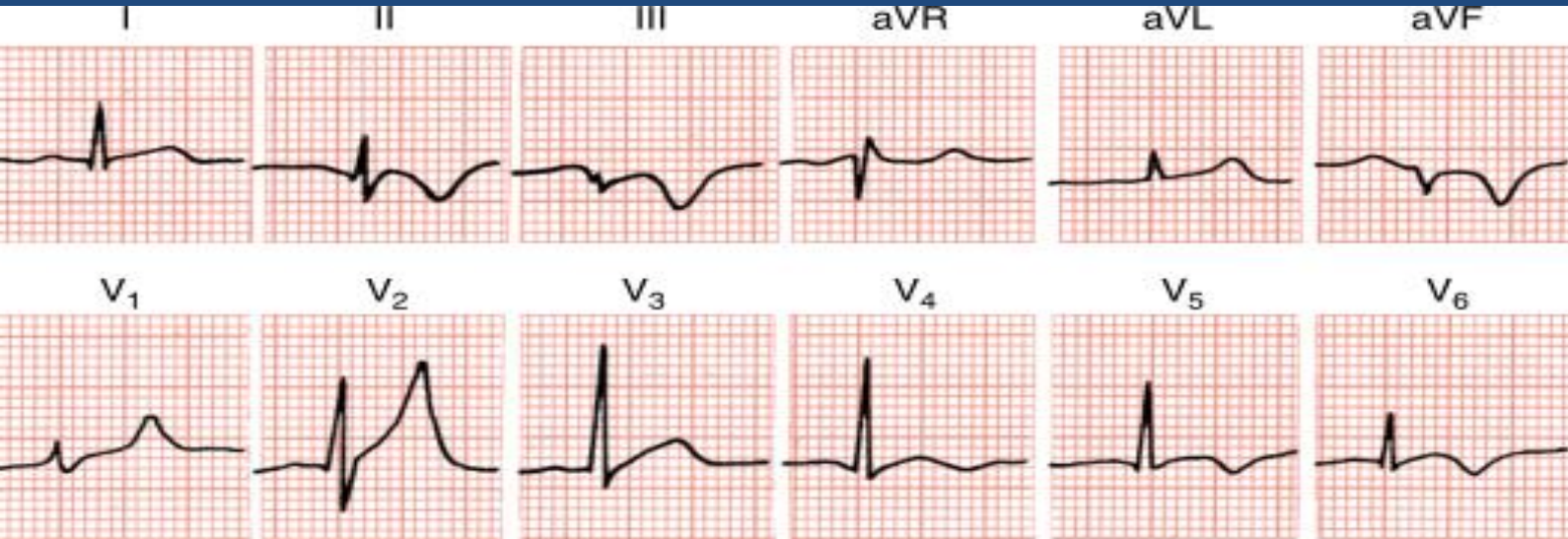
Notice the reciprocal ST segment depression in the inferior leads, abnormal Q waves in the anterior leads and aVL



Posterior MI

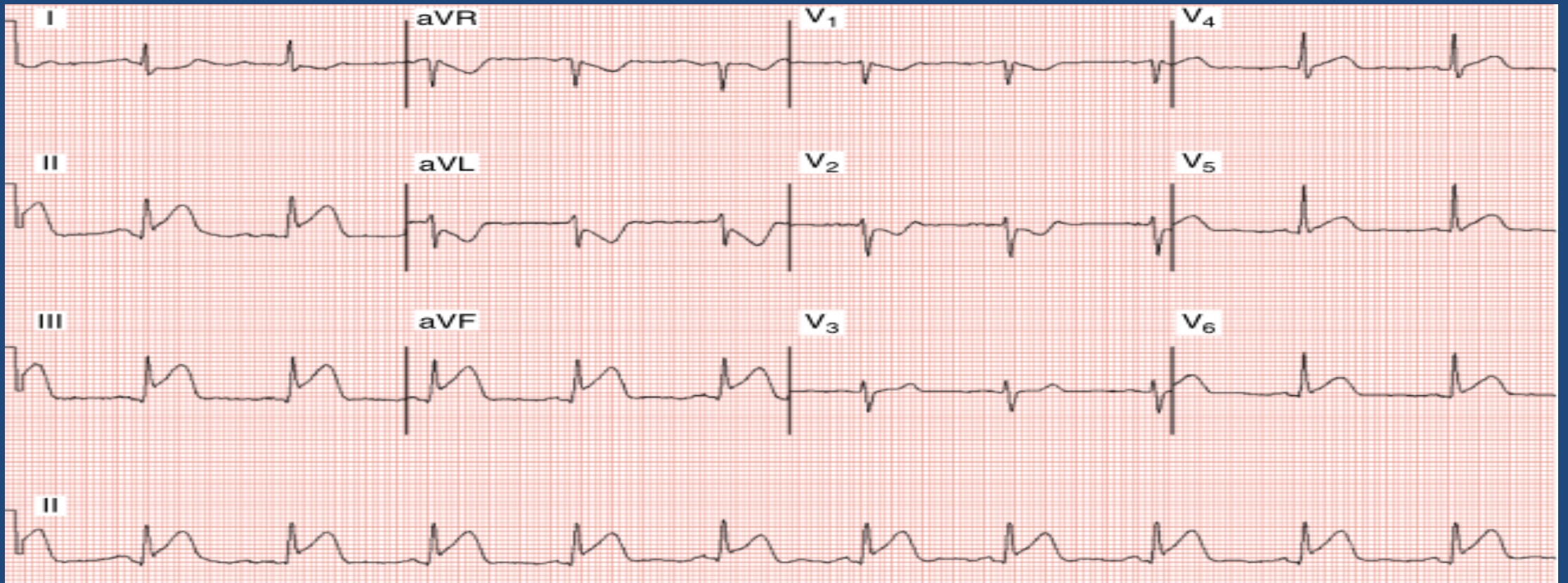
Posterior MI's usually occur in the presence of lateral or inferior MI's but can also occur in isolation. To better view a suspected posterior MI, a posterior ECG is recorded. The additional posterior leads V7, V8 and V9 provide the direct infarction pattern. They are suspected when certain changes occur:

- the mirror image is seen in the anterior (anteroseptal) leads V2 and V3 (and sometimes V1), consisting of positively deflected T waves, ST depression and dominant tall/broad R waves

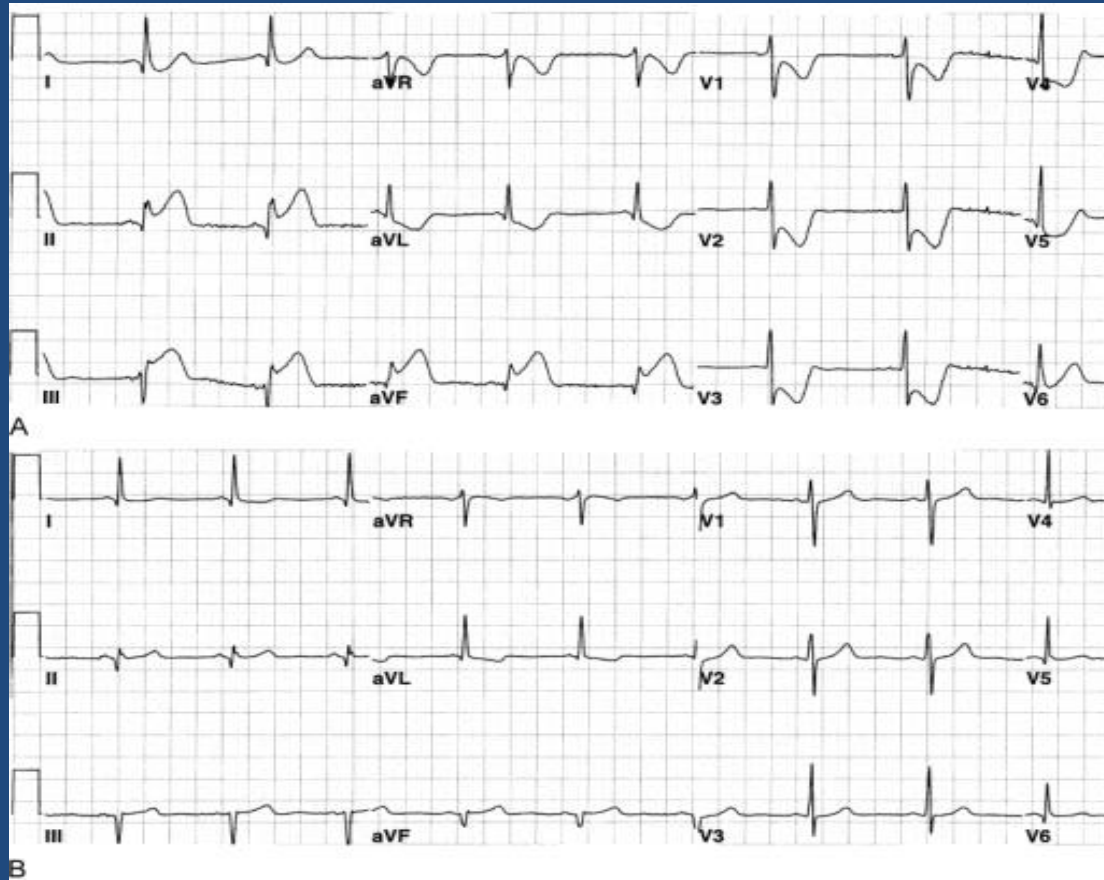


Inferolateral MI

- Typically, ST segment elevation in leads II, III, aVF, V5, and V6. In many cases, however, ST segment elevation extends to the right of lead V5 (i.e., leads V2–V4).
- Reciprocal ST segment depression may be present in leads I, III, aVL, and V1–V4, but it may also be absent



ECG of a 48-year-old man with an inferoposterior myocardial infarction caused by total occlusion of the large-caliber circumflex coronary artery.



- A. Day of infarction, note the ST segment elevation in leads II, III, and aVF and reciprocal ST segment depression in leads I, aVL, and V1–V6.
- B. At 13 hours after angioplasty of the left circumflex artery.

