



# EKG interpretation in excitability disorders

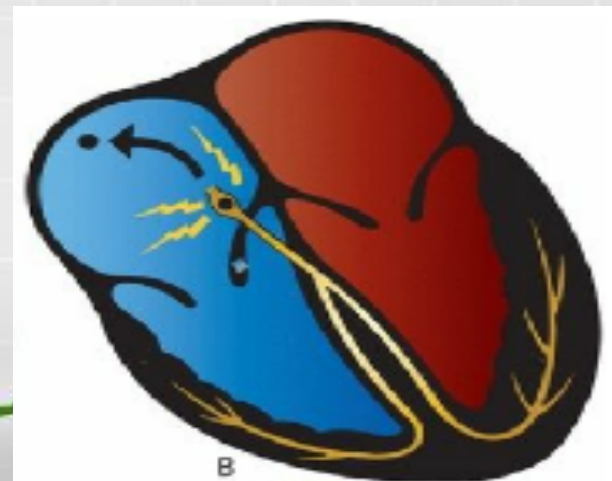
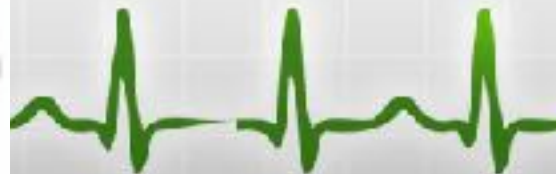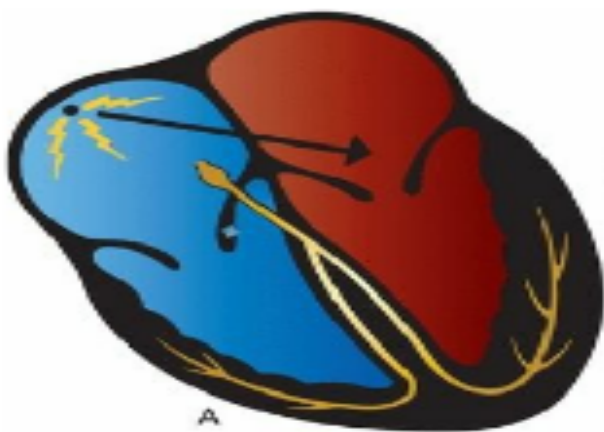
# The two major causes of nonsinus arrhythmias are:

- ectopic rhythms and reentrant rhythms.

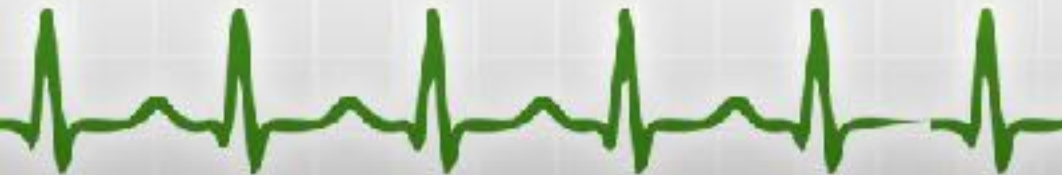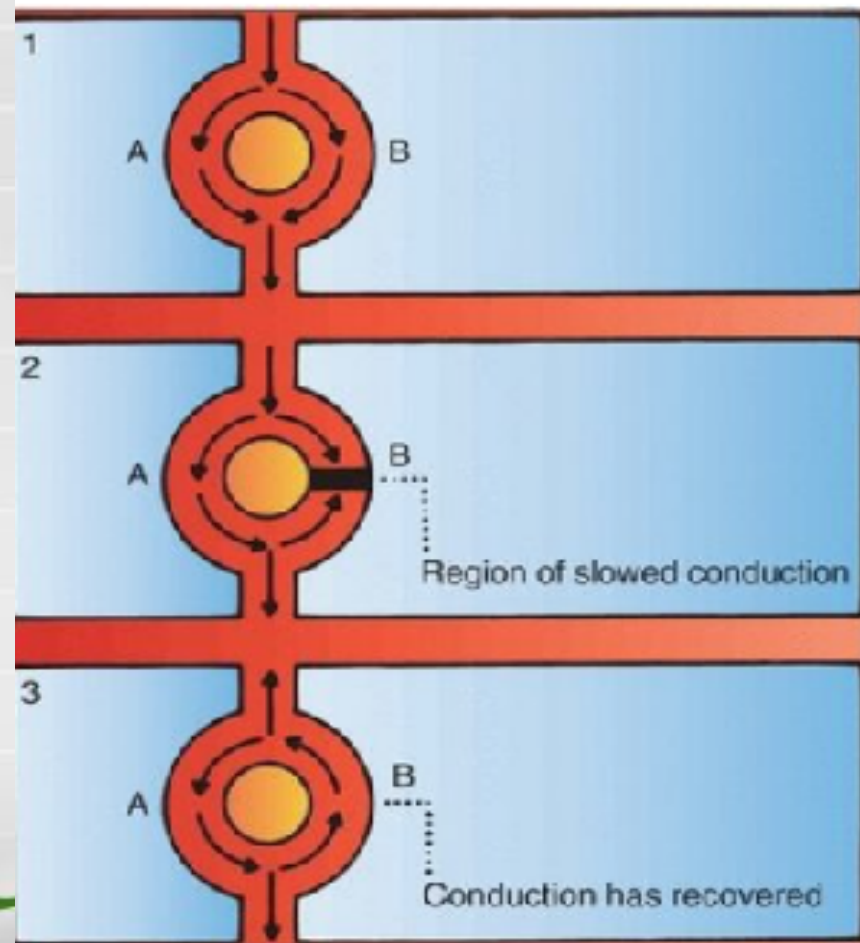
**Ectopic rhythms** - abnormal rhythm that arise from elsewhere than the sinus node. It can consist of a single, isolated beats or sustained arrhythmias.

The fastest pacemaker usually drives the heart, and under normal circumstances, the fastest pacemaker is the **sinus node**.

Under abnormal circumstances, any of other pacemakers scattered throughout the heart can be accelerated, that stimulated to depolarize faster and faster until they can overdrive the normal sinus mechanism and establish their own transient or ectopic rhythm.



- **Reentrant rhythms-** represent a disorder of impulse transmission.



# Classification

## Ectopic arrhythmias

**1. Escape (passive) beats/ rhythms**- they may appear when the automatic activity of the SAN decreases too much or even stops. They are rhythms of salvation, to avoid an asystole.

- Atrials
- Junctionals
- Ventriculars

**2. Usurpation (active) beats/rhythms**- they can appear either inside of the excito-conductor system or outside of this system. The pacemaker activity of these centers is now higher than that of the SAN.

- Wandering pacemaker: atrial, junctional
- Extrasystole (premature contraction): atrial, junctional or ventricular
- Parasystole: atrial, junctional or ventricular
- Tachycardia: fast rhythms up to 250/min. It can be atrial, junctional or ventricular
- Flutter: fast rhythm, rate between 250-350/min. It can be: atrial or ventricular
- Fibrillation: fast rhythm, rate between 400-600/min. It can be: atrial or ventricular



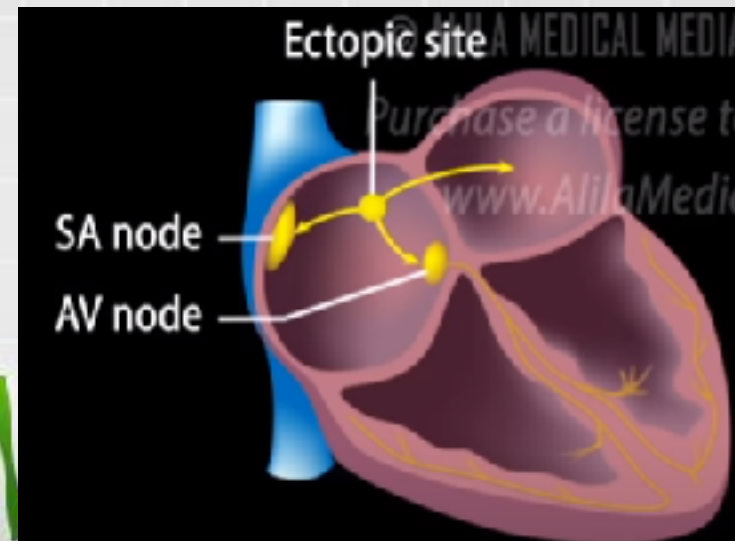
# Atrial Extrasystoles

- When the premature beat arises from an ectopic pacemaker located in the atria.

May occur:

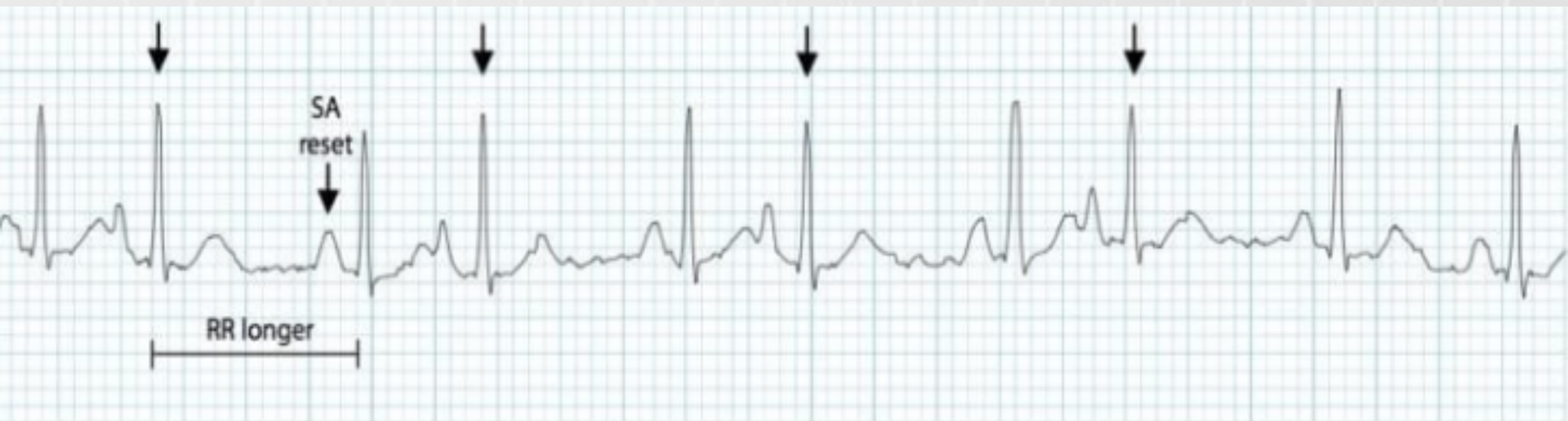- in people with a healthy heart (if they do not have a pathological significance),
- in patients with heart disease (ischemic heart disease, heart failure) in patients with COPD and hypoxemia (due to hypertension of the small circulation) and in patients with hyperthyroidism.

Atrial extrasystoles can precede the installation of supraventricular (atrial) tachycardias, flutter and atrial fibrillation, especially in chronic forms.




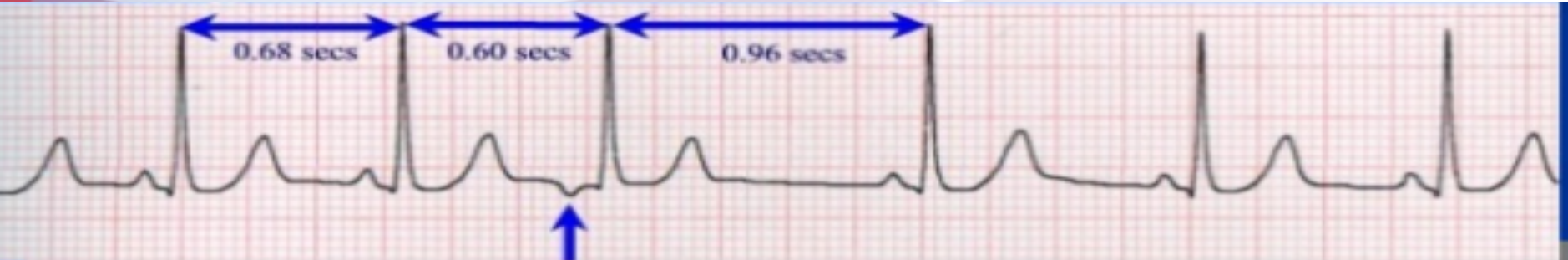
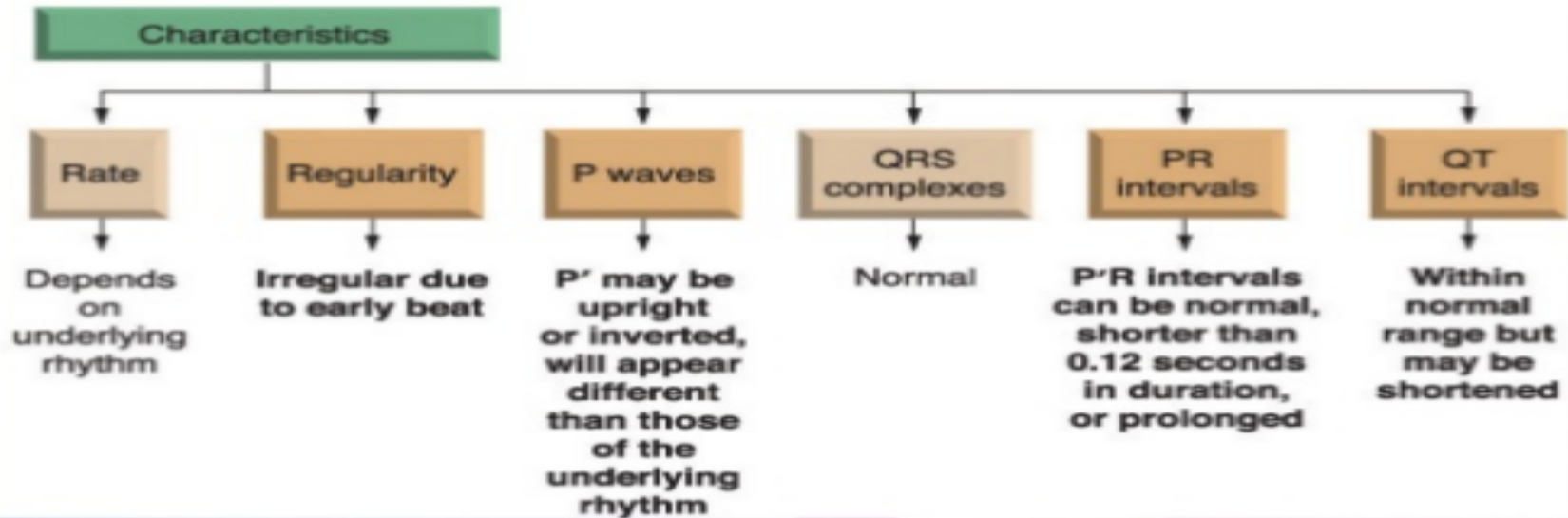
# Atrial Extrasystoles

- An abnormal (non-sinus) P wave is followed by a QRS complex.
- The P wave typically has a different morphology and axis to the sinus P waves.
- The abnormal P wave may be hidden in the preceding T wave, producing a “peaked” or “camel hump”
- P-R interval are frequently shortened, but may be normal and prolonged
- Compensatory pause incomplete (under usual QRS complex configuration)

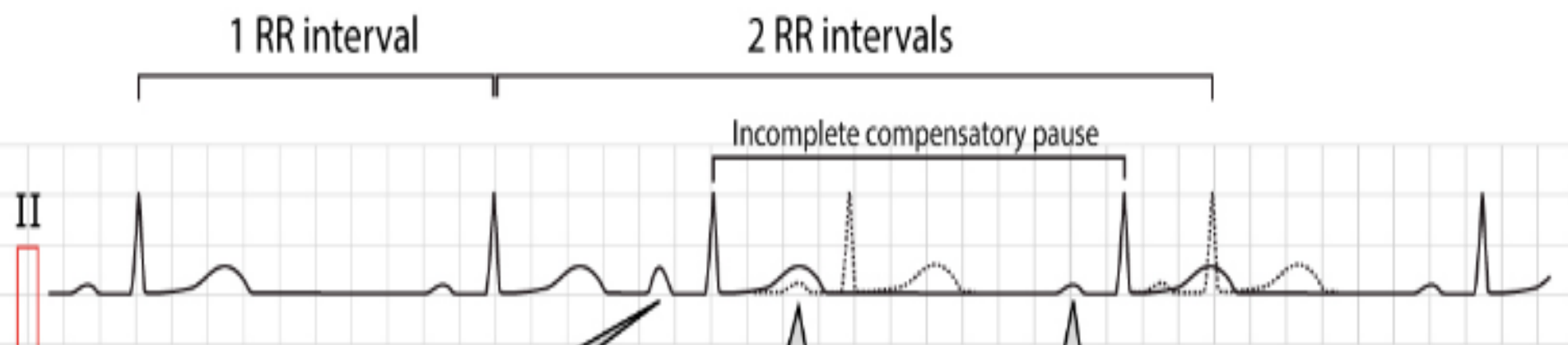


# Atrial Extrasystoles

## Premature Atrial Complexes



## Atrial premature complex (APC) - classical pattern



APC occurs here and it results in ventricular depolarization (QRS-complex). The APC occurs earlier than the next sinus beat was expected, and the P-wave has a different contour as compared with the sinus P-waves (indicating that it did not originate in the sinoatrial node).

1

The dashed line shows where the next normal (sinus) beat would be expected. However this beat will not appear because the APC will depolarize the sinoatrial node and reset it.

2

The next sinus beat occurs earlier than expected. The dashed line shows where the next sinus beat was expected should the APC not have occurred. The distance between the APC and this normal beat is longer than 1 RR interval because it will take some time for the APC impulse to travel to the sinoatrial node, and then reset it. The interval between the normal beat prior to and after the APC is less than 2 RR intervals.

3



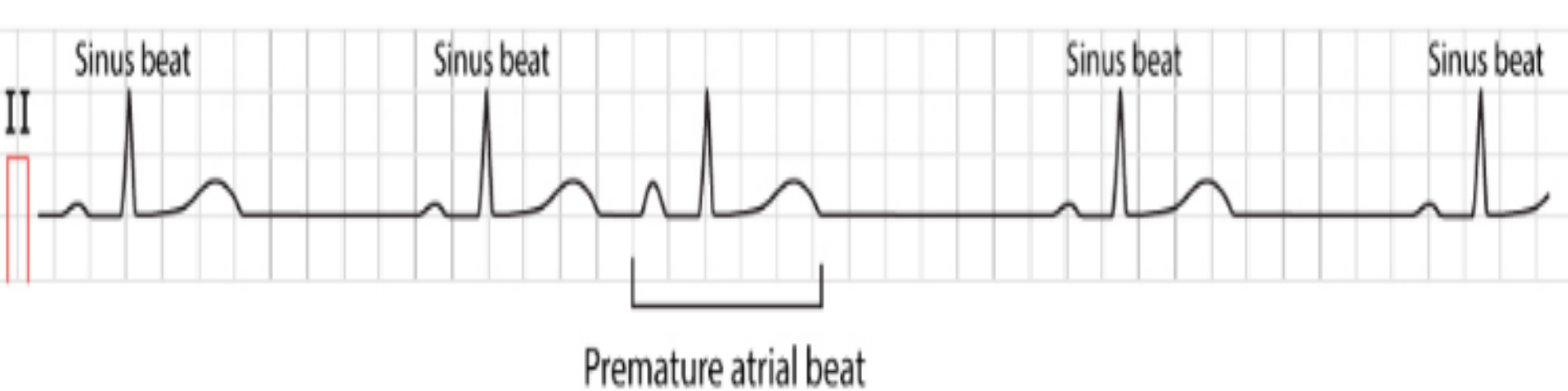
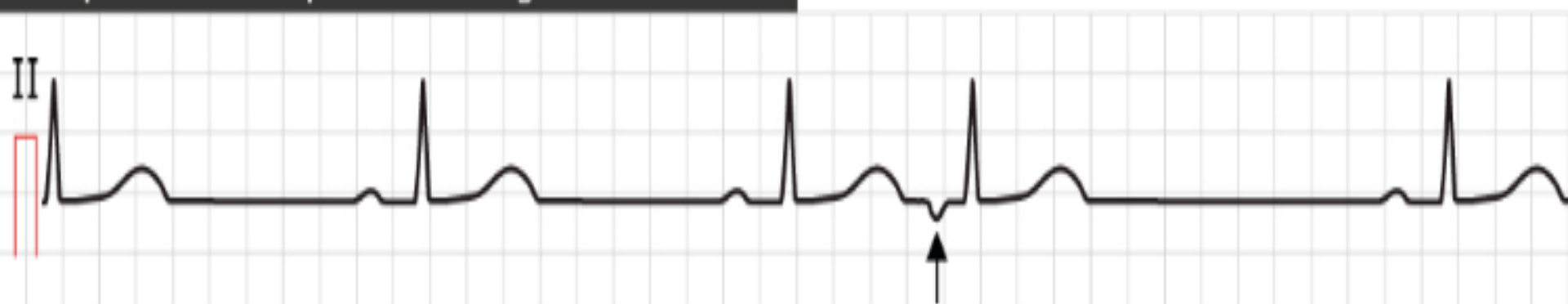


Figure 1. Typical premature atrial contraction (beat / complex).

### Atrial premature complex with retrograde P-wave



The fourth beat is an atrial premature beat. The P-wave is inverted (retrograde) indicating the the ectopic focus is located distally in the atria (presumably around the AV-node). Atrial activation takes place in the opposite direction.

Figure 2. Atrial premature beat with retrograde P-wave.

# Atrial Extrasystoles

## Classification of Premature Atrial Complex (PAC)

### PAC may be either:

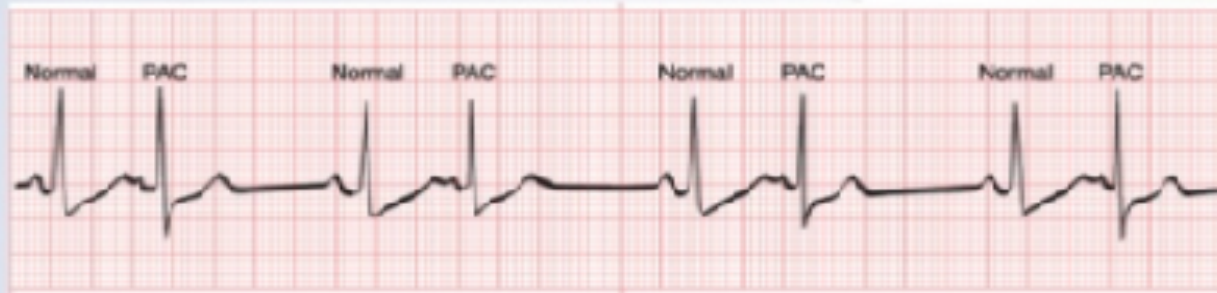- **Unifocal** – Arising from a single ectopic focus; each PAC is identical.
- **Multifocal** – Arising from two or more ectopic foci; multiple P-wave morphologies.

### PAC often occur in repeating patterns:

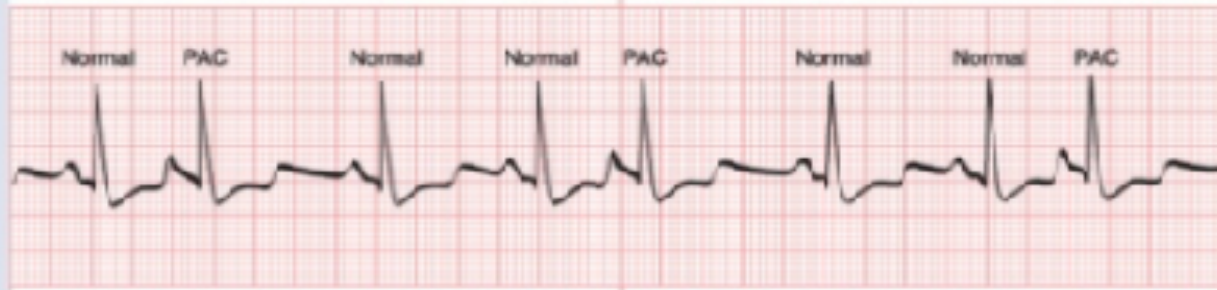- **Bigeminy** — every other beat is a PAC.
- **Trigeminy** — every third beat is a PAC.
- **Quadrigeminy** — every fourth beat is a PAC.
- **Couplet** – two consecutive PAC.
- **Triplet** — three consecutive PAC.
- 



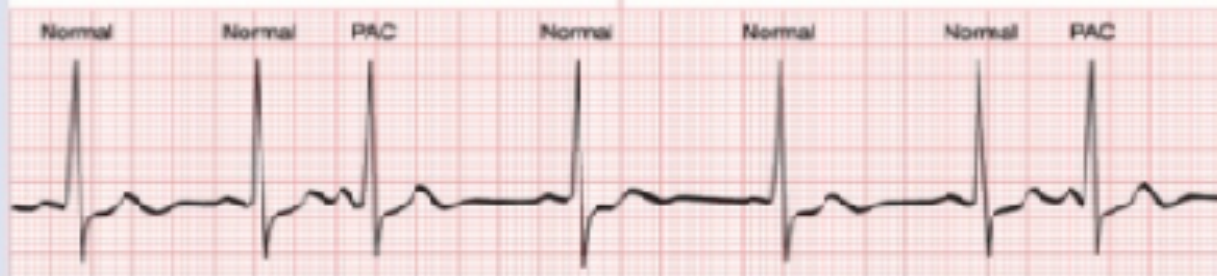# Atrial Extrasystoles



Bigeminal



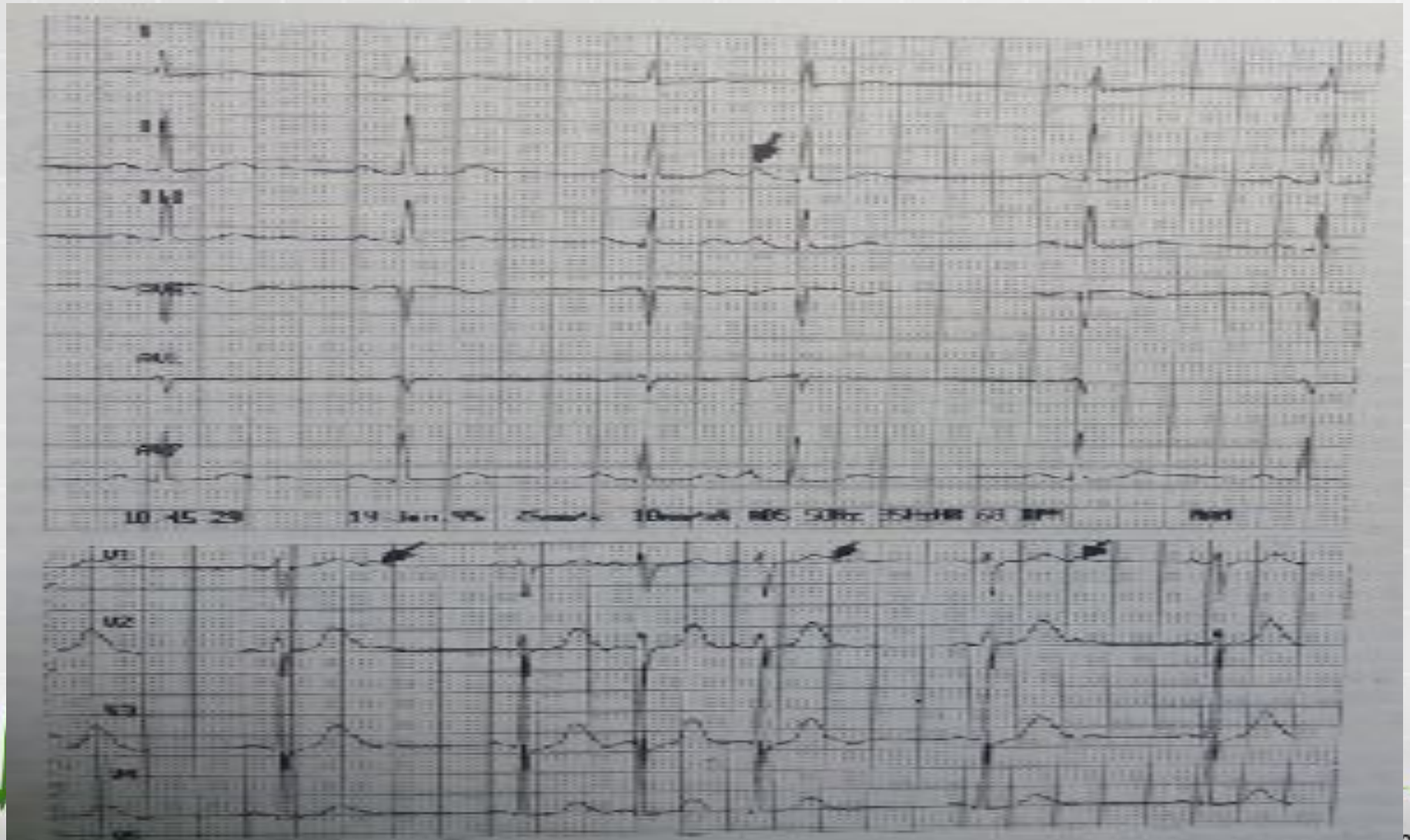
Trigeminal



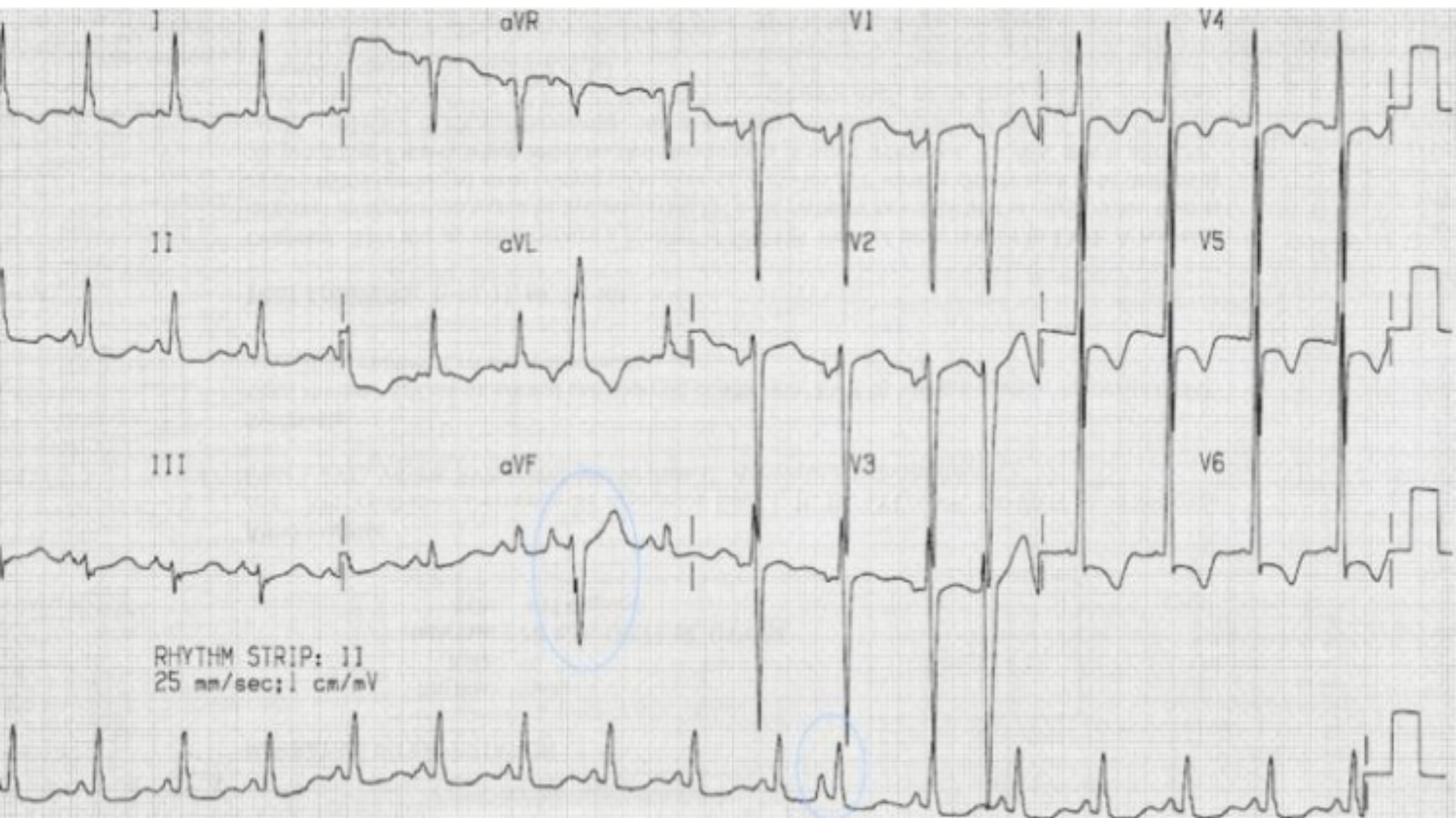Quadrigeminal



# Atrial Extrasystoles (premature atrial complex)

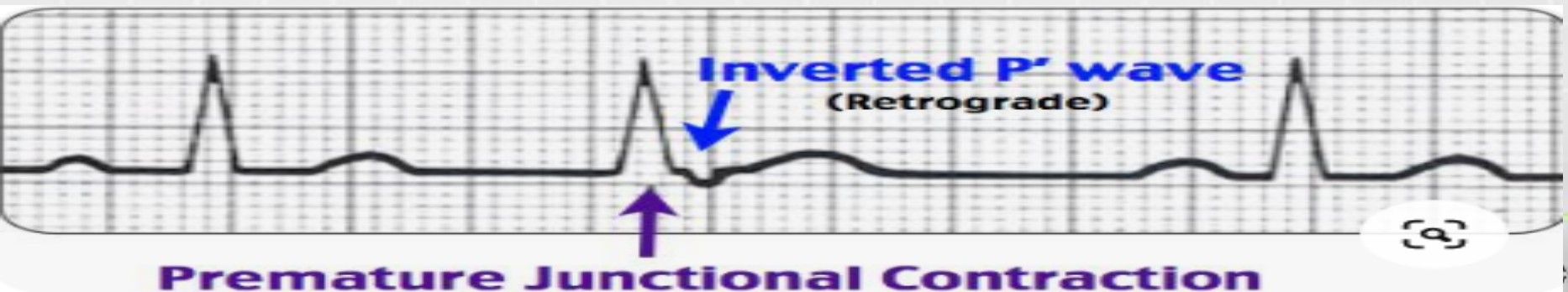

# Atrial Extrasystoles (premature atrial complex)



# Junctional extrasystoles

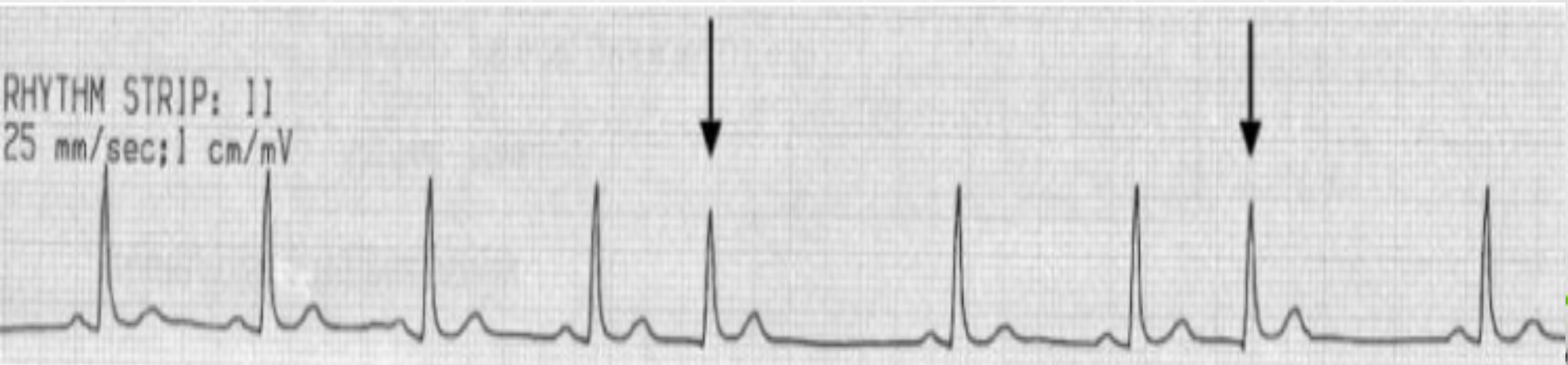
- are much less common than PAC or PVC.
- these arise from the region of the AV node, so the ventricles are usually activated normally
- Narrow QRS complex, either (1) without a preceding P wave or (2) with a retrograde P wave which may appear *before, during, or after* the QRS complex. If before, there is a short PR interval of  $< 120$  ms and the “retrograde” P waves are usually inverted in leads II, III and aVF.
- Followed by a compensatory pause.



# Junctional extrasystoles

## Typical appearance of PJC's:

- Premature QRS complex (relative to the basic RR interval) which may be narrow or wide (if underlying bundle branch block or aberrancy)
- The P wave may precede the QRS by  $\leq 0.11$  seconds (retrograde atrial activation,), may be buried in the QRS (and not visualized), or may follow the QRS complex
- Inverted P waves in leads II, III, aVF and upright P waves in leads I and aVL are commonly seen due to the spread of atrial activation from near the AV node and in a superior and leftward direction



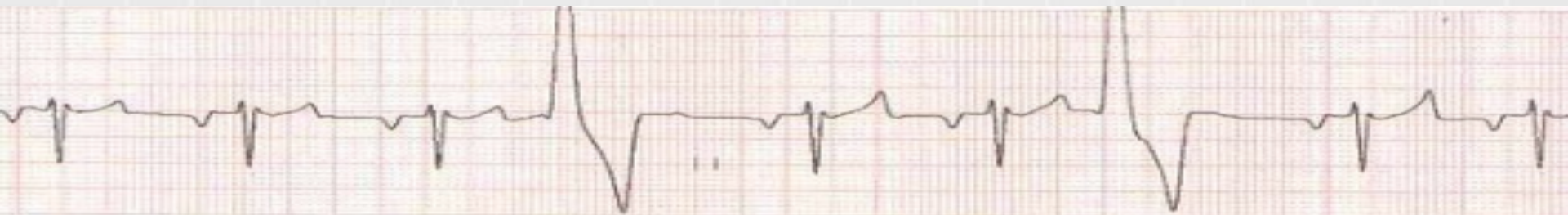
# Ventricular extrasystoles (ventricular premature beat)

- A premature beat arising from an ectopic focus within the ventricles.

## Causes:

- Anxiety
- Sympathomimetics
- Beta-agonists
- Excess caffeine
- [Hypokalaemia](#)
- [Hypomagnesaemia](#)
- [Digoxin toxicity](#)
- [Myocardial ischemia](#)

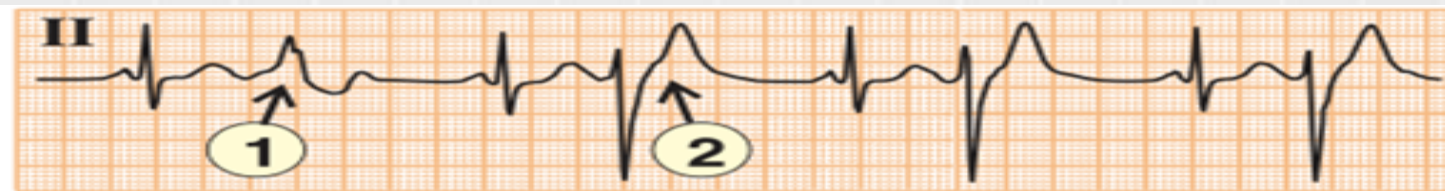These are among the most common arrhythmias and occur in patients with and without heart disease.





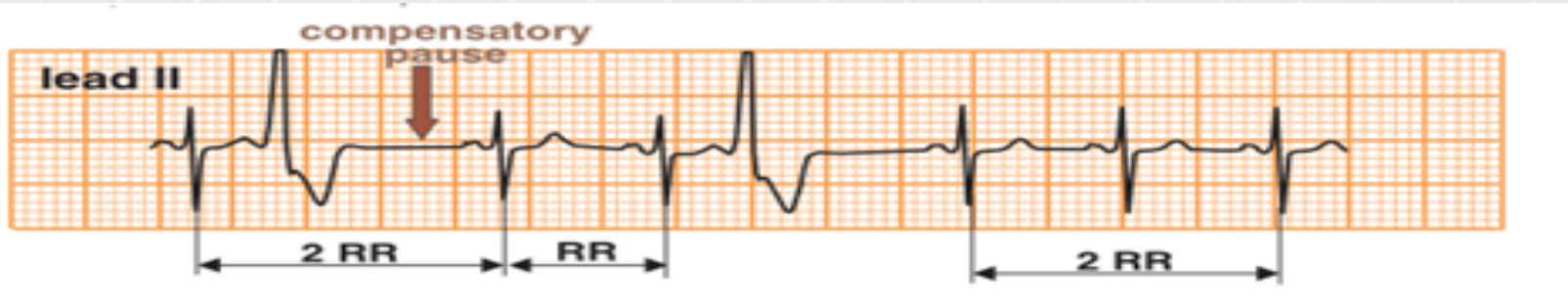# Ventricular extrasystoles (ventricular premature beat)

- Almost 30% of all healthy individuals display premature ventricular contractions during exercise stress testing.
- In patients without heart disease, VE have not been shown to be associated with any increased incidence in mortality or morbidity.
- VE may occur in up to 80% of patients with previous myocardial infarction.
- are commonly encountered in patients with other types of organic heart disease, including hypertensive and rheumatic heart disease and cardiomyopathies, in patients with rheumatic or valvular heart disease.

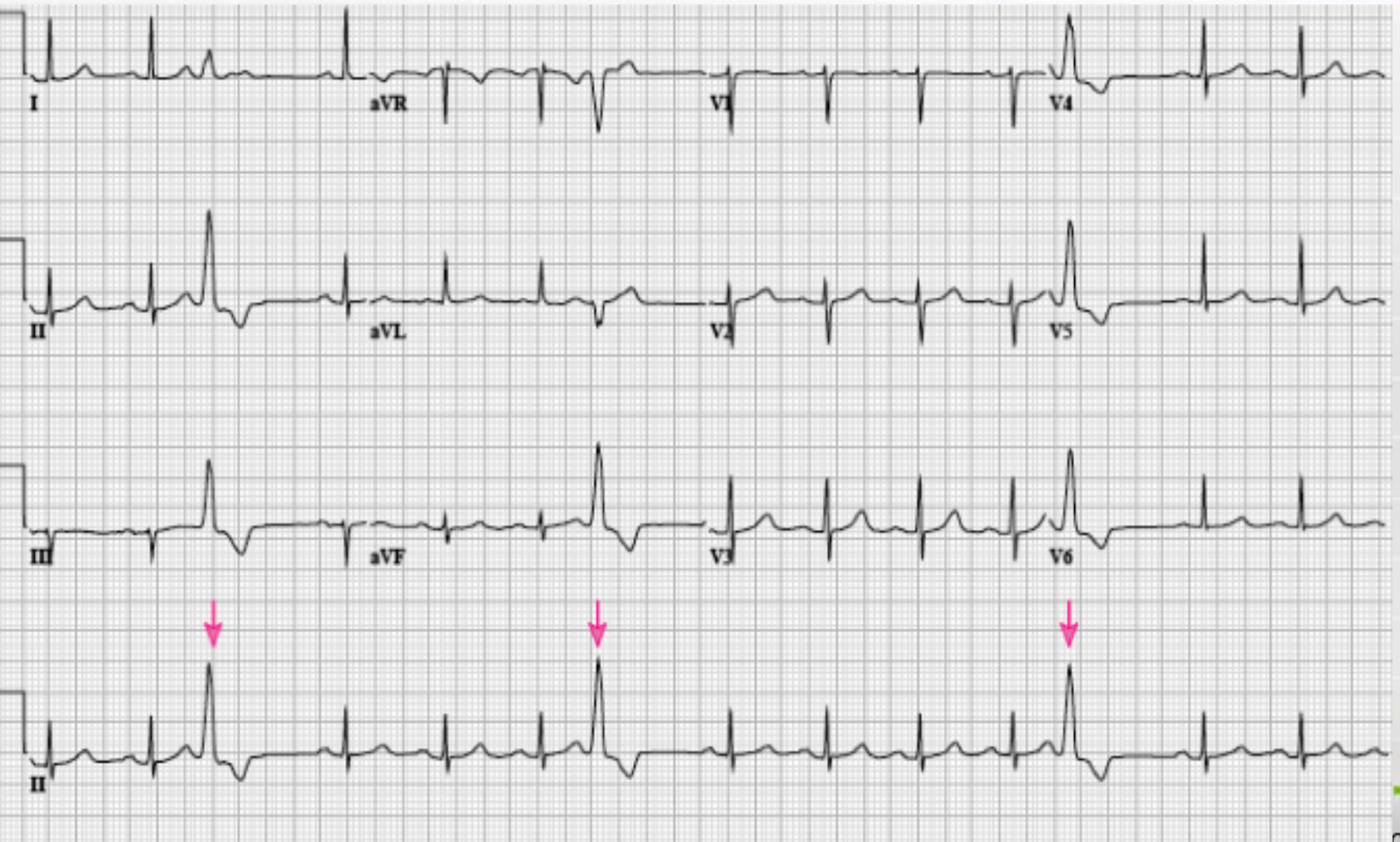


# Ventricular extrasystoles (ventricular premature beat)

1. premature appearance of the ventricular complex
2. absence of P wave;
3. deformation of the QRS complex;
4. since the sequence of relaxation in the ventricles is not synchronous the shape and the height of the T wave changes as well. As a rule, it is enlarged and its direction is opposite to that of the maximum wave of the complex (the T wave is negative if R wave is high and positive if S wave is deep).
5. The ventricular extrasystole is followed by a complete compensatory pause (except in interpolated extrasystoles)



# Ventricular extrasystoles (ventricular premature beat)

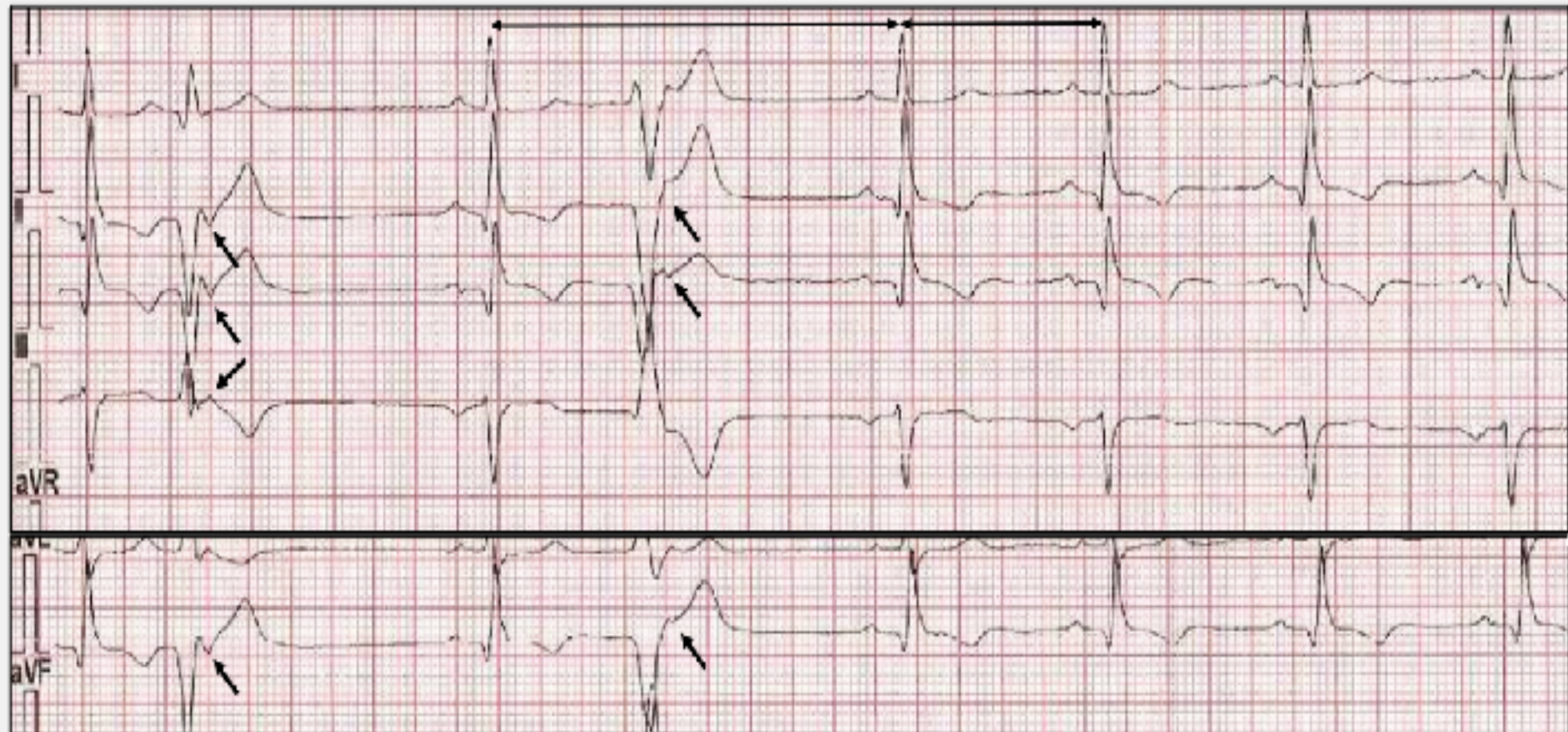

# Ventricular extrasystoles (ventricular premature beat)

Frequently, the VES wave front propagates retrograde through the AVN before the anterograde arrival of the depolarization front originating in the SAN. Hence, the depolarization front with intraventricular origin will retrograde depolarize the atria and will "reset" the SAN, just as an AES does. On the ECG we will see the appearance of a negative P' wave in D<sub>I</sub>, D<sub>II</sub>, AvF and a positive P' wave in AvR after and tightly glued to the QRS complex of the VES (arrows in the image below). This is an "atrial capture"

1920 msec.

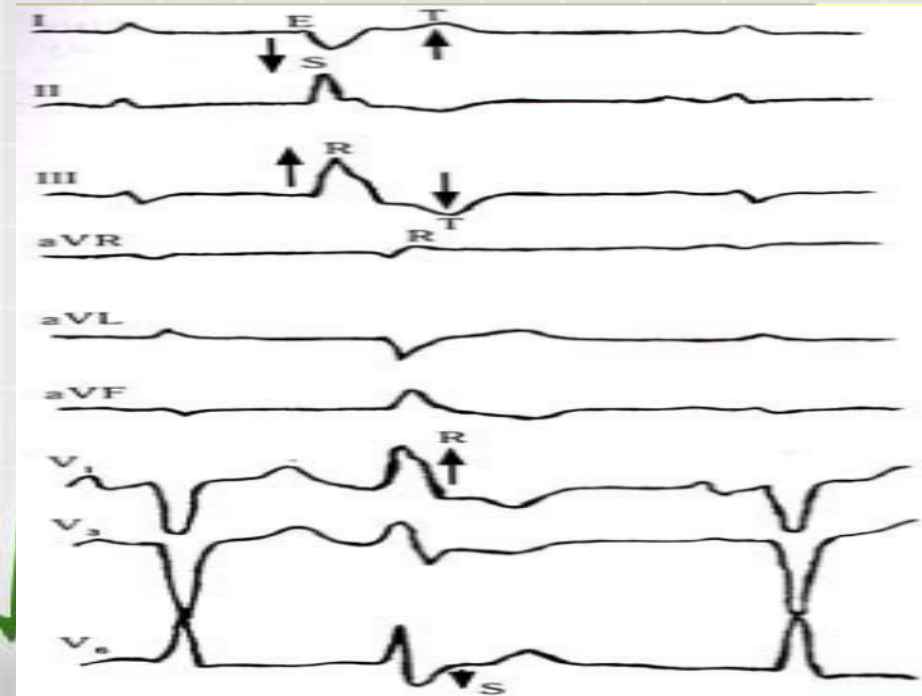
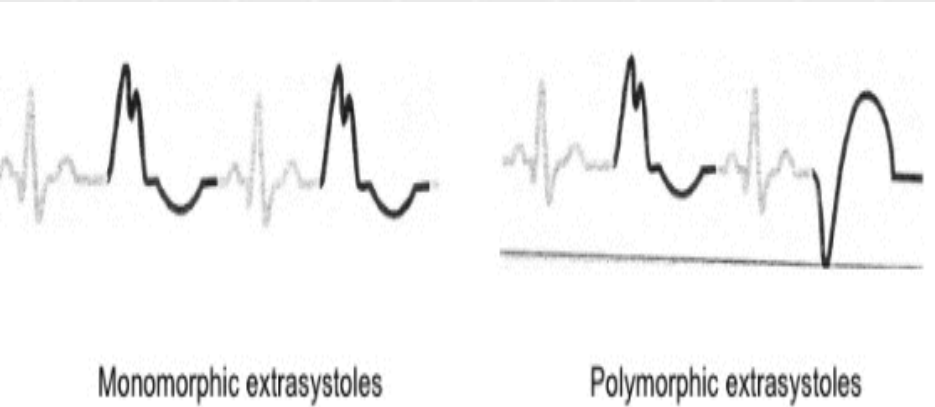
960 msec.



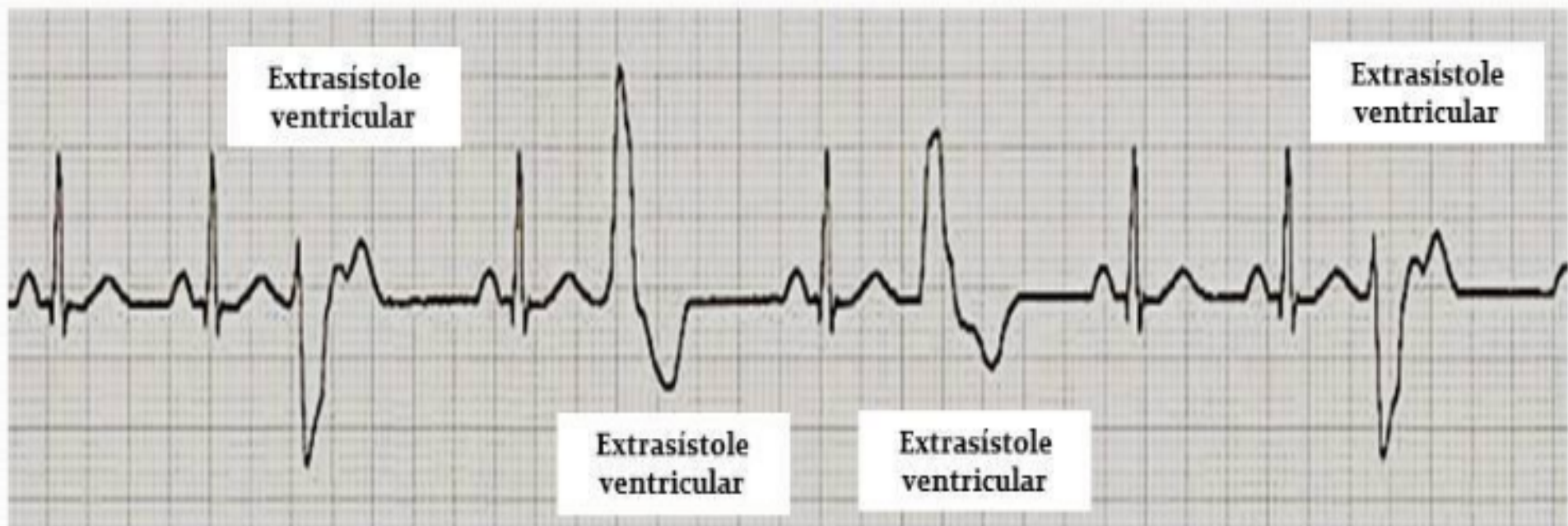
# Multifocal ventricular extrasystole

## *Morphology and Origin:*

- Monomorphic VPBs originate from the same focus and are called unifocal;
- Polymorphic VPBs might be unifocal with varying ventricular activation (the coupling interval is equal), or multifocal (varying coupling intervals)



# Multifocal ventricular extrasystole

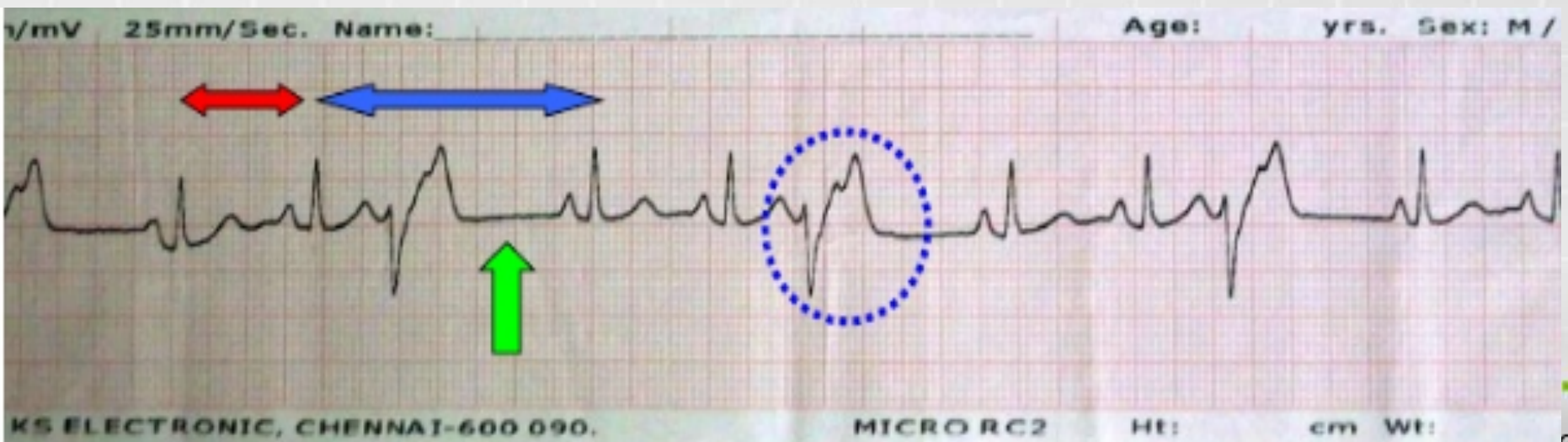


# Ventricular extrasystoles (ventricular premature beat)

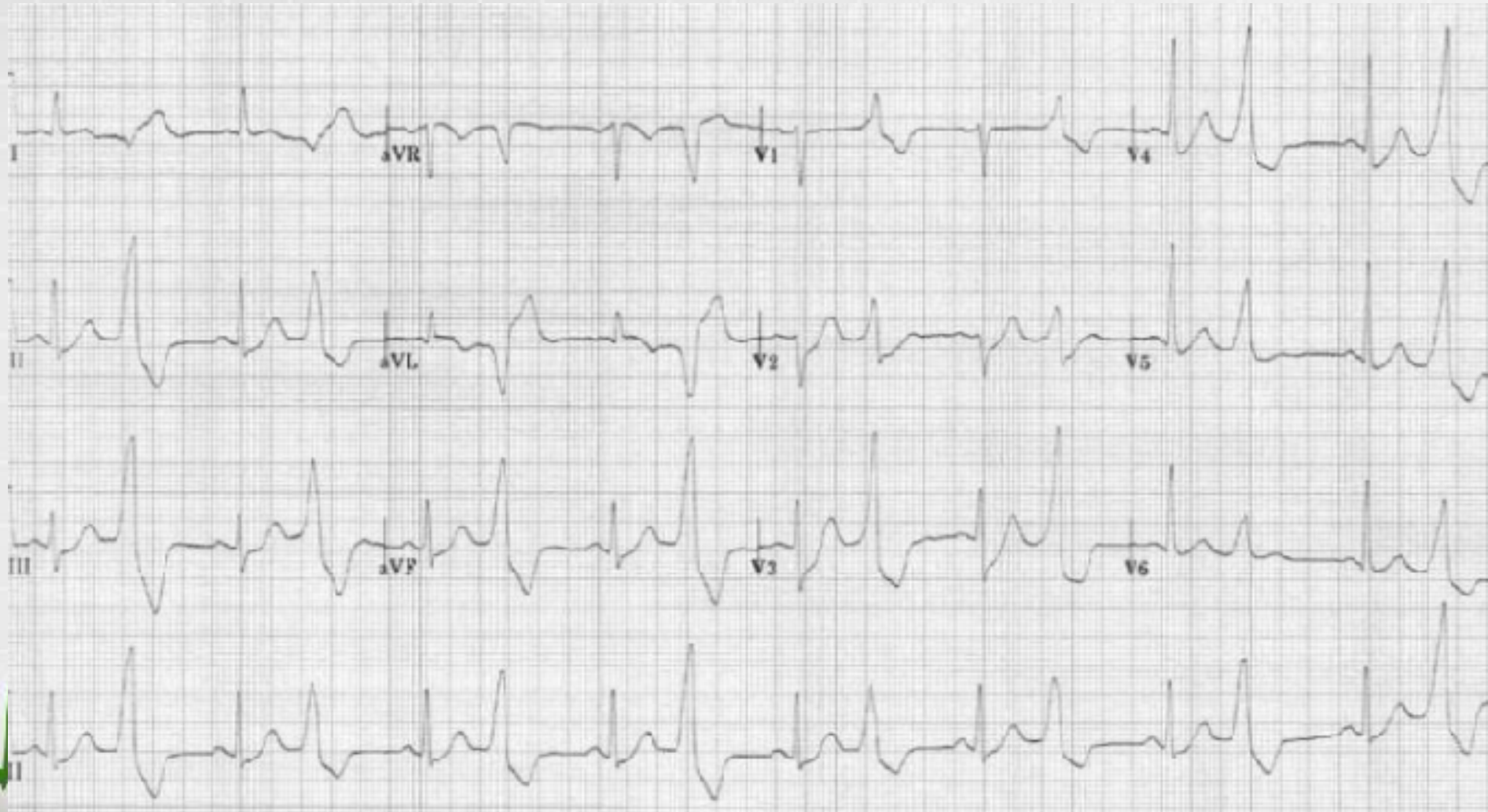
**ALLORHYTHMIA**- An irregularity in the cardiac rhythm that repeats itself any number of times.

**Variants:**

- If every sinus beat is followed by a VPC -bigeminy;
- If two sinus beats are followed by a VPC -trigeminy;
- Quadrigeminy - three sinus beats are followed by a VPC

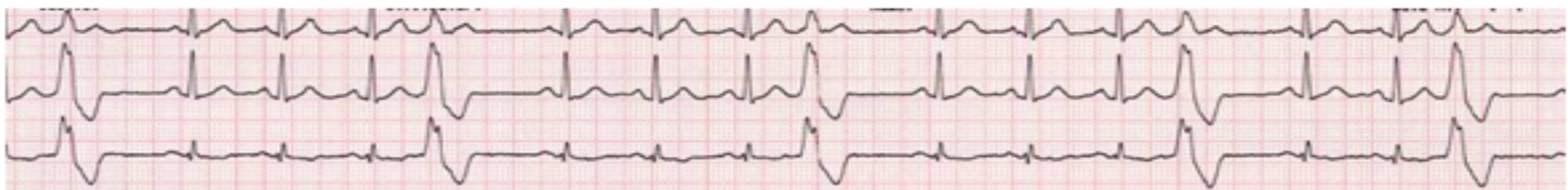
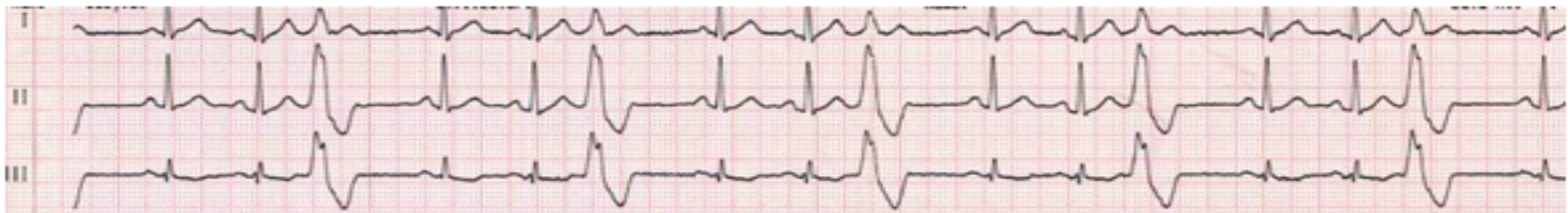
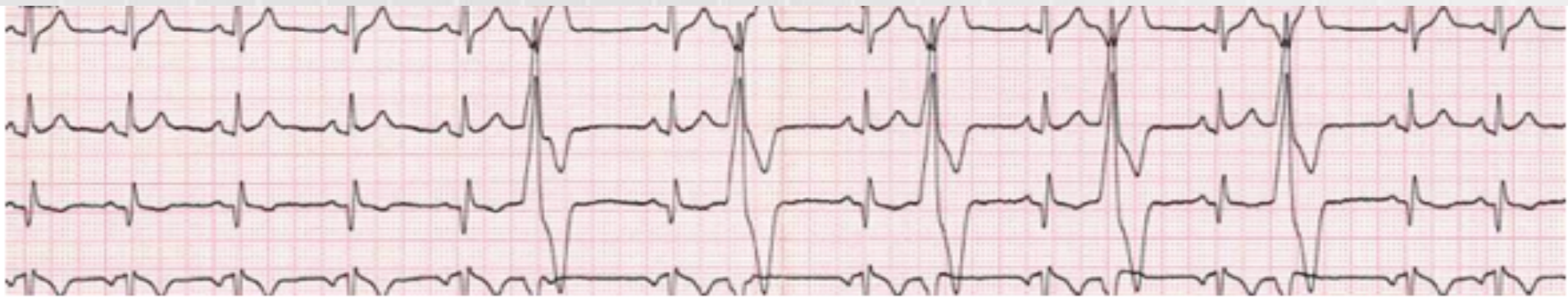# Ventricular bigeminy

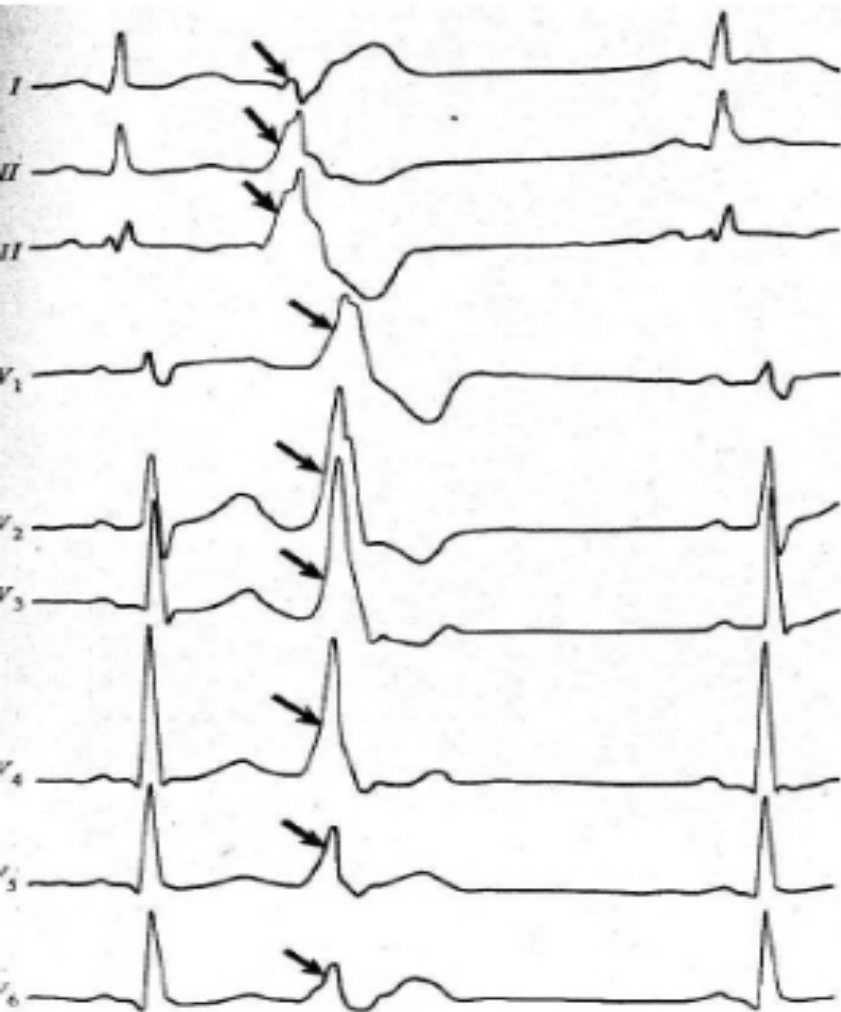




# Ventricular extrasystoles

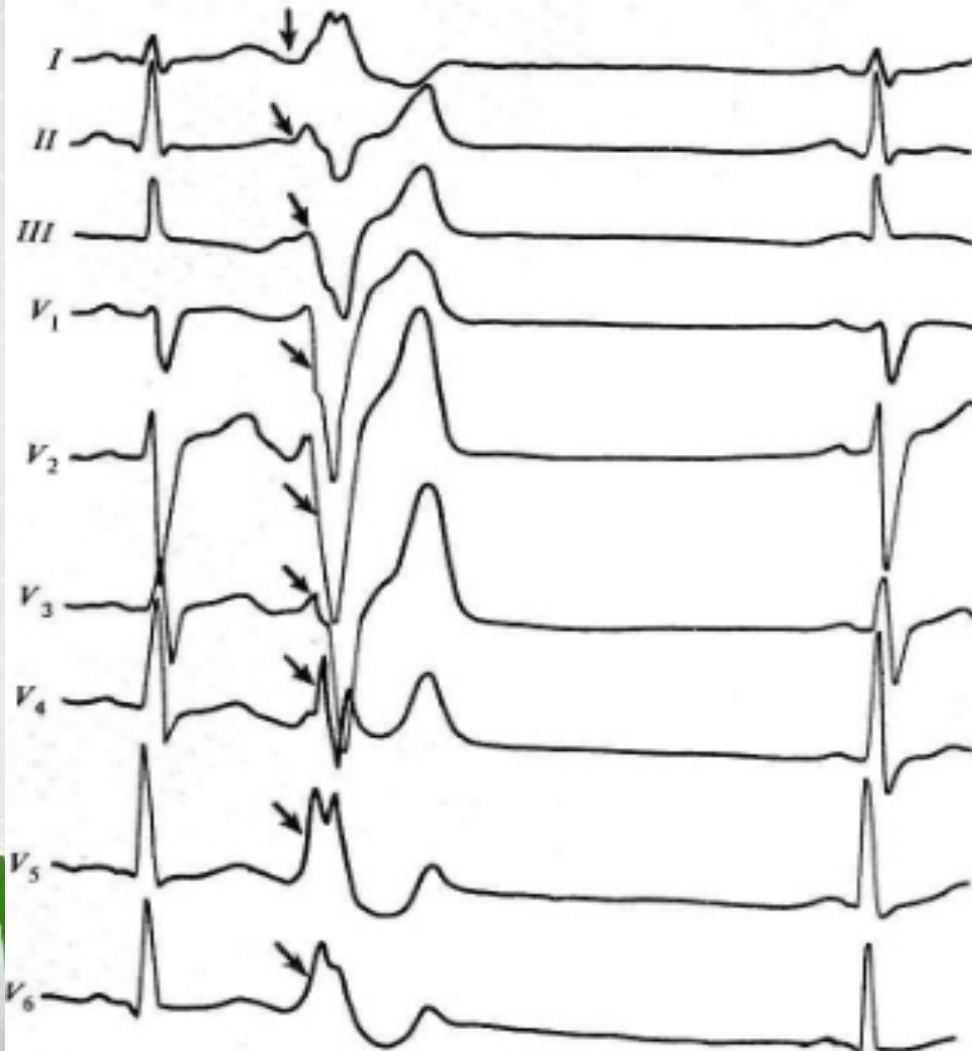

# Left ventricular extrasystole



- high *R* wave in the standard lead III and the deep *S* wave in the standard lead I;
- high *R* wave in the right chest leads (V1-V2) and a broad or deep *S* wave in the left chest leads (V5-V6).

# Right-ventricular extrasystole



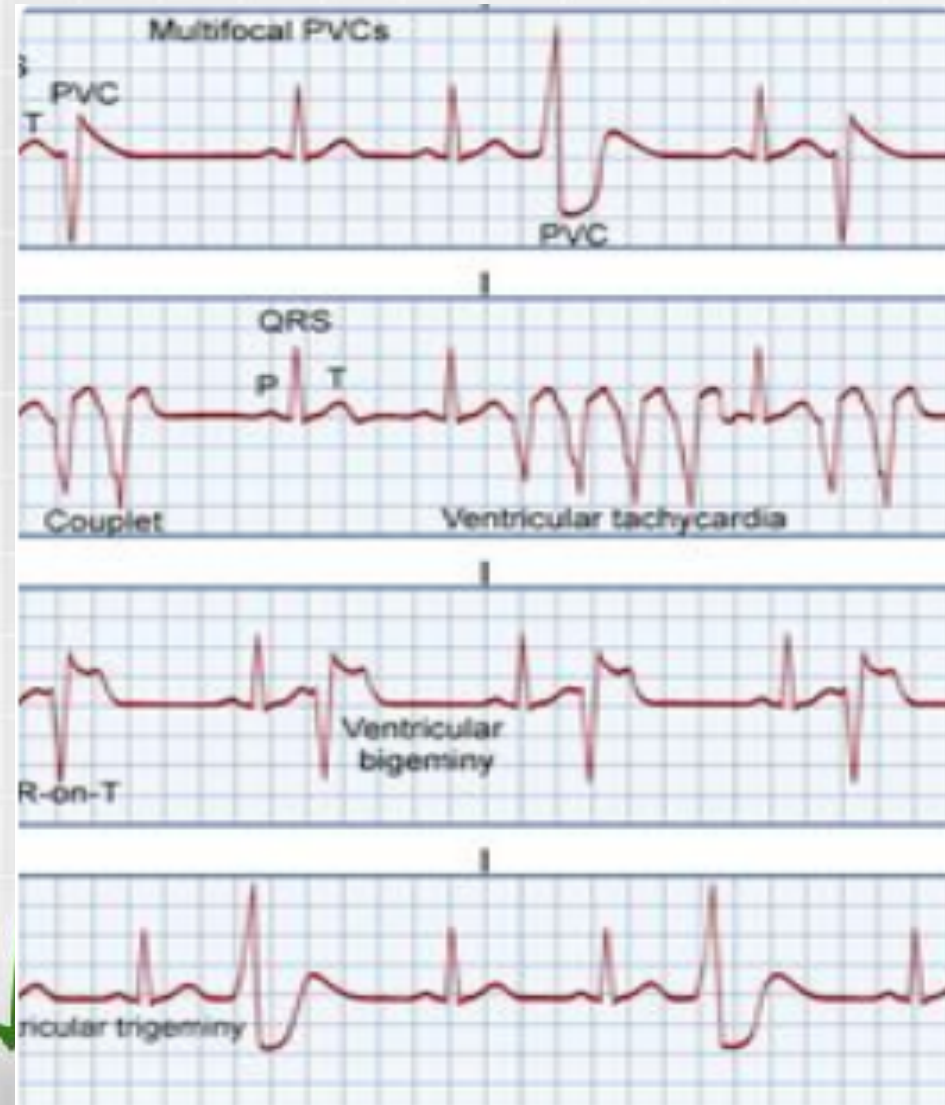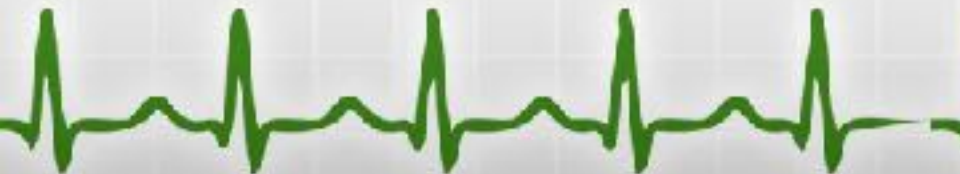- high *R* wave in the standard lead I, and a deep *S* wave in the standard lead III;
- the deep *S* wave in the right chest leads (*V*1-*V*2) and a high *R* wave in the left chest leads (*V*5-*V*6).

# Ventricular extrasystole

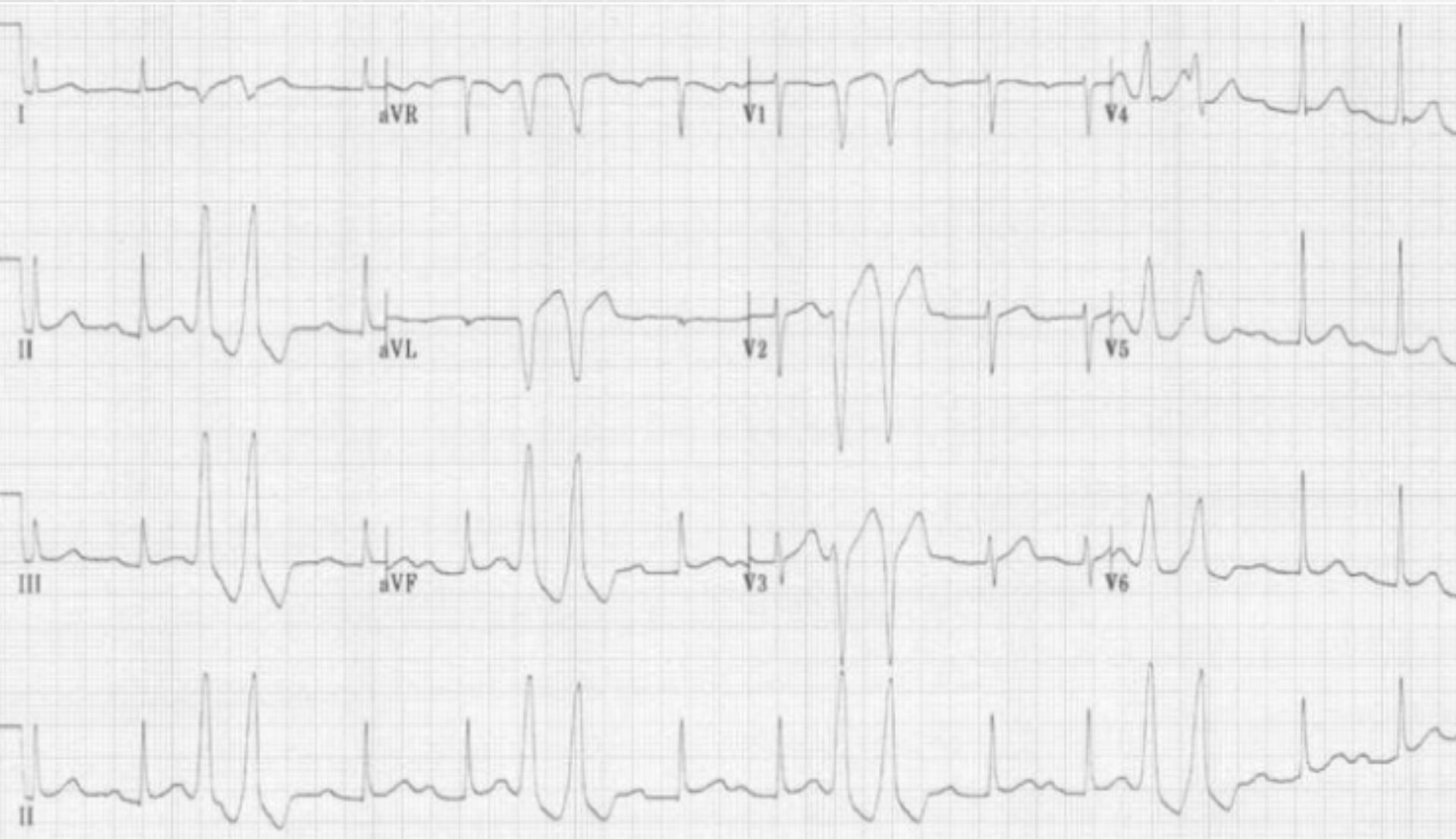VE occurring 2 in a row- **pair or couplet**

VE occurring 3 or more in a row- **ventricular tachycardia**

**VE** falling on the T wave of the previous beat, called the "R-on-T" phenomenon. The T wave is vulnerable period in the cardiac cycle, and a VE falling there is more likely to set off ventricular tachycardia.



# PVC Pairs (Couplets)



# Ventricular extrasystole

VPBs that meet the following criteria are considered to be “dangerous” or “malignant”:

- Occurring frequently (6 or more beats/min)
- In showers with runs of ventricular tachycardia
- In couplets or VPBs in bigeminal rhythm
- With short coupling interval (R-on-T phenomenon)
- More than 0.14 sec wide, bizarre or multifocal
- Associated with serious organic heart disease and left ventricular dysfunction.



# Paroxysmal atrial tachycardia (PAT)

**Paroxysmal atrial tachycardia (ectopic atrial tachycardia):** -is a form of supraventricular tachycardia, originating within the atria, but outside of the sinus node, a regular rhythm with a rate of 100-200 beats/min.

Three major types of atrial tachycardia are seen:

- focal atrial tachycardia,
- multifocal atrial tachycardia (MAT)
- re-entrant atrial tachycardia.

These arrhythmias have unique arrhythmic substrates and characteristics.

- can occur in persons with structurally normal hearts.
- multiple causes including digoxin toxicity, catecholamine excess, congenital abnormalities; may be idiopathic.



# Manifestations of atrial tachycardia

- Rapid pulse rate: In most atrial tachycardias, the rapid pulse is regular; it may be irregular in rapid atrial tachycardias with variable AV conduction and in multifocal atrial tachycardia
- Episodic or paroxysmal occurrence
- Sudden onset of palpitations
- Dyspnea, dizziness, lightheadedness, fatigue, or chest pressure



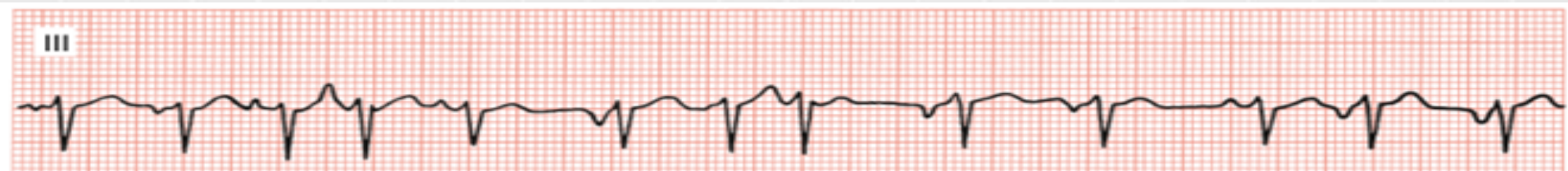

# Multifocal Atrial Tachycardia

- If impulses arise from numerous atrial foci, it constitutes a multifocal atrial tachycardia (MAT) or a chaotic atrial rhythm.
- MAT is a fast rhythm at a rate of 100 to 150 beats/min characterized by a beat-to-beat variability in P wave configuration representing a changing focus of origin of impulses.

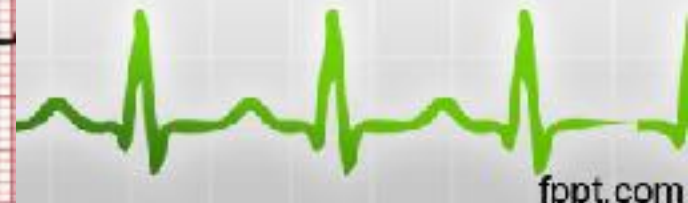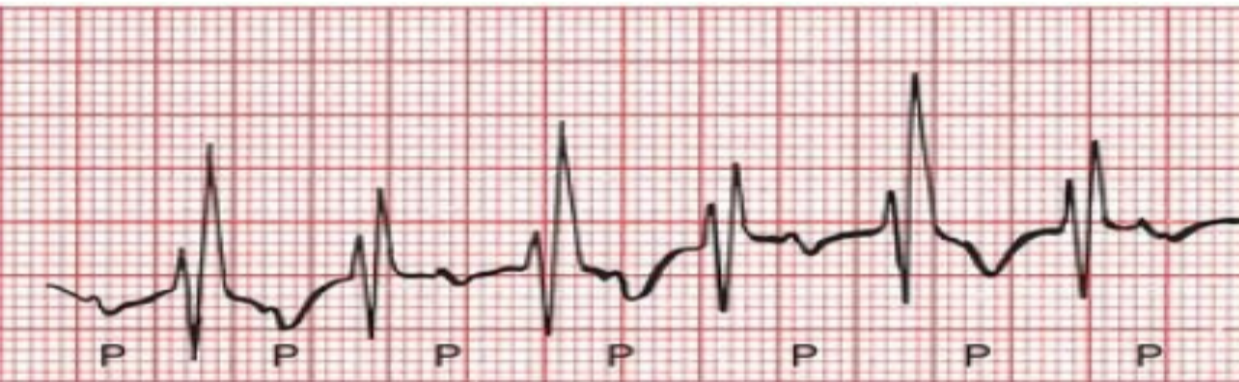MAT can be recognized by the following features:

- Varying PP and PR intervals
- P waves may be blocked (i.e., not followed by a QRS complex), or may be conducted with a narrow or wide

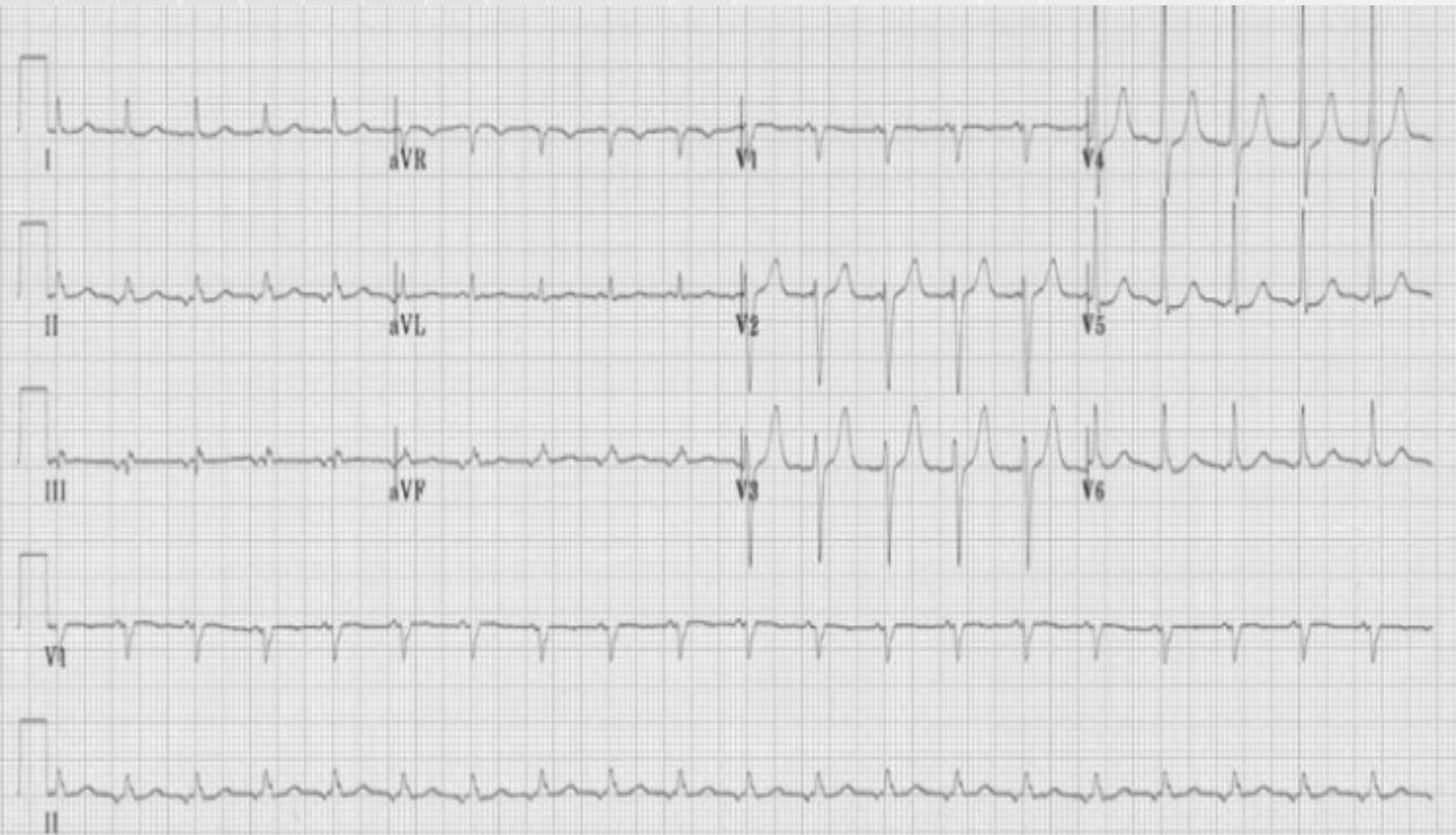


# Paroxysmal atrial tachycardia (PAT)

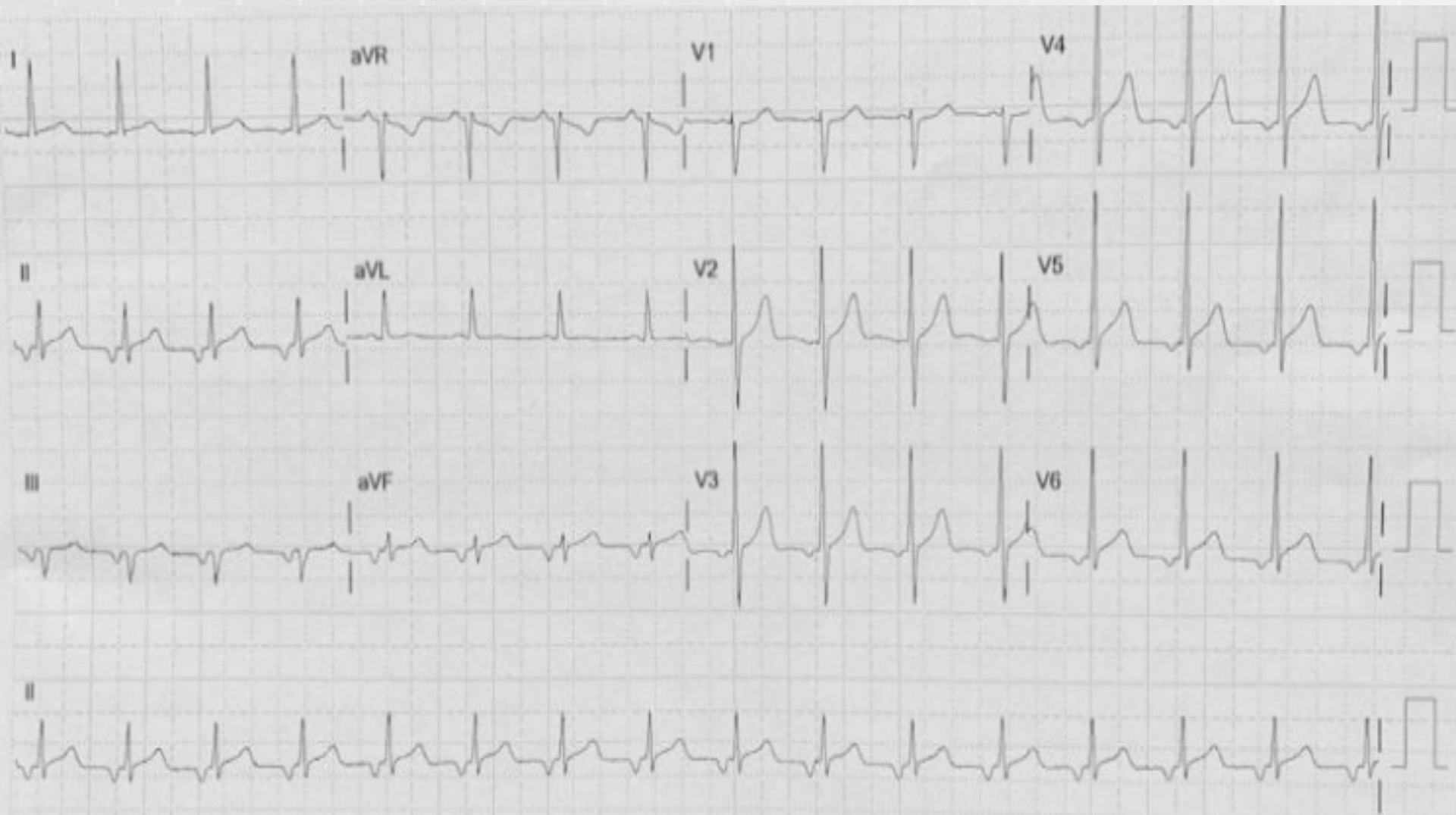
- P wave morphology is abnormal when compared with sinus P wave due to ectopic origin.
- There is usually an abnormal P-wave axis (e.g. inverted in the inferior leads II, III and aVF)
- At least three consecutive identical ectopic p waves.
- QRS complexes usually normal morphology unless pre-existing bundle branch block, accessory pathway, or rate related aberrant conduction.



# Paroxysmal atrial tachycardia (PAT)

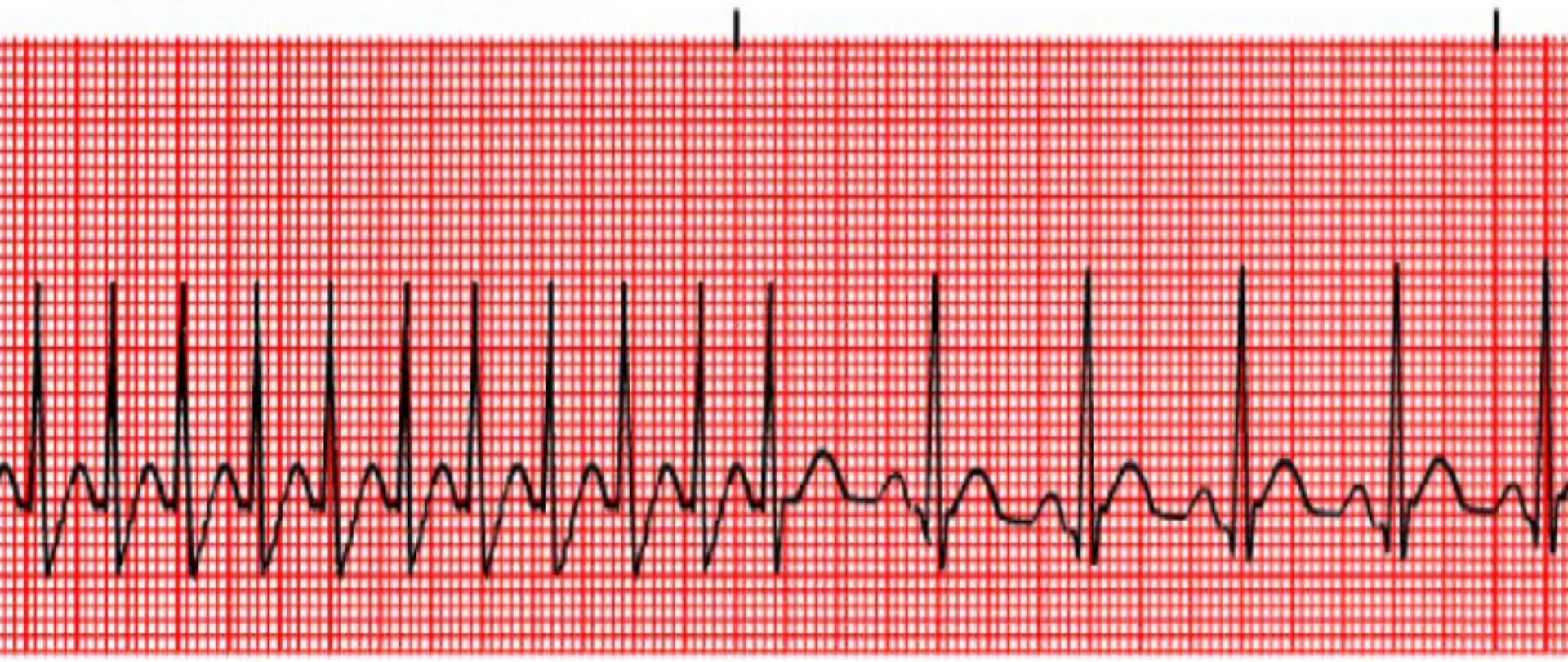


# Paroxysmal atrial tachycardia (PAT)



# Paroxysmal atrial tachycardia (PAT)

PAROXYSMAL ATRIAL TACHYCARDIA



# Atrioventricular node re-entrant tachycardia (AVNRT)

- AV nodal re-entrant tachycardia (AVNRT) is the most common form of paroxysmal supraventricular tachycardia (PSVT), comprising approximately 60-70% of all regular supraventricular tachycardias.
- is a form of re-entrant rhythm within the region of the atrioventricular (AV) node;
- this is the commonest cause of palpitations in patients with structurally normal hearts
- AVNRT is typically paroxysmal and may occur spontaneously or upon provocation with exertion, caffeine, alcohol, beta-agonists (salbutamol) or sympathomimetics;
- it is more common in women than men (~ 75% of cases occurring in women) and may occur in young and healthy patients as well as those suffering chronic heart disease.



# Atrioventricular node re-entrant tachycardia (AVNRT)

- patients will typically complain of the sudden onset of rapid, regular palpitations. The patient may experience a brief fall in blood pressure causing presyncope or occasionally syncope;
- If the patient has underlying coronary artery disease the patient may experience chest pain similar to angina (tight band around the chest radiating to left arm or left jaw);
- The condition is generally well tolerated and is rarely life threatening in patients with pre-existing heart disease



# Atrioventricular node re-entrant tachycardia (AVNRT)

## General Features of AVNRT

- Regular tachycardia ~140-280 bpm.
- QRS complexes usually narrow (< 120 ms) unless pre-existing bundle branch block, accessory pathway, or rate related aberrant conduction.
- ST-segment depression may be seen with or without underlying coronary artery disease.
- P waves if visible exhibit *retrograde conduction* with P-wave inversion in leads II, III, aVF
- P waves may be buried in the QRS complex, visible after the QRS complex, or very rarely visible before the QRS complex.






# Types of atrioventricular node re-entrant tachycardia

## A) Typical AVNRT (slow-fast): 90% of all cases



In most cases the P-wave is hidden in the QRS complex.



Lead II



Lead V1

The P-wave is sometimes seen after the QRS complex. It will present itself as "pseudo s" in lead II and "pseudo r" in lead V1.

# Types of atrioventricular node re-entrant tachycardia

B) Atypical AVNRT (fast-slow): 10% of all cases

---



P-wave before QRS complex

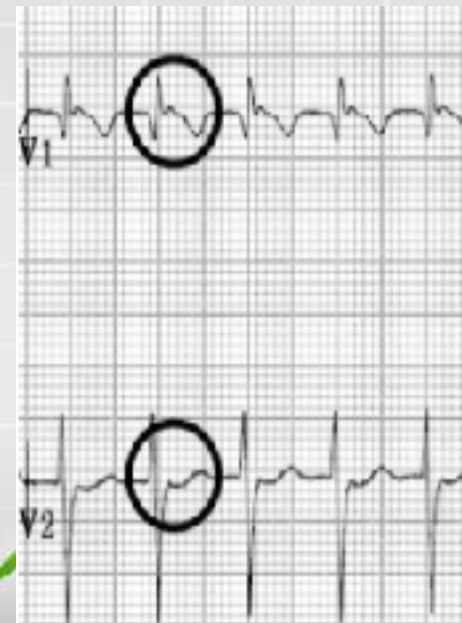
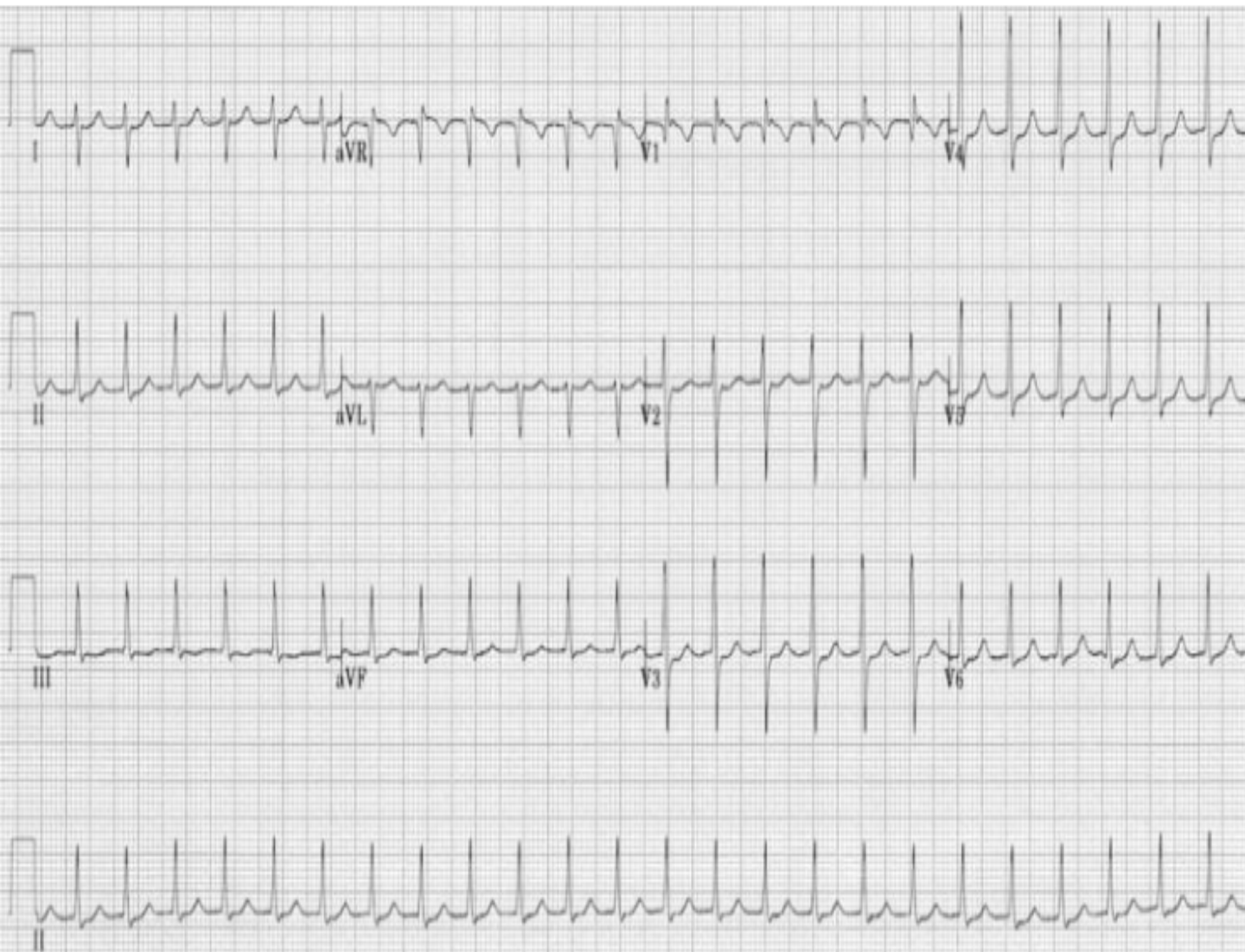C) Very atypical AVNRT (slow-slow): <1% of all cases

---

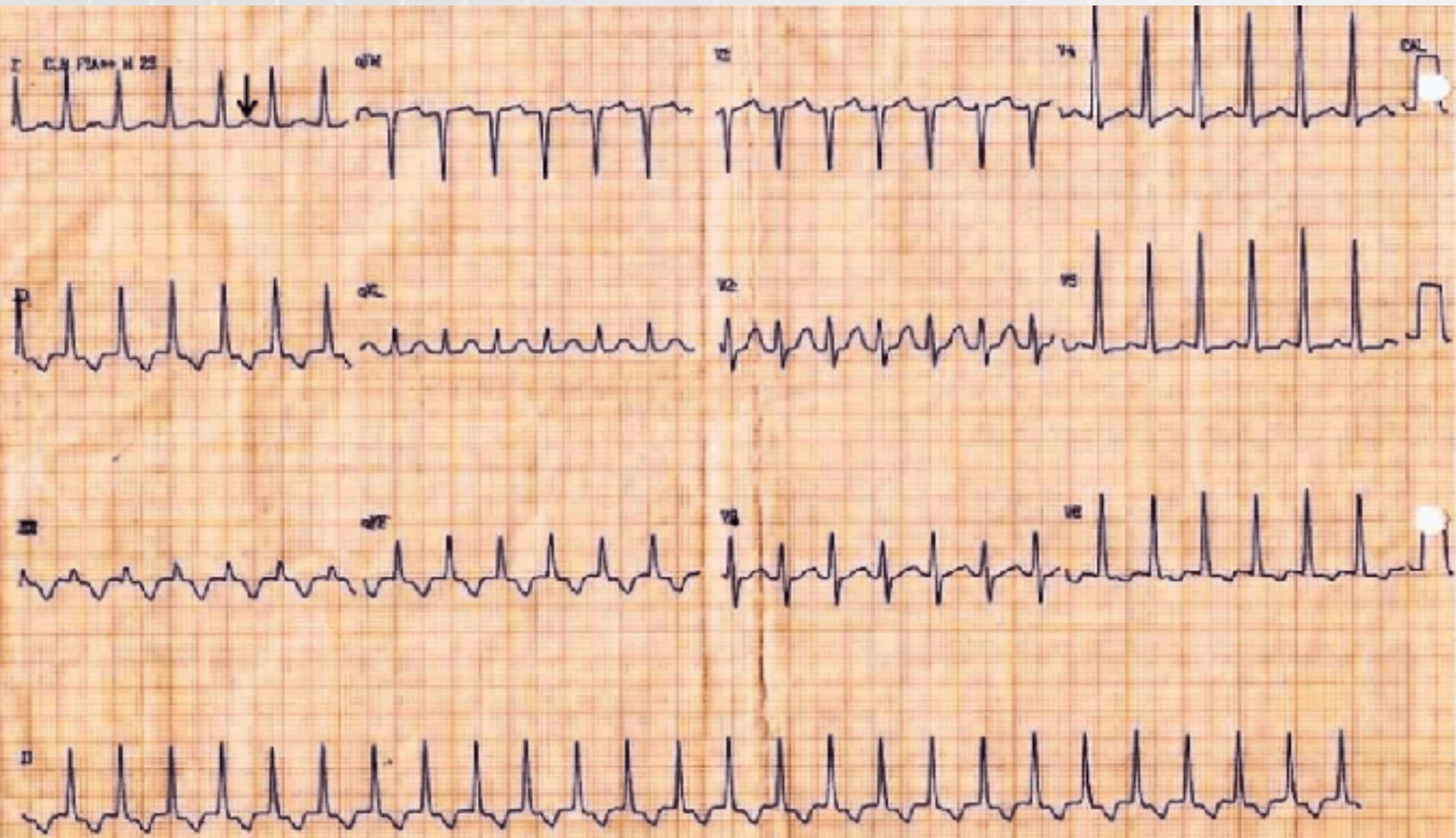


P-wave on the ST-T segment

# Atrioventricular nodal re-entrant tachycardia

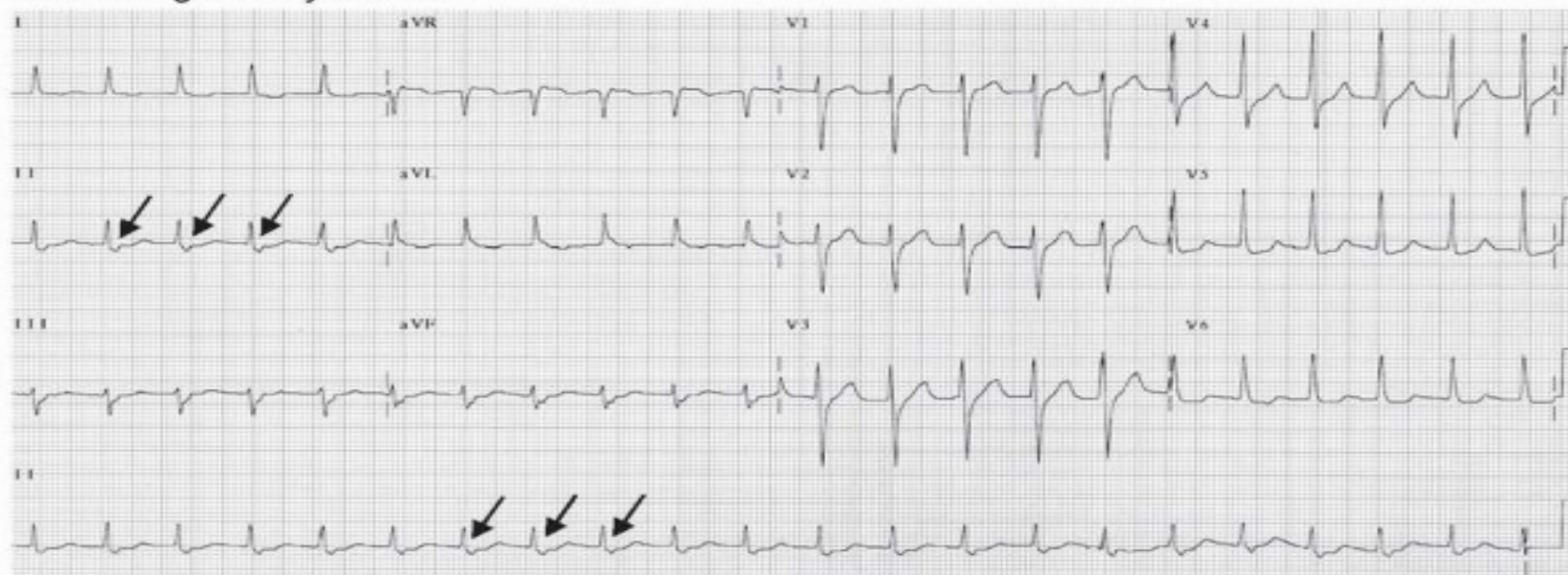


# Atrioventricular nodal re-entrant tachycardia

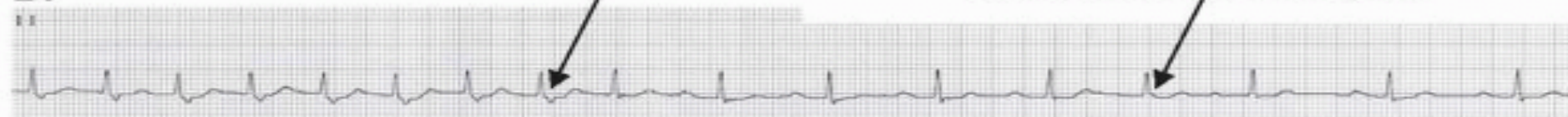


# Atrioventricular nodal re-entrant tachycardia

## A. During Tachycardia



## B.



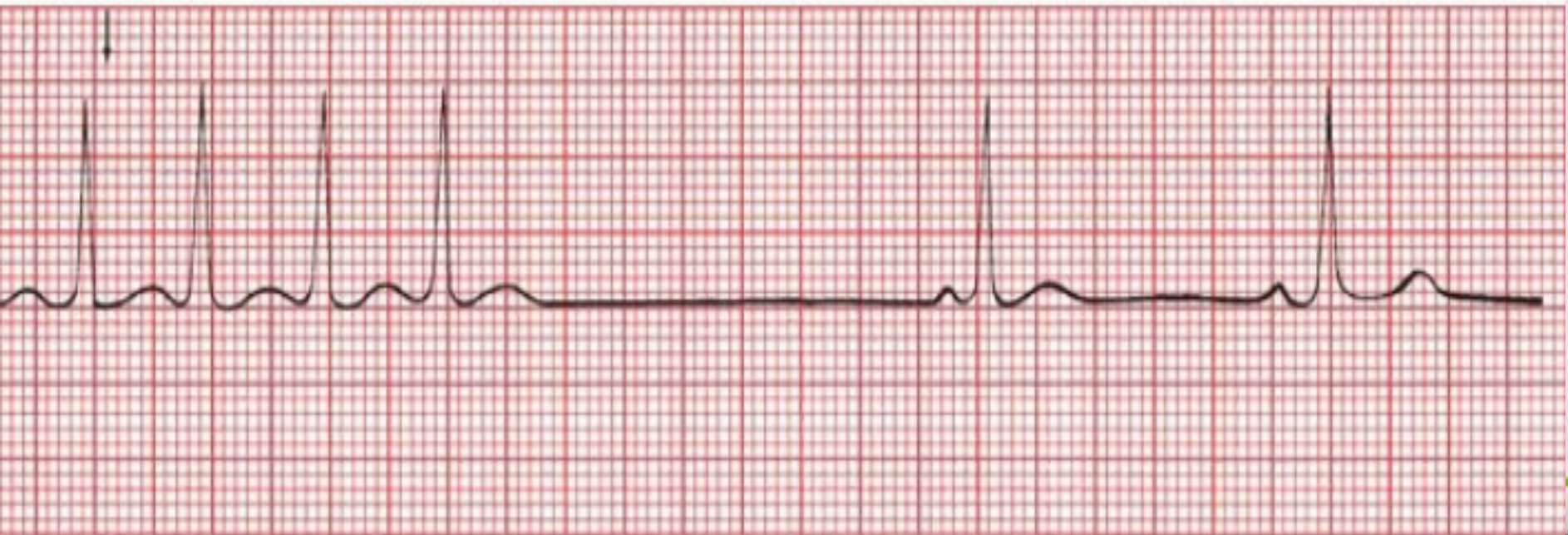# Treatment

- Vagal maneuvers and pharmacologic therapy are usually very effective in terminating the tachycardia.
- Vagal maneuvers: Vagal stimulation should be attempted as the initial therapeutic maneuver before any pharmacologic agent is given. The EKG should be recorded when vagal stimulation is performed because vagal stimulation is not only effective in terminating the tachycardia, but is also helpful as a diagnostic maneuver if the tachycardia turns out to be due to other arrhythmias.



- The most commonly used and most effective vagal maneuver in terminating SVT is carotid sinus pressure.

**Carotid massage begins**



# Ventricular Tachycardia

## Features that favor the diagnosis of ventricular tachycardia are:

- defined as  $\geq 3$  consecutive premature ventricular complexes
- with a QRS duration of  $> 0.12$  s (often  $\geq 0.14$  s) and a rate between 100 to 240 beats/min, exceptionally up to 300 beats/min, but generally 130–220 beats/min;
- RR interval is usually regular but may be irregular
- Abrupt onset and termination of arrhythmia is evident
- AV dissociation is common

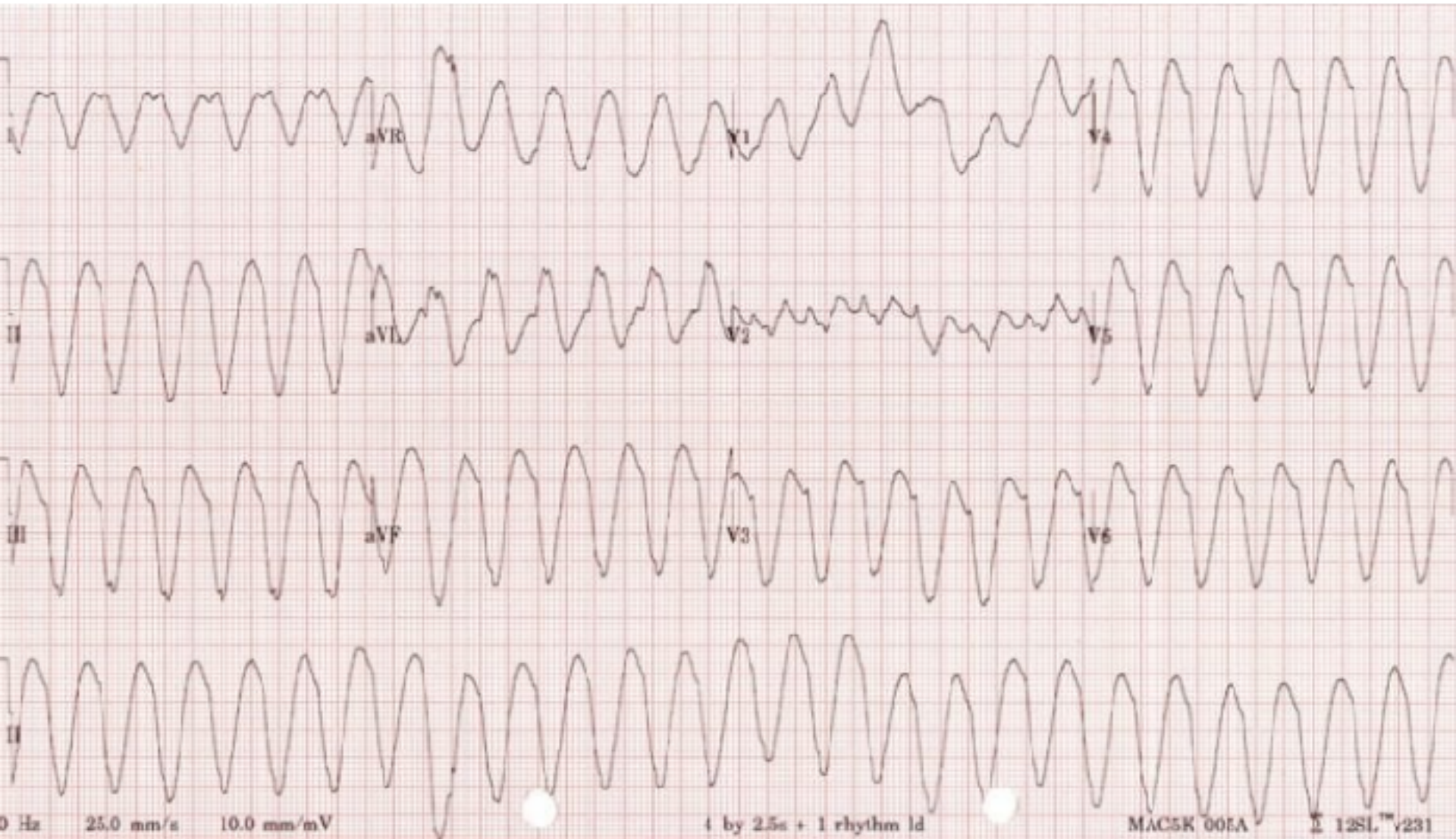
## Duration

- **Sustained** = Duration  $> 30$  seconds or requiring intervention due to hemodynamic compromise.
- **Non-sustained** = Three or more consecutive ventricular complexes terminating spontaneously in  $< 30$  seconds.





# Monomorphic VT



# Ventricular Tachycardia (VT)

## Clinical Presentation

- Haemodynamically **stable**.
- Haemodynamically **unstable** — e.g hypotension, chest pain, cardiac failure, decreased conscious level.

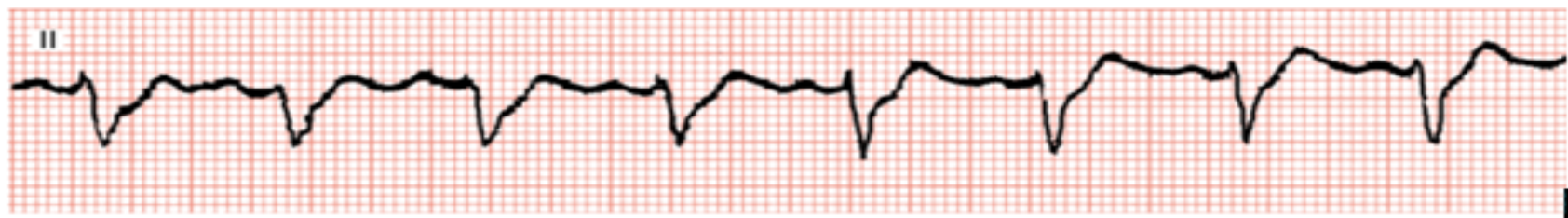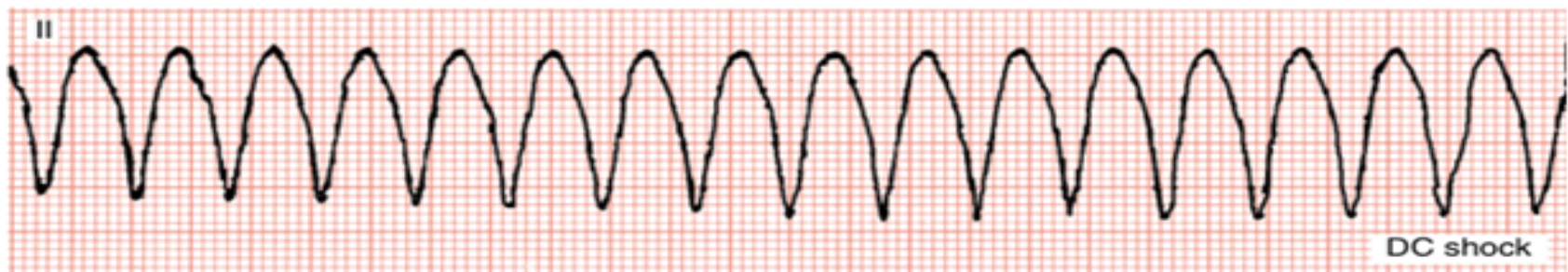VT associated with hemodynamyc instability are emergencies, presaging cardiac arrest and requiring immediate treatment.



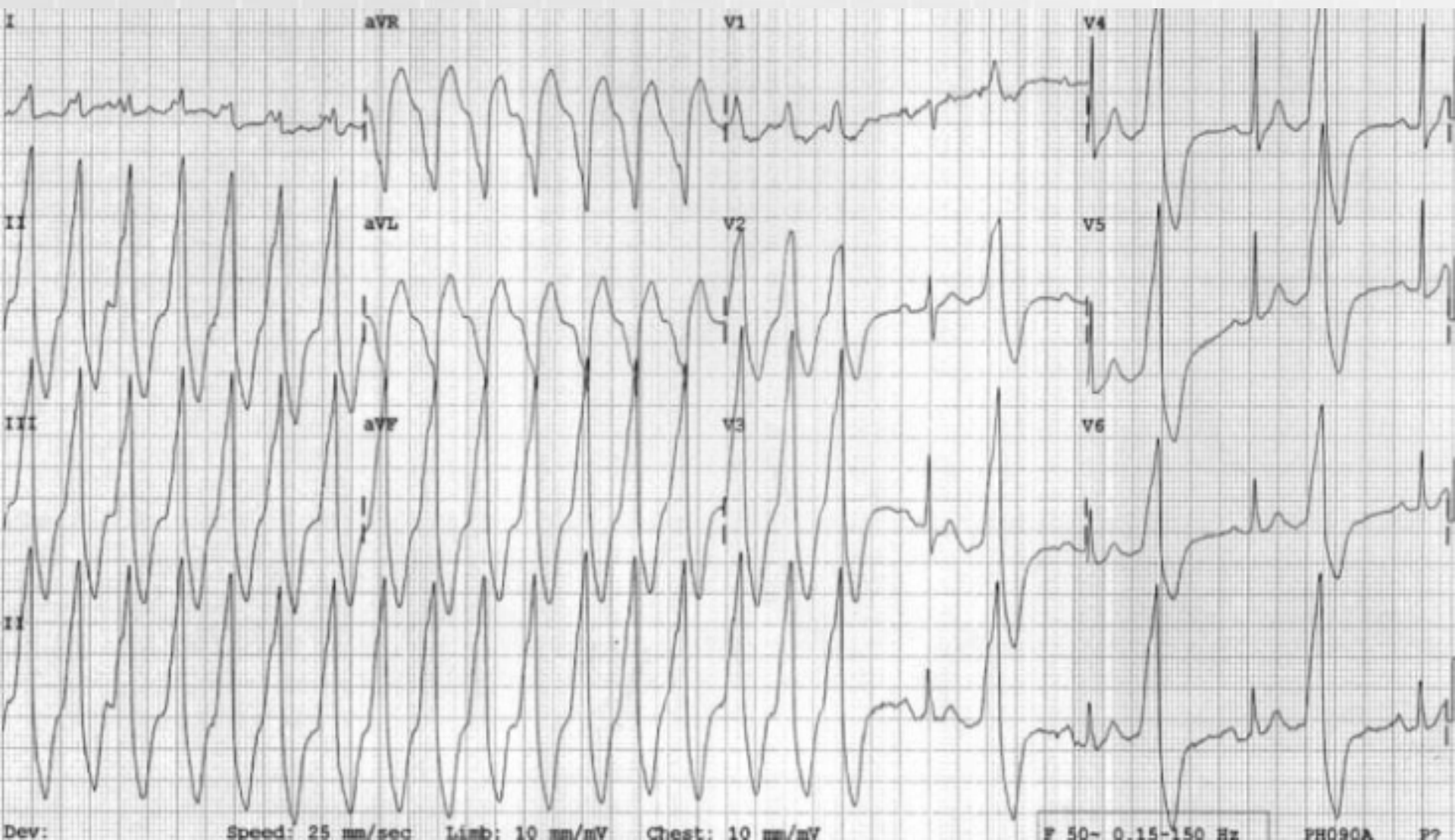
# Monomorphic VT

## Appearance (in any given lead)

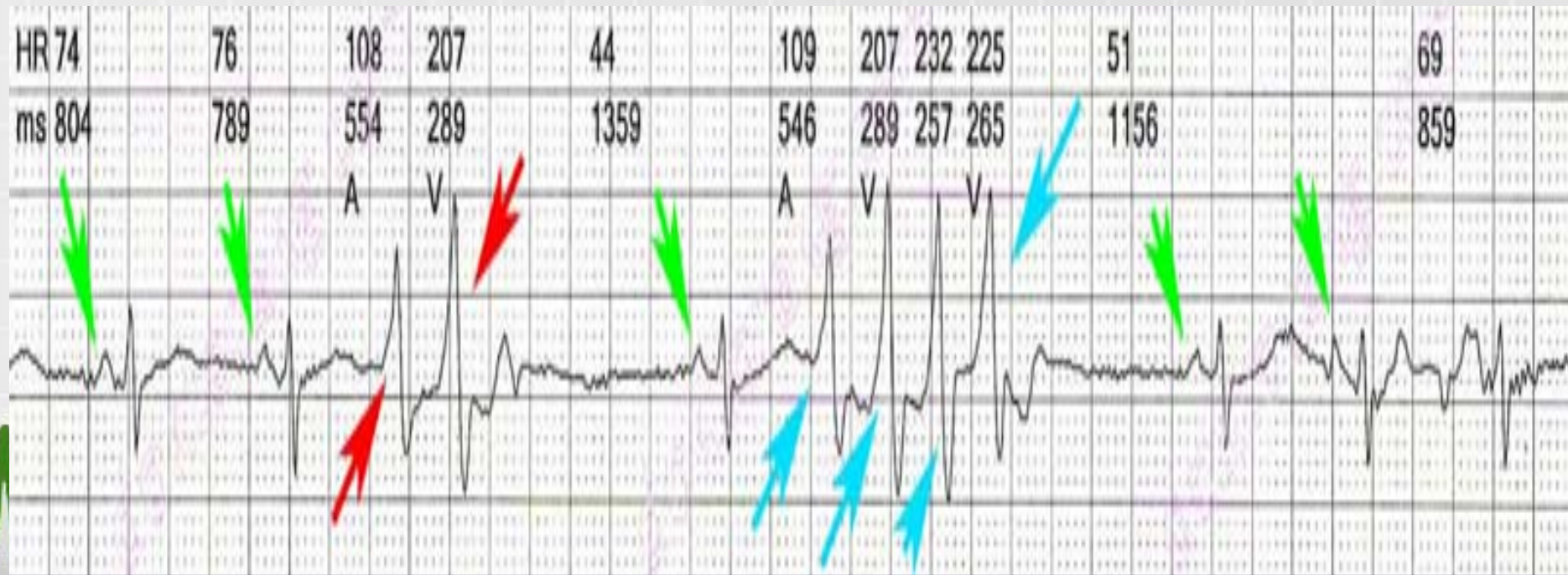
- Monomorphic: all QRS complexes look the same in a given lead
- Polymorphic: is characterized by phasic variation of the QRS complex amplitude and direction
- Monomorphic VT generally shows a left bundle-branch block -like or right bundle-branch block -like QRS pattern.



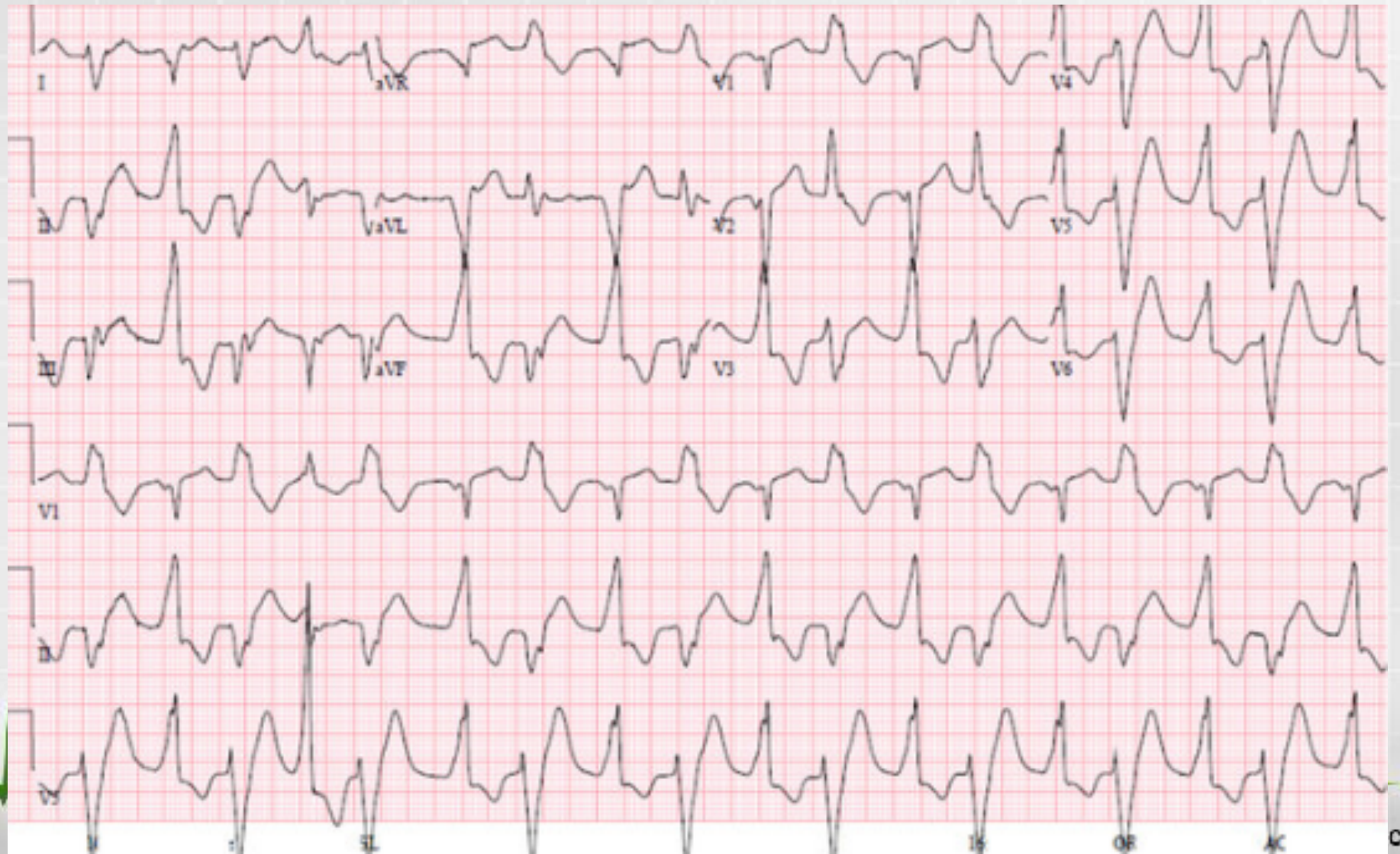
# Monomorphic VT



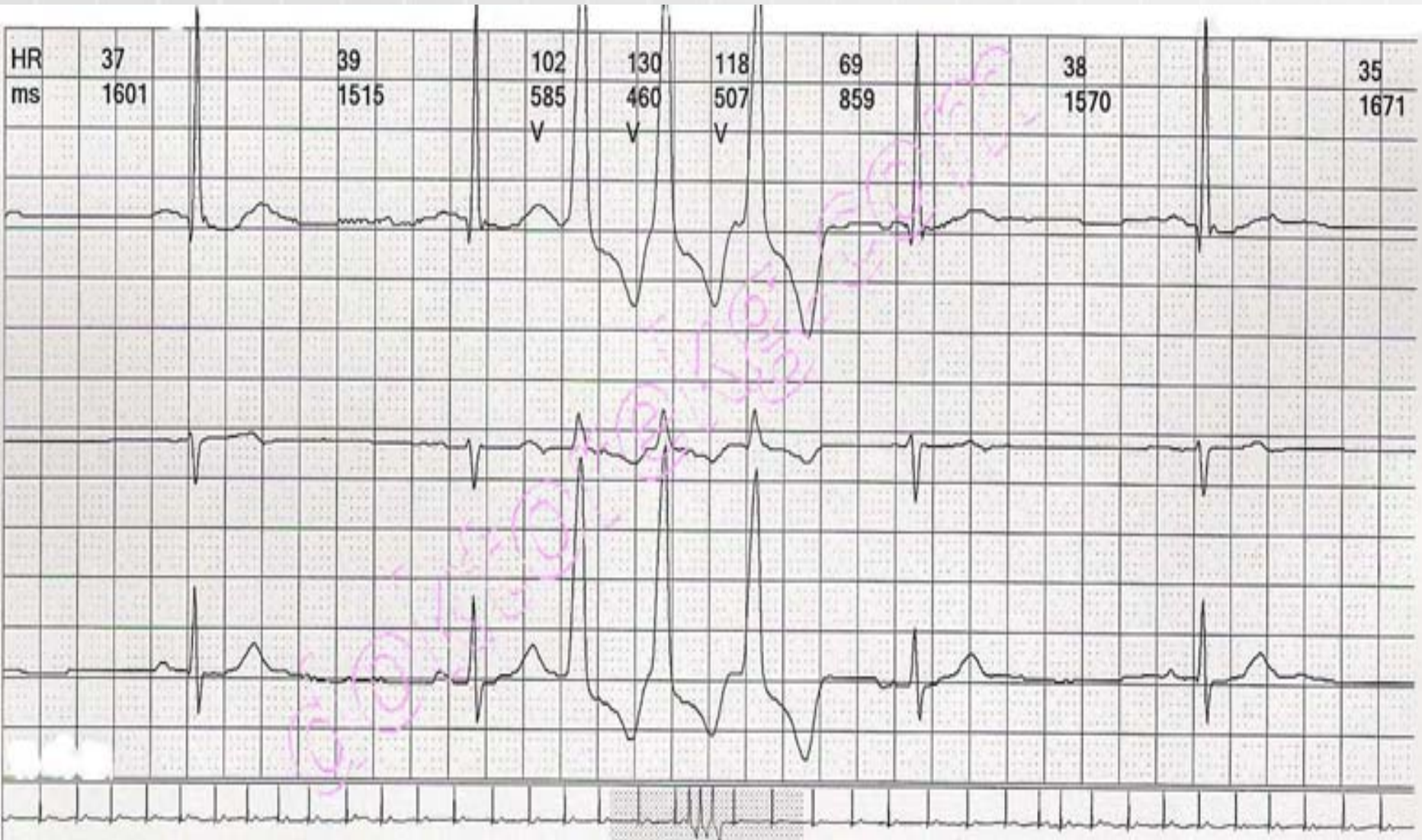
# Ventricular Tachycardia



# Polymorphic ventricular tachycardia




HR	37	39	102	130	118	69	38	35
ms	1601	1515	585	460	507	859	1570	1671
			V	V	V			



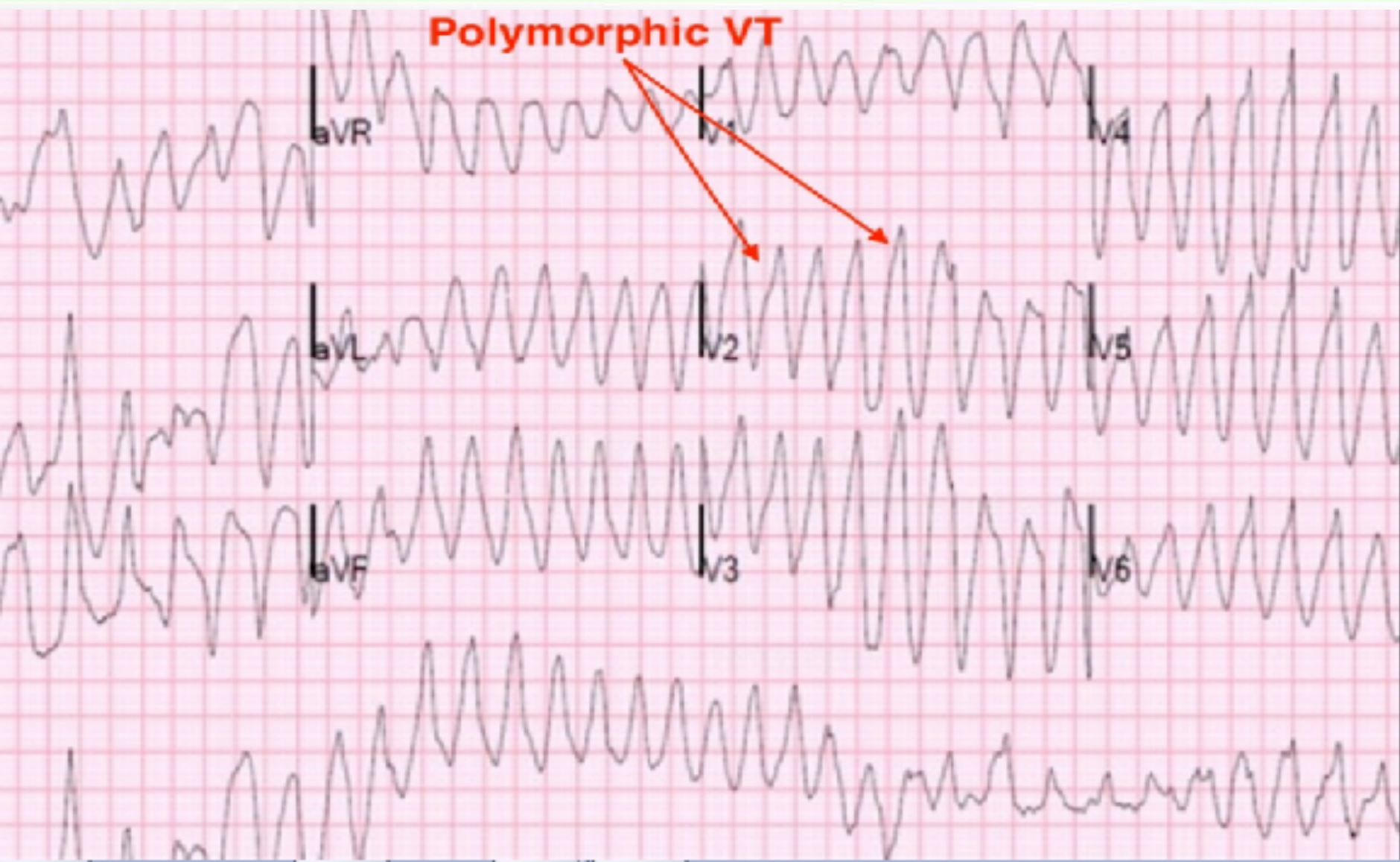
# Case Presentation

- A 43-year-old female with complains: multiple episodes of dizziness, shortness of breath, and palpitations.
- The patient's past medical history was positive for depression and substance abuse of hydrocodone dating back to 2007.
- The patient's husband denied any history of cardiac arrhythmias, structural heart disease, or ischemic heart disease.
- It was reported drug allergies to amoxicillin and erythromycin, also revealed recreational usage of loperamide at approximately 400 mg in the last 24 hours before the presentation.
- On physical exam consisted: pulse of > 200 b/ min, BP-157/80, respiratory rate at 24/min.
- The pulmonary exam - decreased breath sounds bilaterally with symmetrical chest wall expansion.
- The cardiovascular exam - tachycardia with no murmurs reported.
- In the processes of placing the EKG electrodes onto the patient, she became unresponsive and the two lead EKG monitors showed polymorphic VT with a HR- 220/ min and BP- 84/58 mmHg.





**Polymorphic VT**



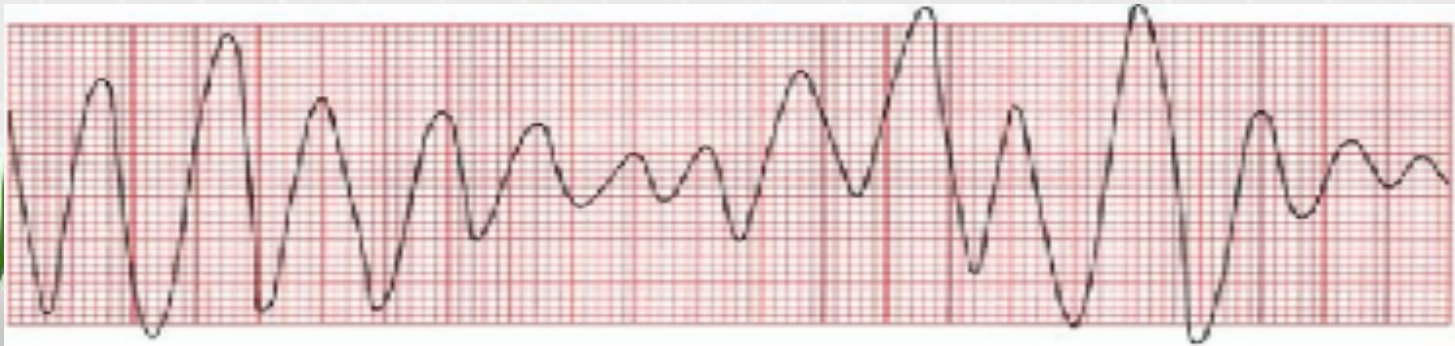
# Torsades de pointes

It is a unique form of ventricular tachycardia at the patients with prolonged QT intervals. It can be:

- Congenital
- Result from various electrolyte disturbances
- Develop during an acute myocardial infarction

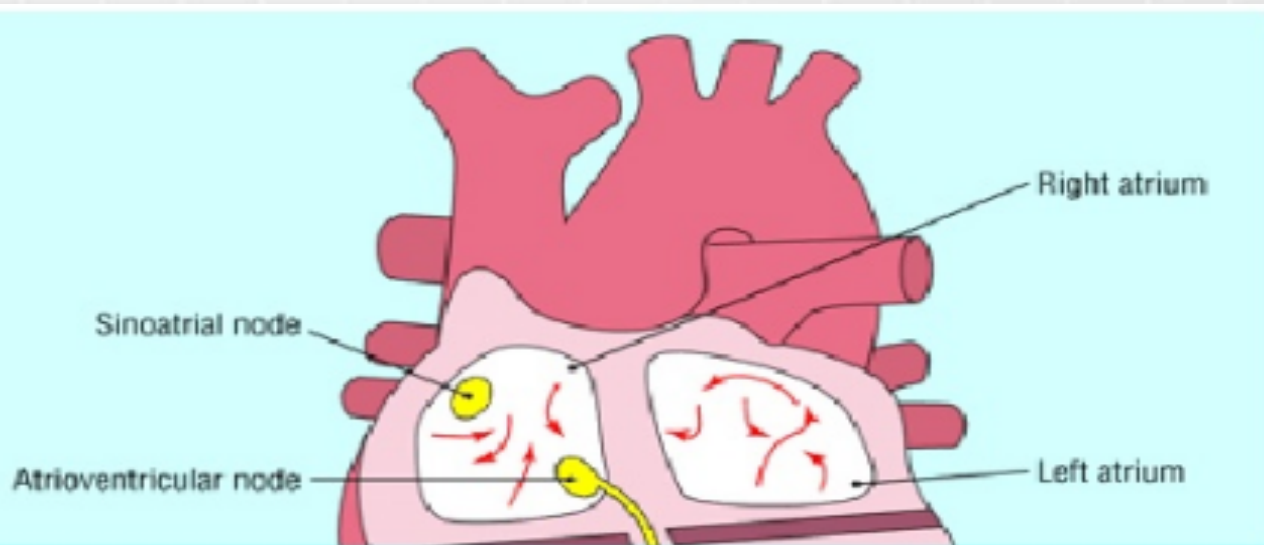
A prolonged QT interval is the result of prolonged ventricular repolarization. A PVC failing during the elongated T wave can initiate torsades de pointes.

Torsades des pointes looks just ordinary ventricular tachycardia, except QRS complexes spiral around the baseline, changing their axis and amplitude.



# Atrial fibrillation

- Chaotic, disorganized excitation and contractions of atrial fibers (rapid irregular twichings) at a rate of 350-600 bpm (without effective atrial contraction).
- Is caused by multiple reentrant circuits or wavelets of activation sweeping around atrial myocardium.

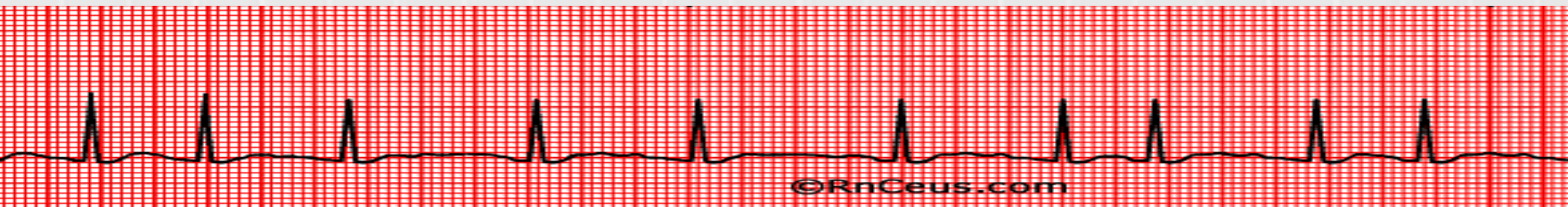


# Atrial fibrillation

- The most common and clinically significant sustained arrhythmia in the general population.

## **Causes:**

- high incidence of underlying cardiovascular disorders (hypertension, metabolic syndrome, mitral valve disease, coronary artery disease)
- Obesity, alcoholism
- Obstructive sleep apnea
- Thyrotoxicosis
- emotional stress or following surgery



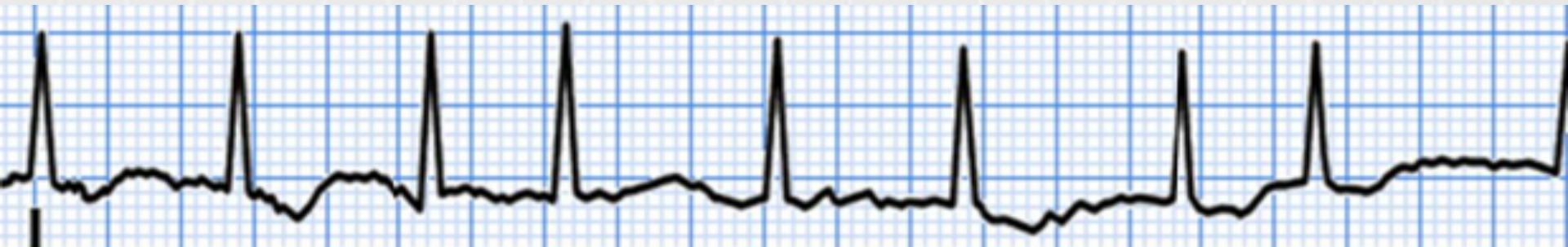
# Types of AF

AF pattern	Definition
First diagnosed AF	AF that has not been diagnosed before, irrespective of the duration of the arrhythmia or the presence and severity of AF-related symptoms.
Paroxysmal AF	Self-terminating, in most cases within 48 hours. Some AF paroxysms may continue for up to 7 days. <sup>2</sup> AF episodes that are cardioverted within 7 days should be considered paroxysmal. <sup>2</sup>
Persistent AF	AF that lasts longer than 7 days, including episodes that are terminated by cardioversion, either with drugs or by direct current cardioversion, after 7 days or more.
Long-standing persistent AF	Continuous AF lasting for $\geq 1$ year when it is decided to adopt a rhythm control strategy.
Permanent AF	AF that is accepted by the patient (and physician). Hence, rhythm control interventions are, by definition, not pursued in patients with permanent AF. Should a rhythm control strategy be adopted, the arrhythmia would be re-classified as 'long-standing persistent AF'.



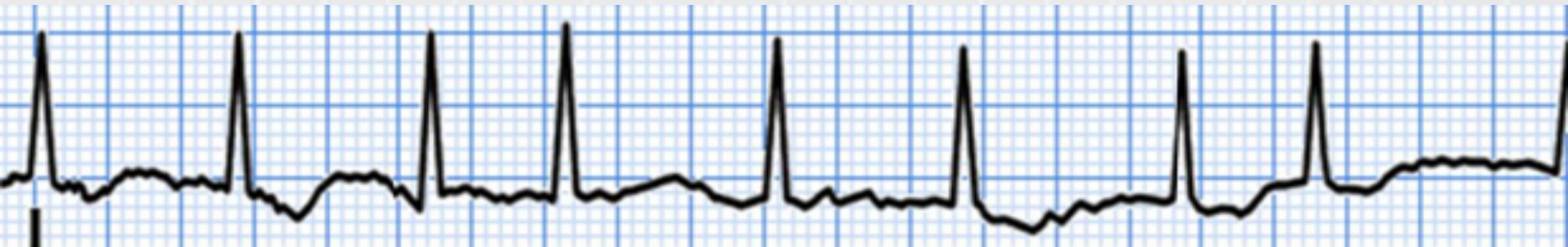
# ECG criteria of atrial fibrillation

- P waves are absent in all leads
- Multiple oscillating baseline 'f waves (fibrillation) of various amplitude and shape are recorded instead of P waves (usually best seen in the leads II, III, aVF, V1 and V2).
- RR intervals are of various duration (irregular ventricular rhythm)
- QRS complex are not changed



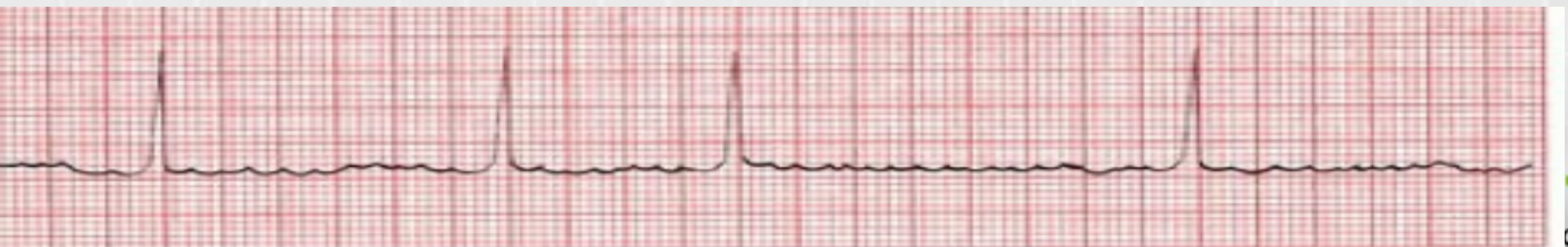# Clinical forms of atrial fibrillation

1. The ventricular rate may be normal - 60-90 bpm
2. Tachyarrhythmia-the ventricles are contracted with the rate  $> 100$ bpm
3. Bradyarrhythmia -the ventricles are contracted with the rate  $< 60$  bpm



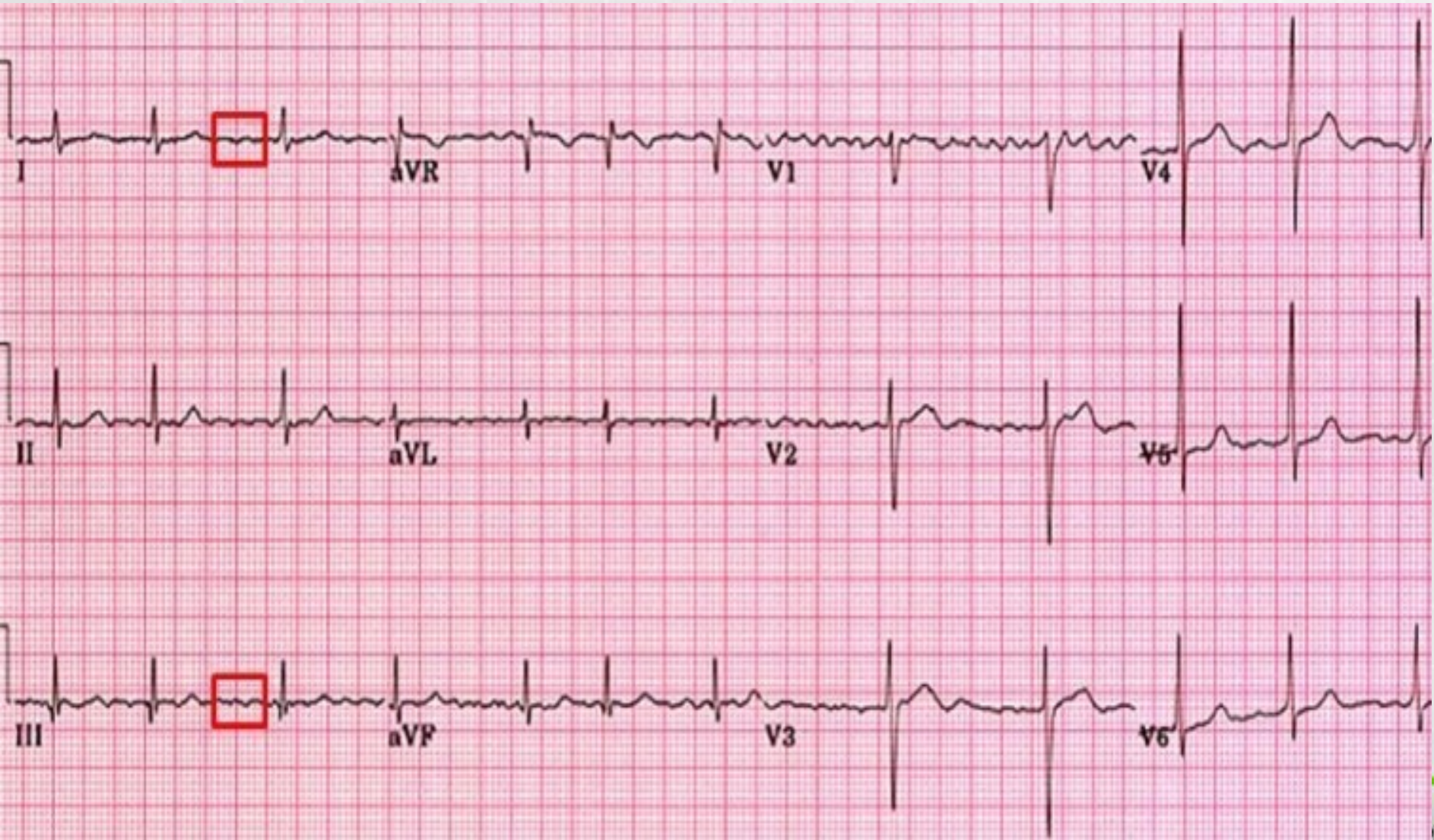
# Atrial fibrillation

- It causes minimal hemodynamic compromise and often the patient presents complaining of palpitations as the only symptom.
- Although hemodynamic compromise is minimal, atrial fibrillation is an important risk factor for the development of thromboembolic complications, such as strokes and transient ischemic attack.

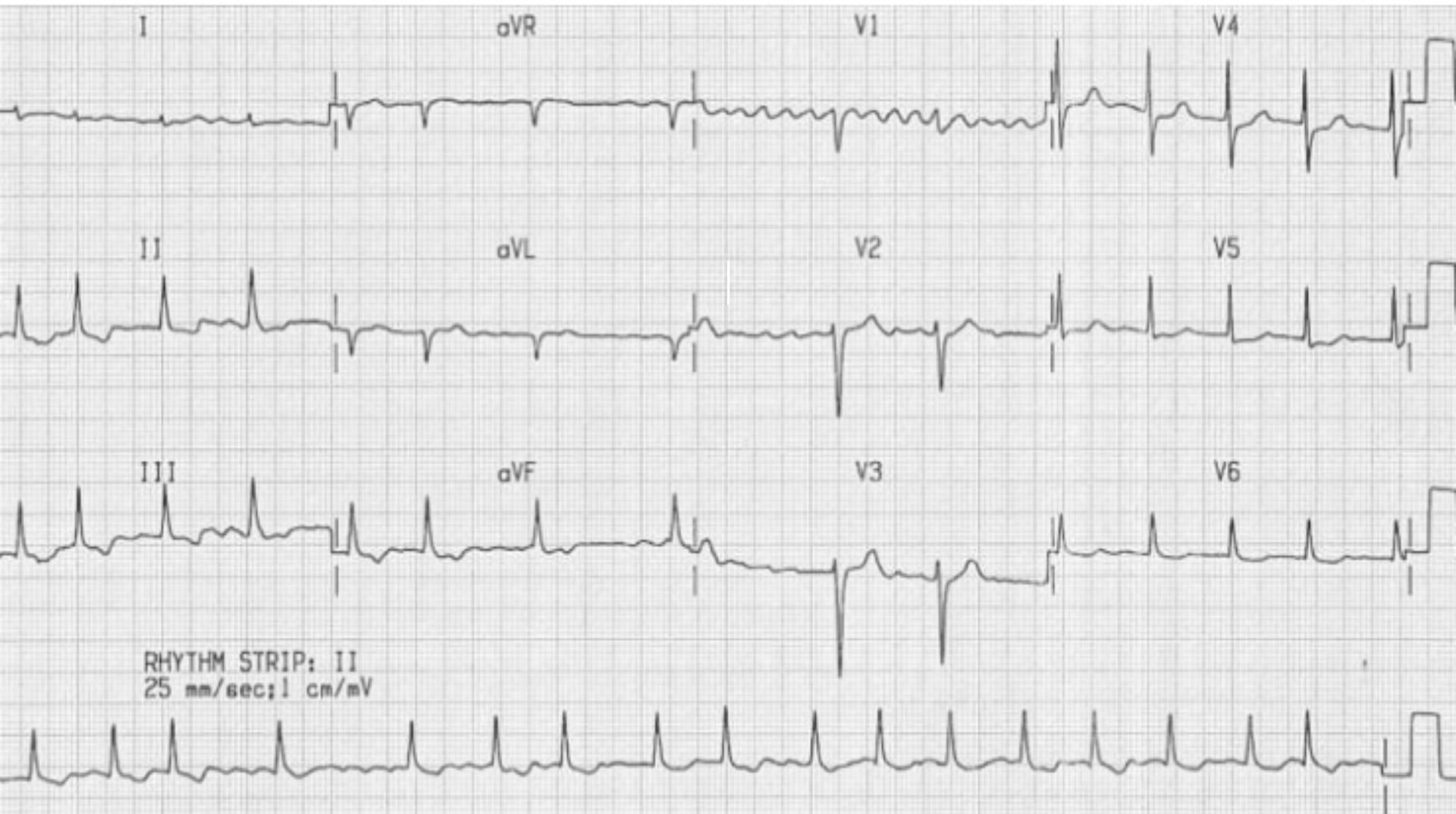


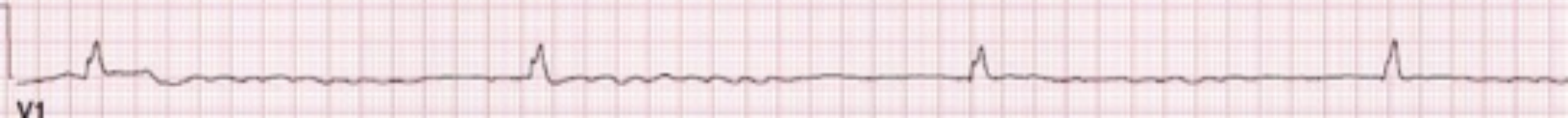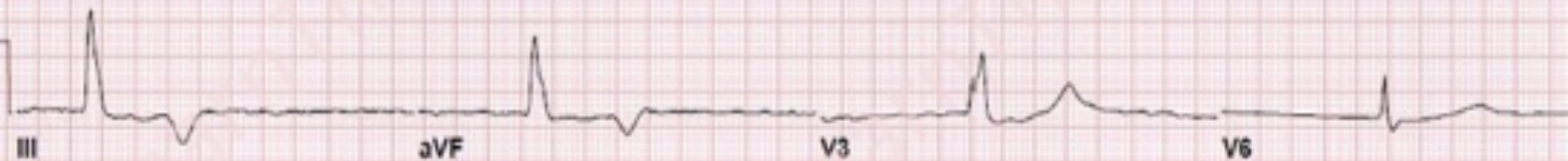




# Atrial fibrillation

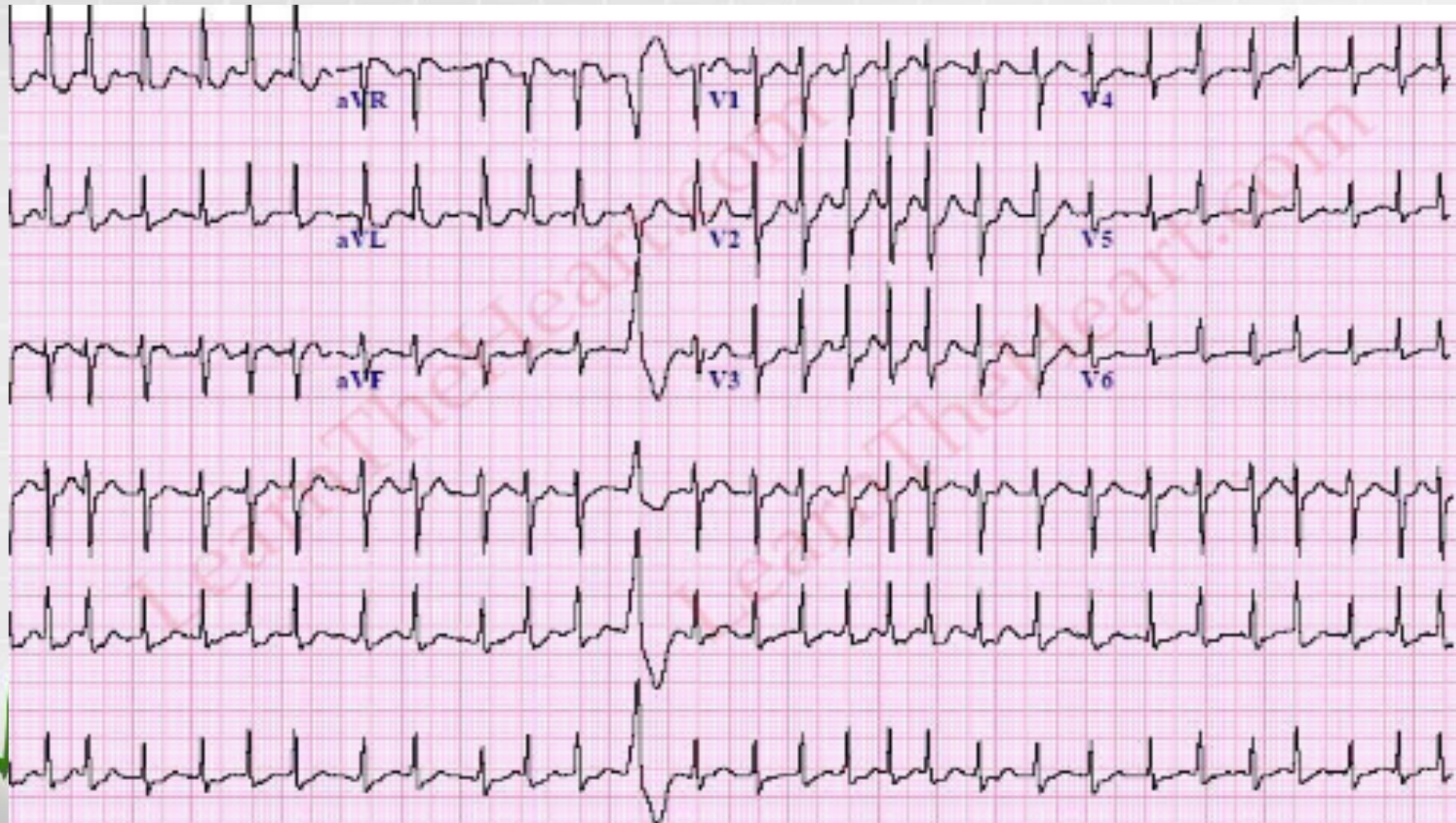


# Atrial fibrillation



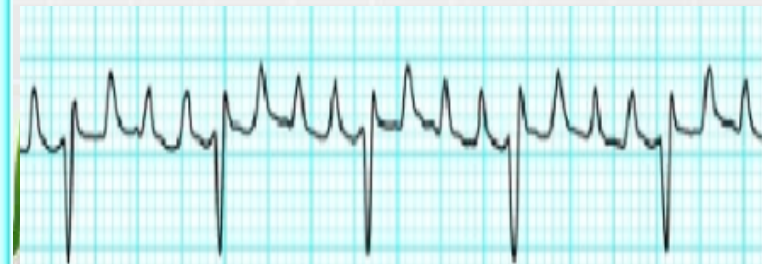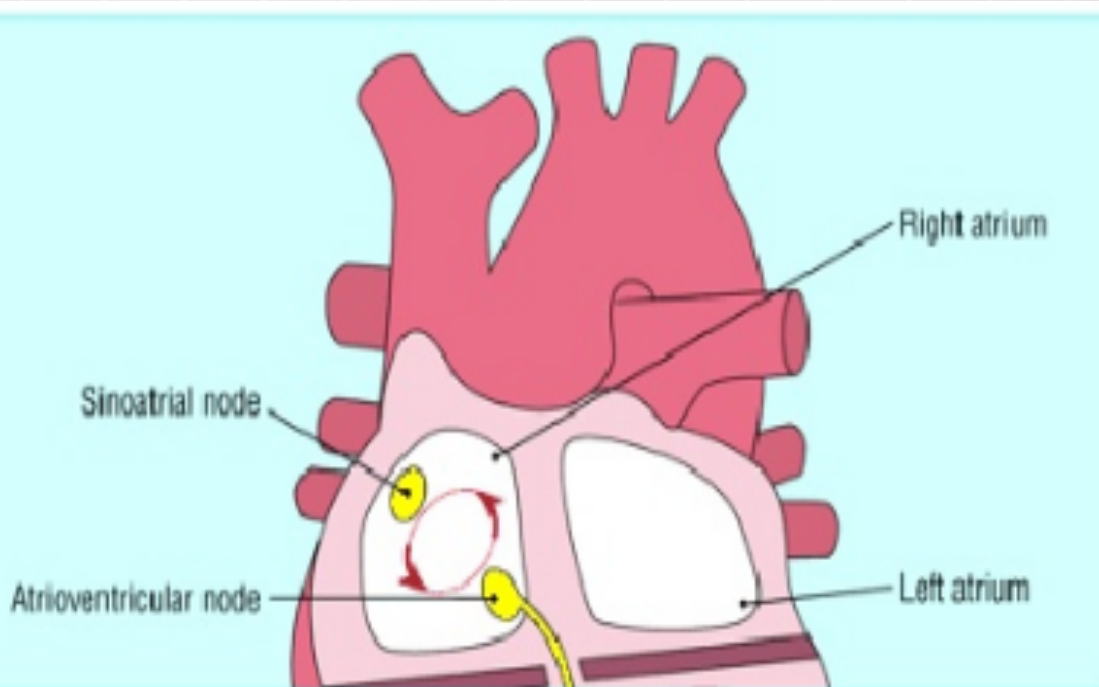


# Atrial fibrillation



# Atrial Flutter

- occurs when a “reentrant” circuit is present, causing a repeated loop of electrical activity to depolarize the atrium at a rate of about 250 to 350 beats per minute; remember the atrial rate in atrial fibrillation is 400 to 600 bpm.



# Atrial Flutter

Typically, a person with AF doesn't feel the fluttering of their heart. Symptoms often manifest in other ways.

Some of them include:

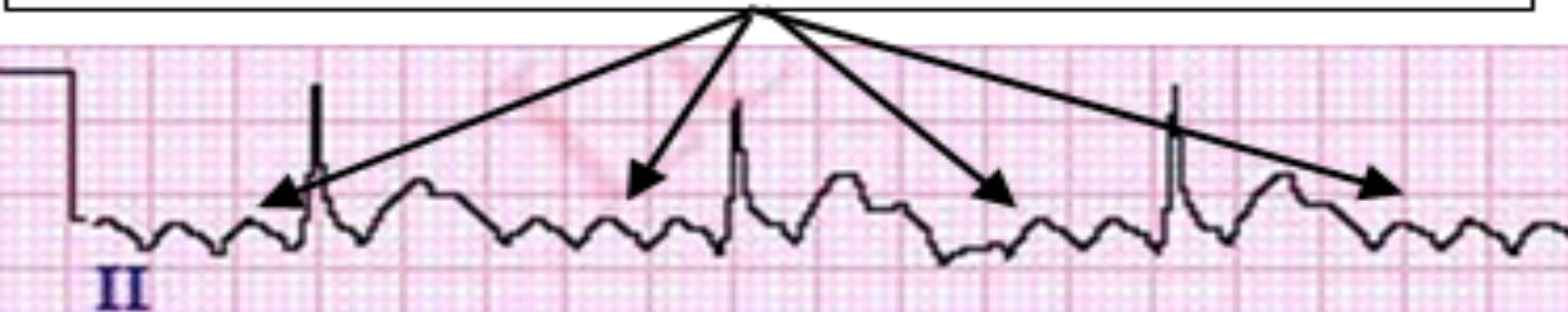- fast heart rate
- shortness of breath
- feeling lightheaded or faint
- pressure or tightness in the chest
- dizziness or lightheadedness
- [heart palpitations](#)
- trouble doing everyday activities because of fatigue



# Atrial Flutter

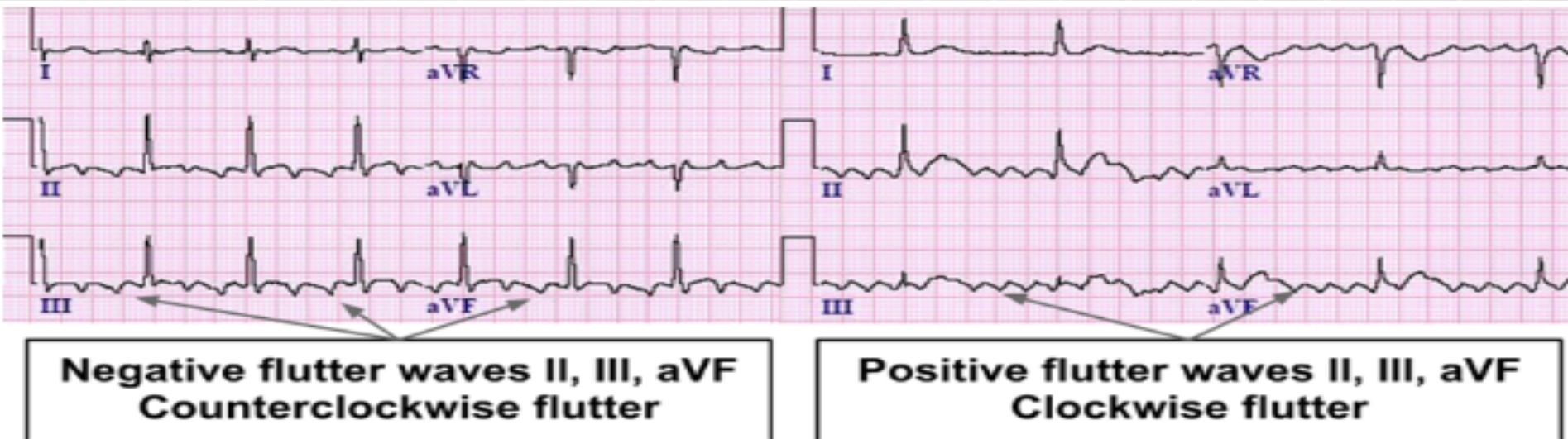
- P waves are absent
- Rhythm can be regular or irregular
- The baseline continually rises and falls, producing *flutter waves* instead of P waves (*saw-toothed pattern*), usually best seen in leads II, III, aVF, V1, V2
- QRS complex is not changed
- RR intervals are equal in duration

## Atrial Flutter – Sawtooth pattern



# Atrial Flutter

- Atrial flutter can be described as “typical” (type I) or “atypical” (type II) based on the anatomic location from which it originates. Also, atrial flutter can be described as “clockwise” or “counterclockwise” depending on the direction of the circuit.



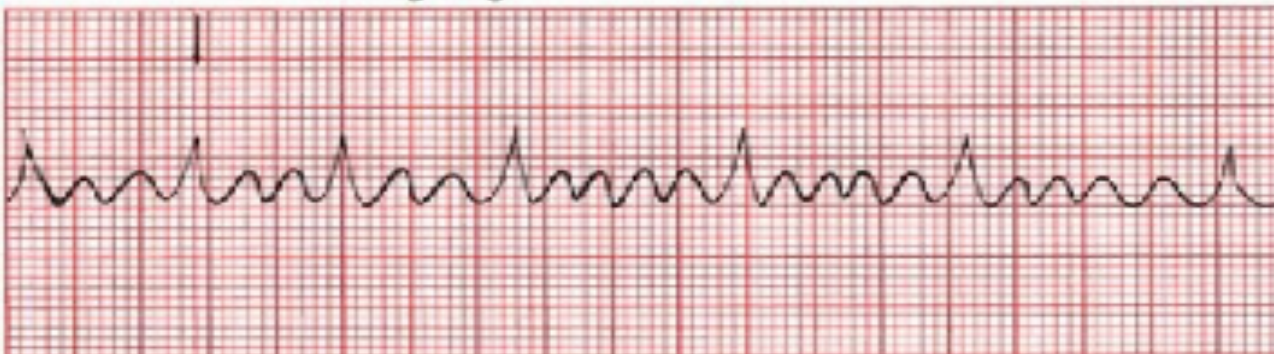

# Atrial Flutter

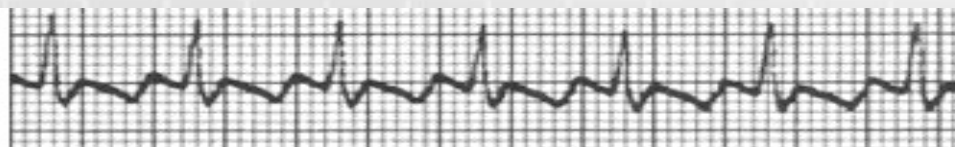
- The AV node can't handle the extraordinary number of atrial impulse bombarding it and it doesn't have time to repolarize in time for each ensuing wave, and not all of the atrial impulses pass through the AV node to generate QRS complexes. This is called- *AV block*.
- The most common is: *AV block 2:1*
- For every 2 visible flutter waves, one passes through the AV node to generate a QRS complex, and one does not.

Carotid massage increases the block from 3:1 to 5:1. P waves are invisible, hidden within the large QRS complex

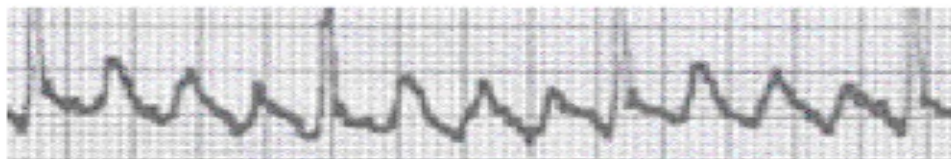
Carotid massage begins



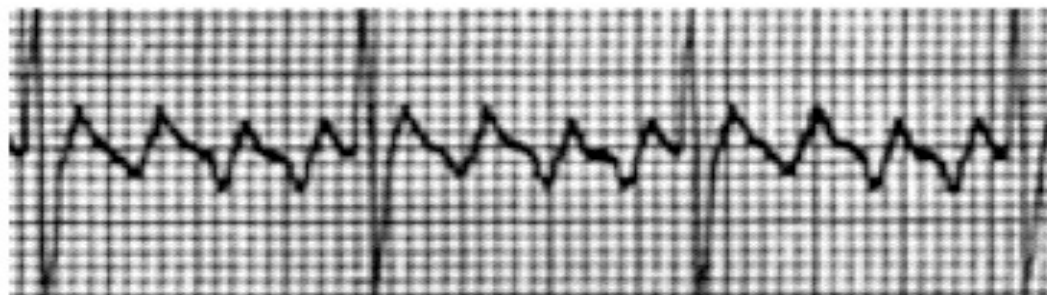
# Atrial Flutter




Atrial Flutter with 2:1 AV Conduction



Atrial Flutter with 3:1 AV Conduction

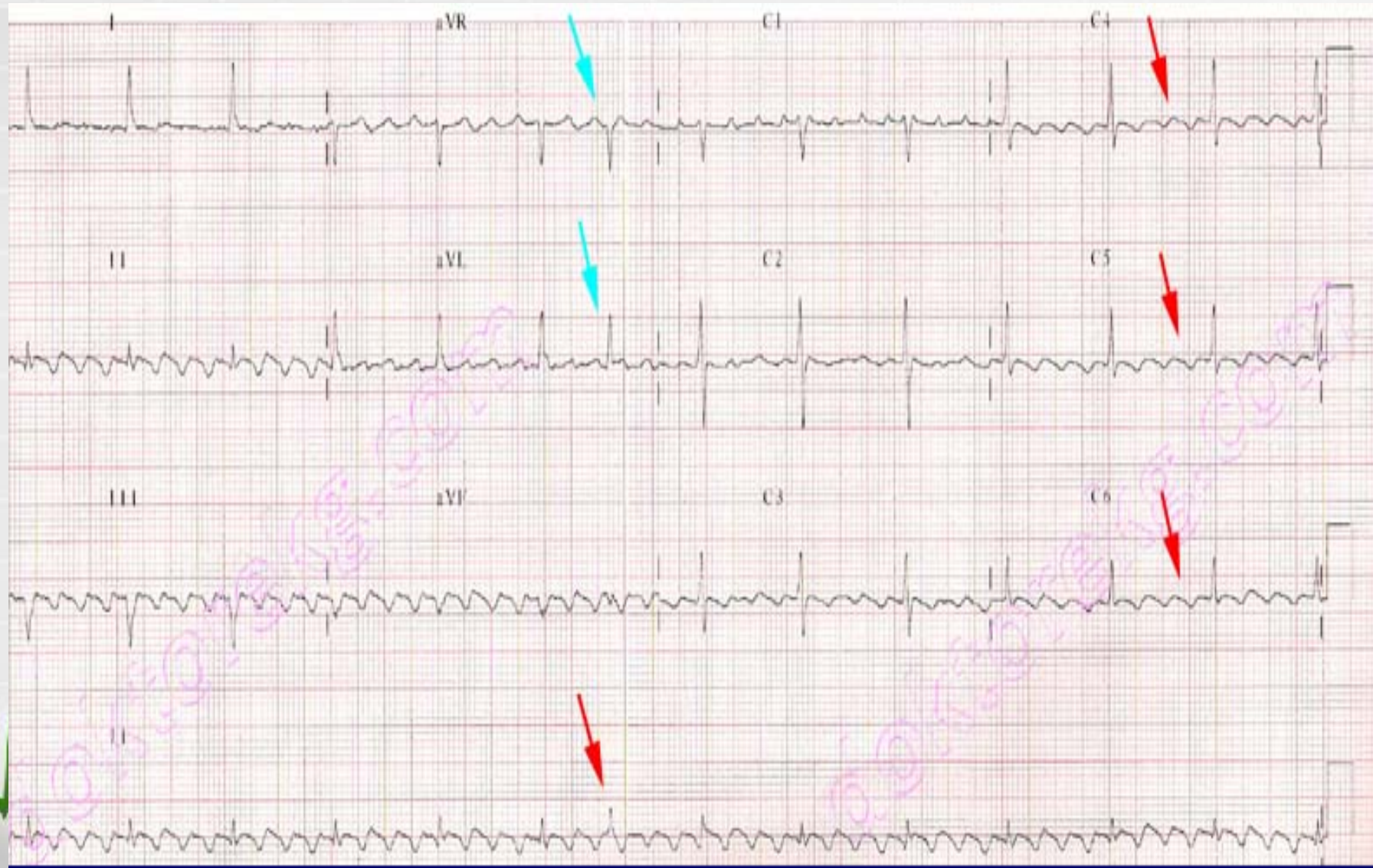


Atrial Flutter with 4:1 AV Conduction

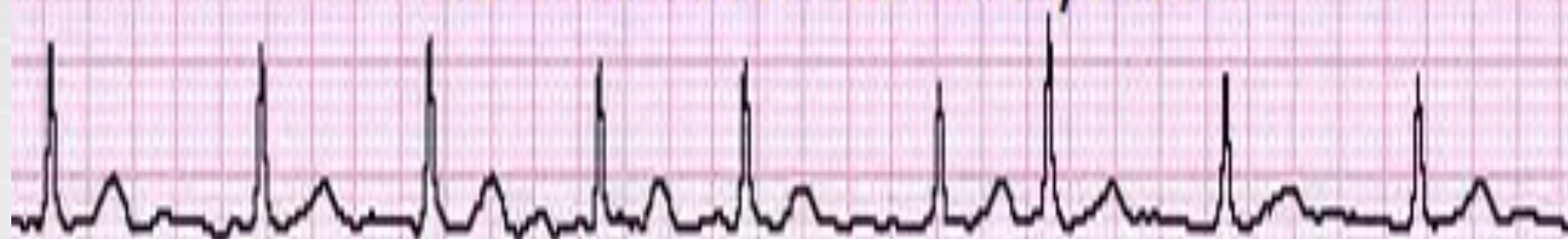


Atrial flutter with **Variable AV conduction**

# Atrial Flutter

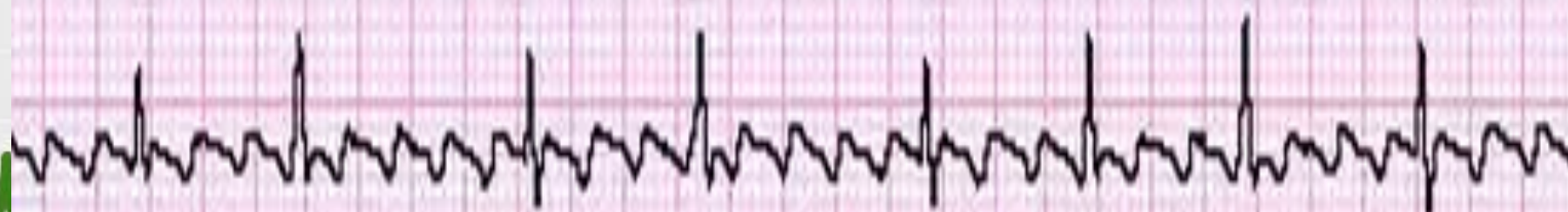

### Atrial Fibrillation - fibrillatory waves



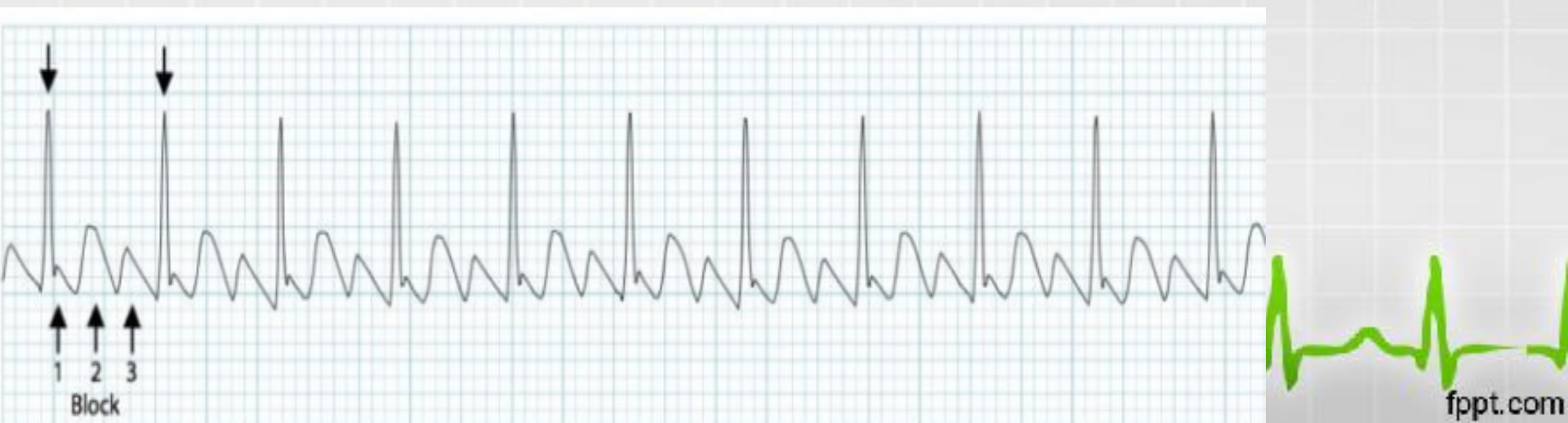
II

### Atrial Flutter - sawtooth pattern



II

# Atrial Flutter



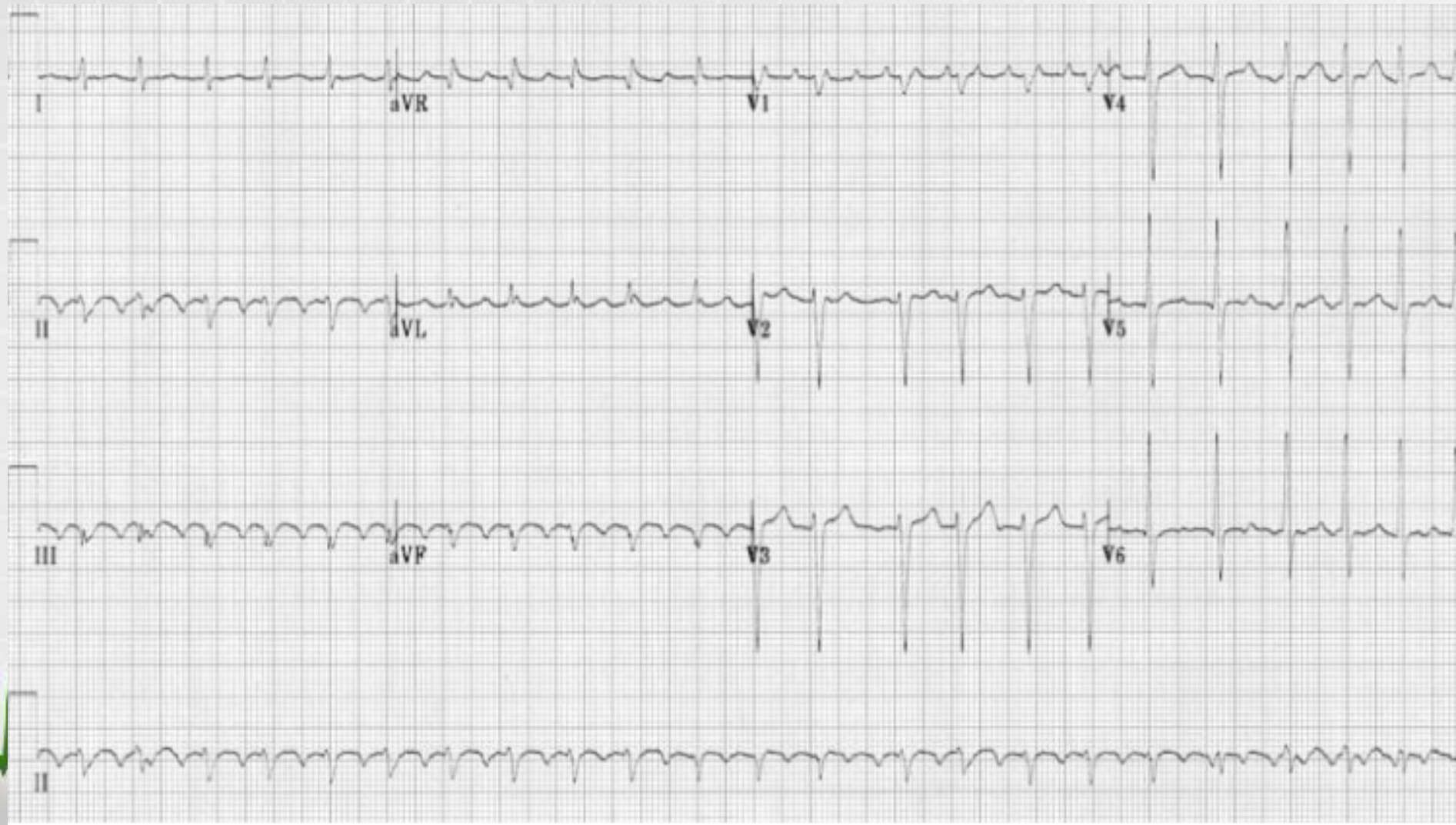
# Atrial Flutter

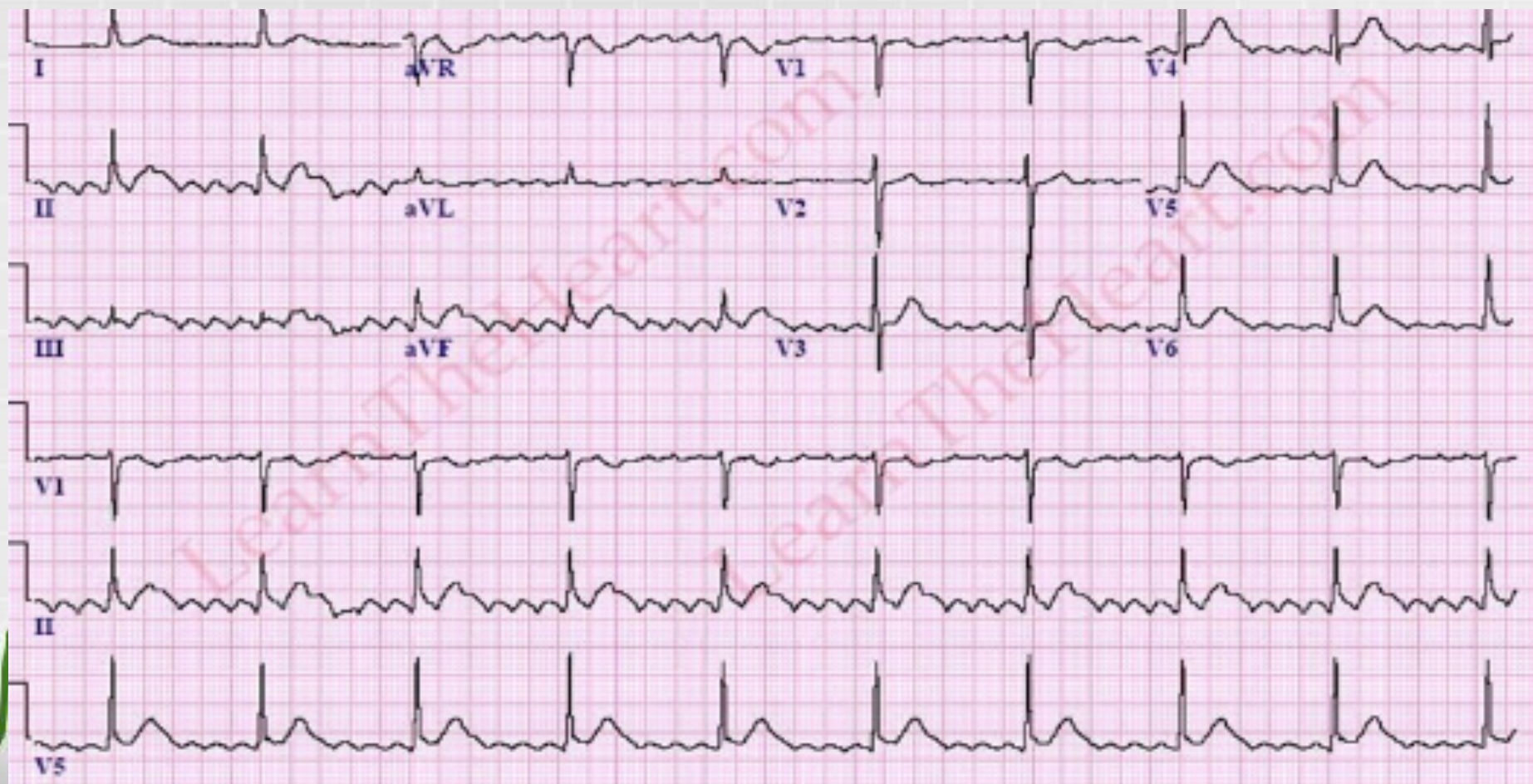
## **Common conditions associated with atrial flutter include the following:**

- Hypertension, obesity, diabetes mellitus, electrolyte imbalances, alcohol intoxication, drug abuse, particularly cocaine and amphetamines, pulmonary disease (chronic obstructive pulmonary disease and pulmonary embolism), thyrotoxicosis, various underlying cardiac conditions, both congenital ( atrial septal defect) and acquired ( rheumatic valvular disease, coronary artery disease, and congestive heart failure).



# Atrial Flutter







# Ventricular Fibrillation

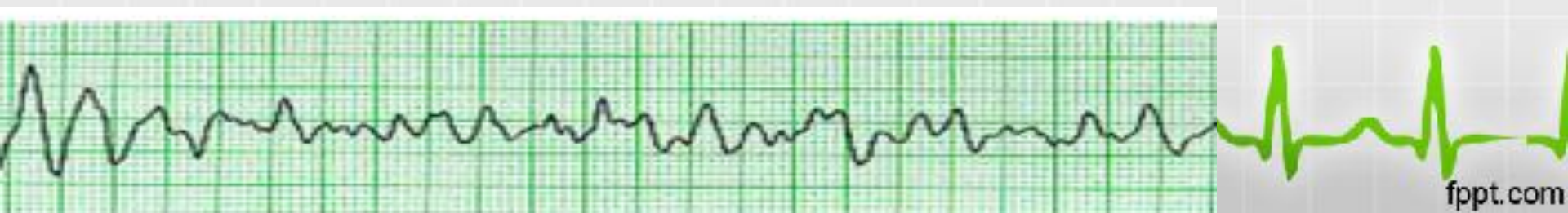- Ventricular fibrillation is often a fatal arrhythmia.
- It occurs when the ventricular rate exceeds 400.
- In this setting, virtually no forward cardiac output occurs.

Advanced Cardiac Life Support should be instituted immediately, including emergent electrical cardioversion.

This is frequently accomplished using an automated external defibrillator.

- Ventricular fibrillation is the main cause of sudden death in patients with myocardial infarction.

Implantable cardioverter defibrillators are recommended in certain situations to abort sudden cardiac death from ventricular fibrillation.

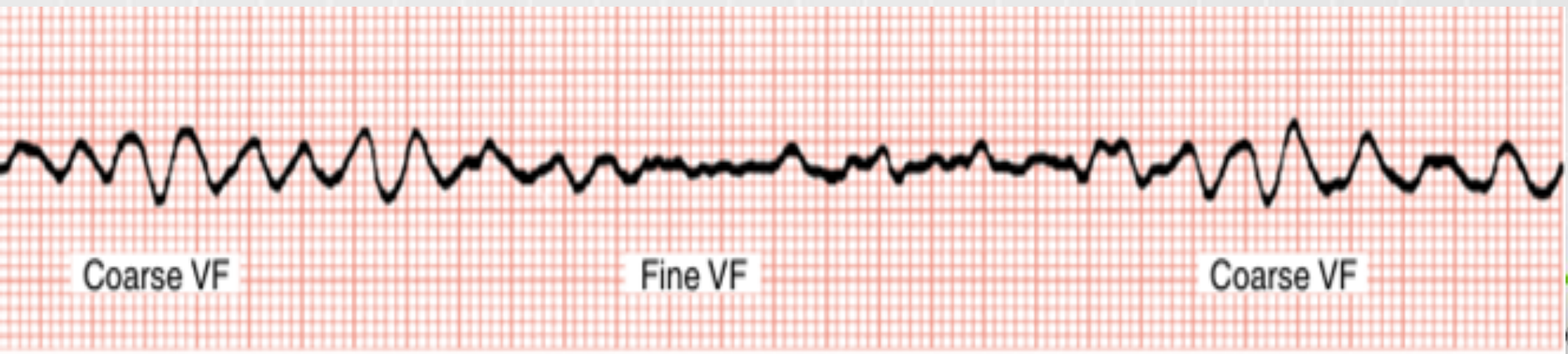


# Ventricular Fibrillation

- It is the most frequently encountered arrhythmia in adults who experience sudden death.

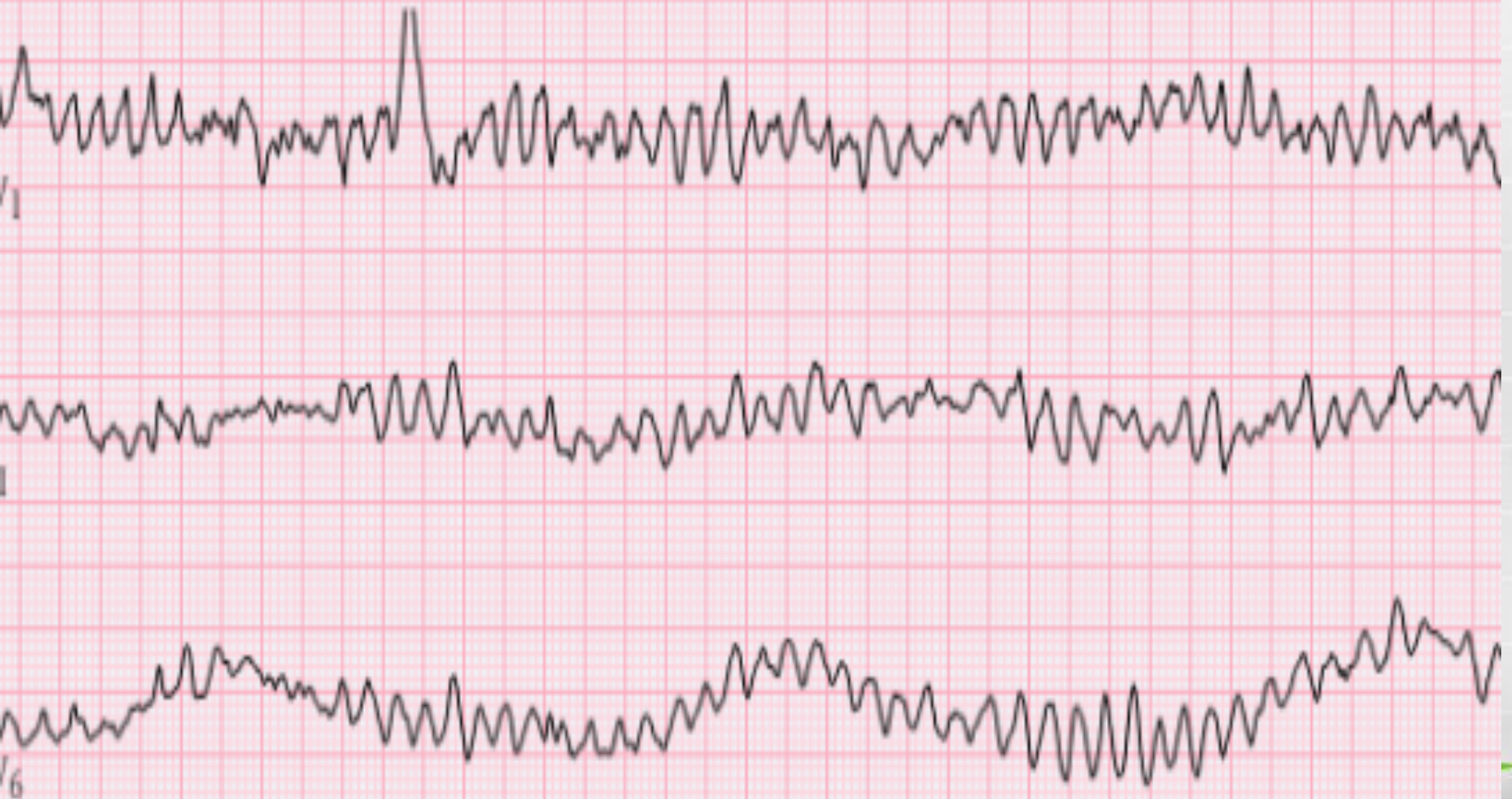
Based on the amplitude of fibrillatory waves VF is arbitrarily classified as:

- coarse ventricular fibrillation
- fine ventricular fibrillation (undulates gently)



# Ventricular Fibrillation

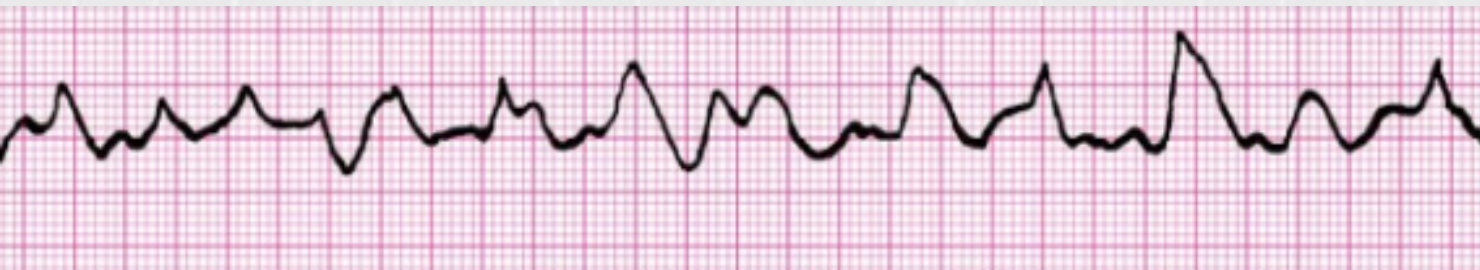Courtesy of Jason E. Roediger, CCT, CRAT



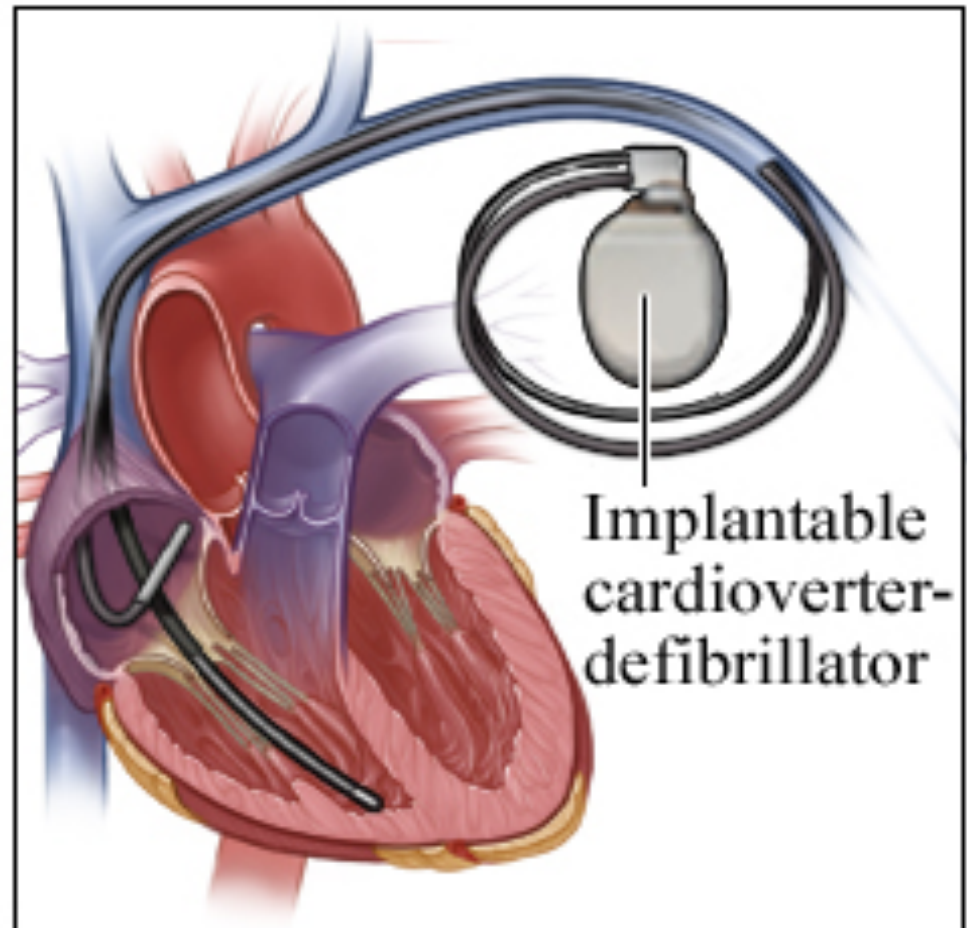
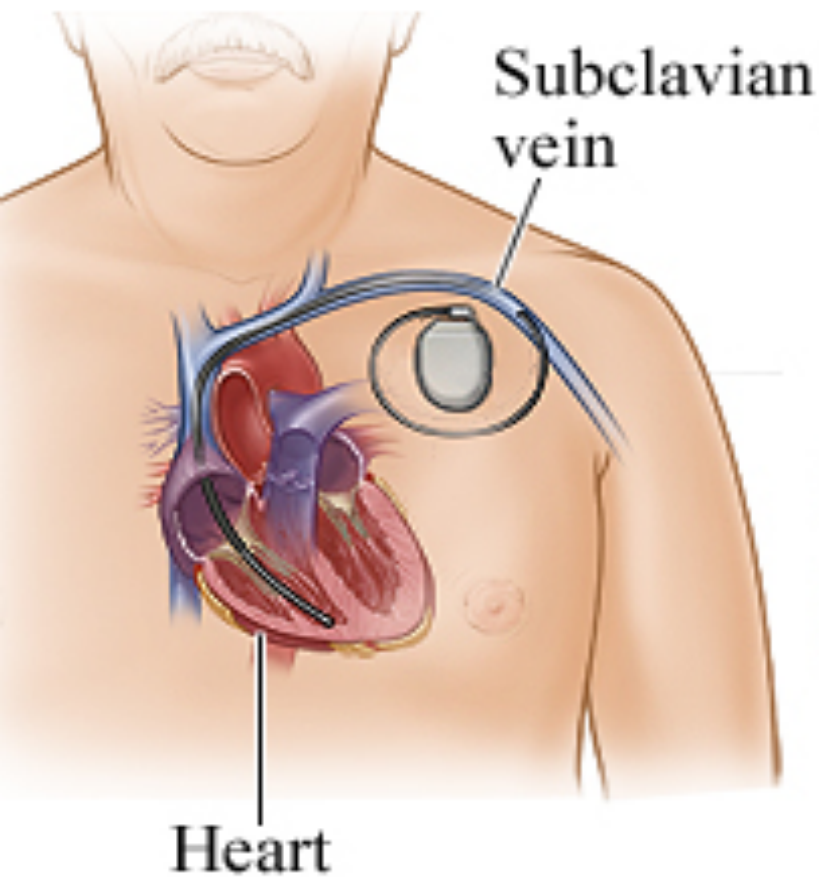
# Ventricular Fibrillation

## Common precipitants of ventricular fibrillation include:

- Myocardial ischemia/infarction,
- Heart failure,
- Hypoxemia or hypercapnia,
- Hypotension or shock,
- Electrolyte imbalances,
- Overdoses of stimulants, especially when used in combination (e.g., Ecstasy)



# Implantable cardioverter-defibrillator



# Ventricular Flutter

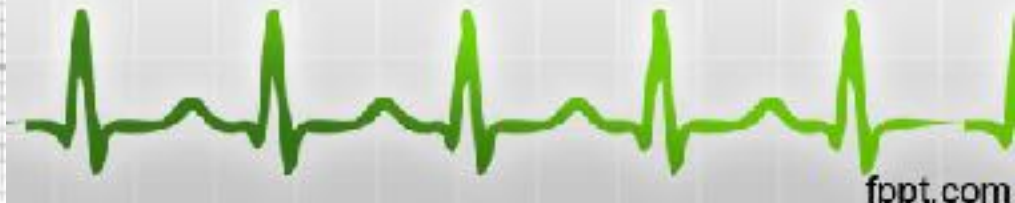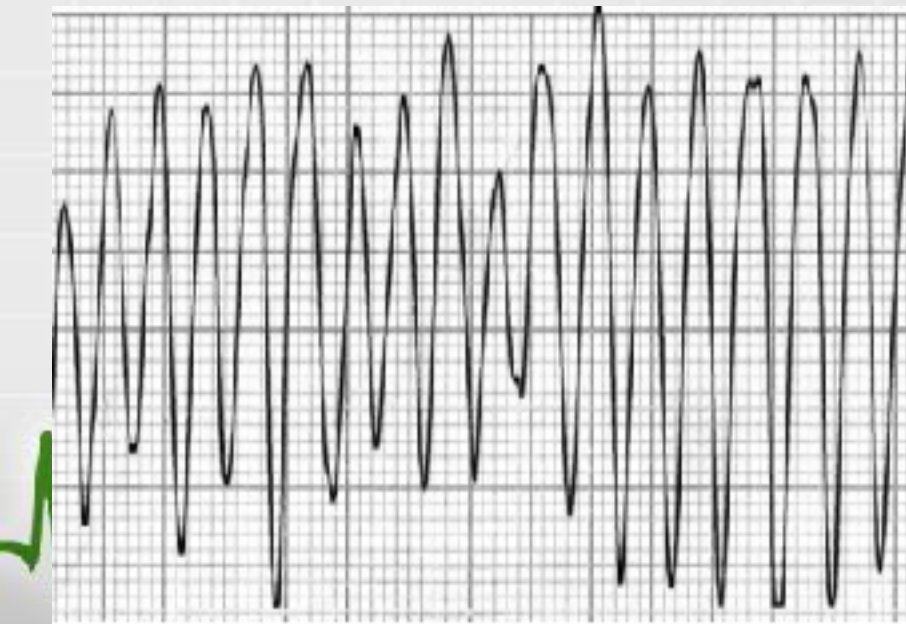
- Extreme form of [ventricular tachycardia](#) with loss of organised electrical activity
- Associated with rapid and profound hemodynamic compromise
- Usually short lived due to progression to [ventricular fibrillation](#)
- As with ventricular fibrillation rapid initiation of [advanced life support](#) is required.



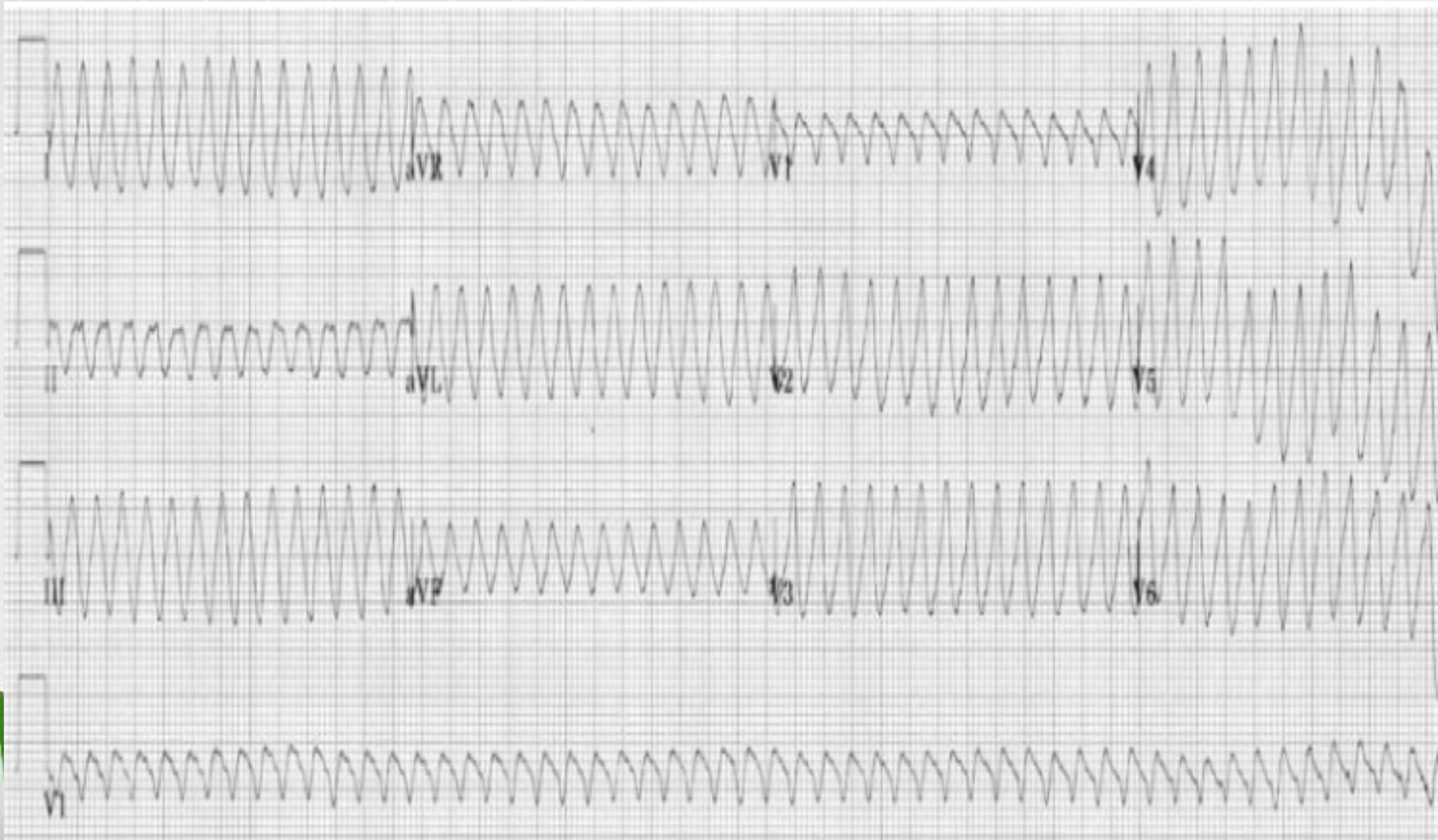# Ventricular Flutter

## How to Recognise Ventricular Flutter

- Continuous Sine Wave
- No identifiable P waves, QRS complexes, or T waves
- Rate usually  $> 200$  beats / min



# Ventricular Flutter





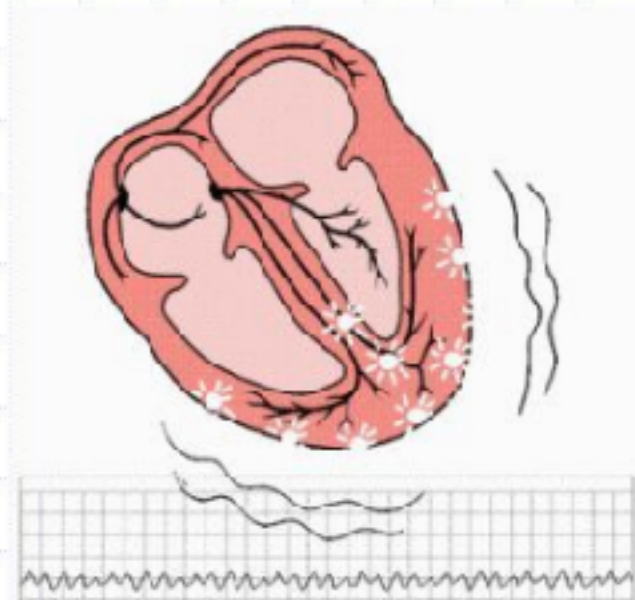
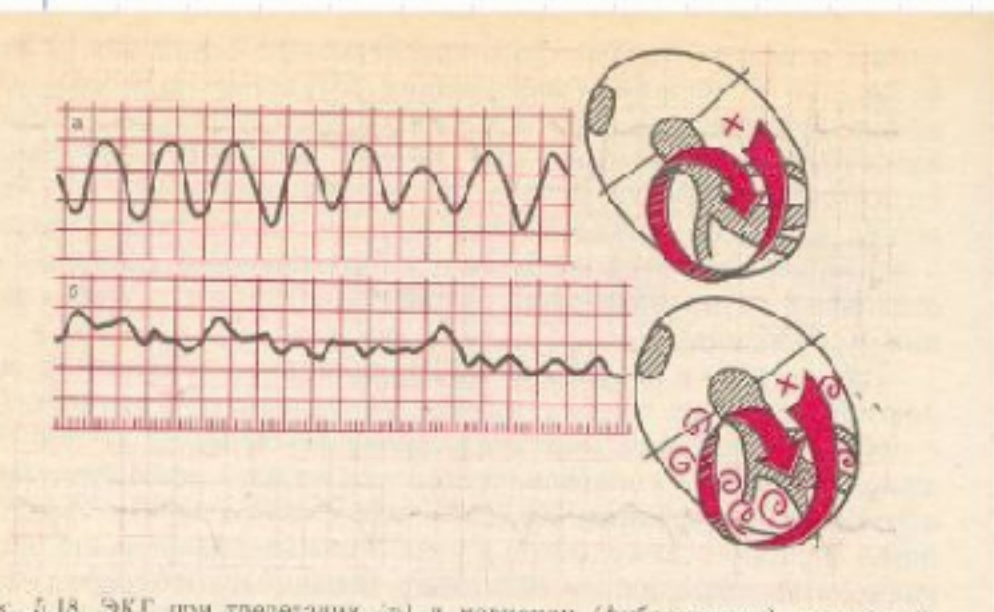
# Ventricle flutter and fibrillation

**Flutter** – frequent (200-300/min) regular excitation and contraction of the ventricles because impulses from ectopic driver circulates constantly ("entry")

**ECG** : no P, QRS is wide

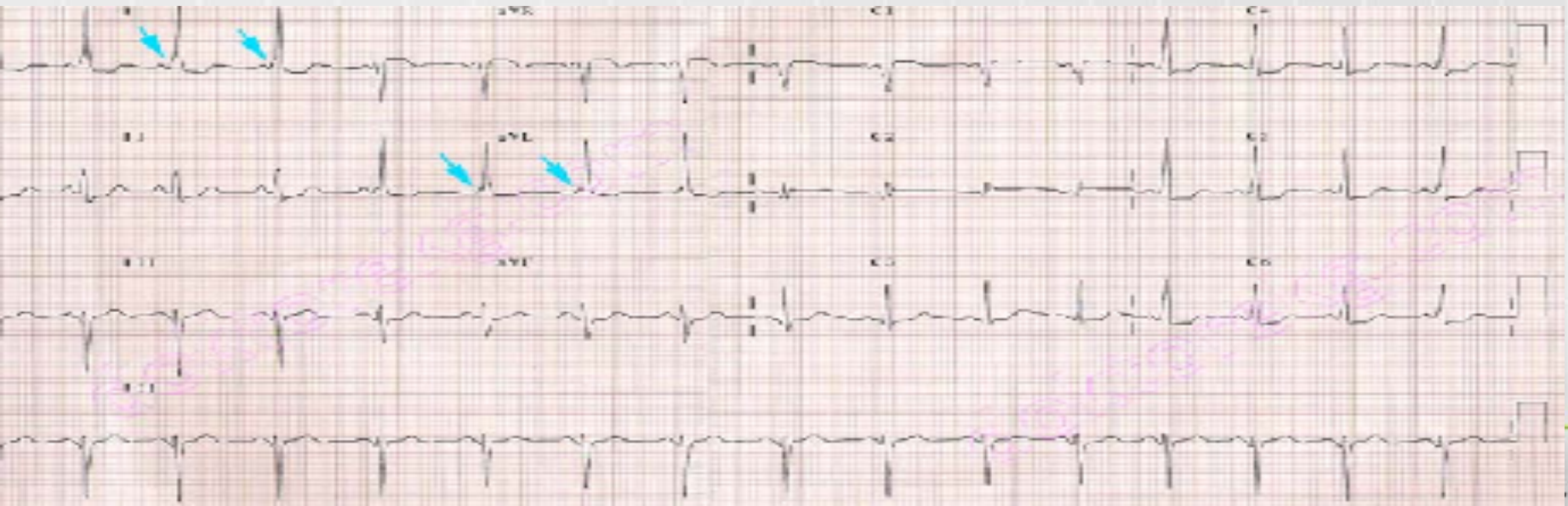
**Fibrillation** – frequent (200-500/min), irregular and chaotic excitation and contraction of cardiomyocyte's separated groups in ventricles (finally ventricles don't contract)

**ECG** : changed shape and amplitude of the waves without any intervals



# Wolff-Parkinson- White Syndrome

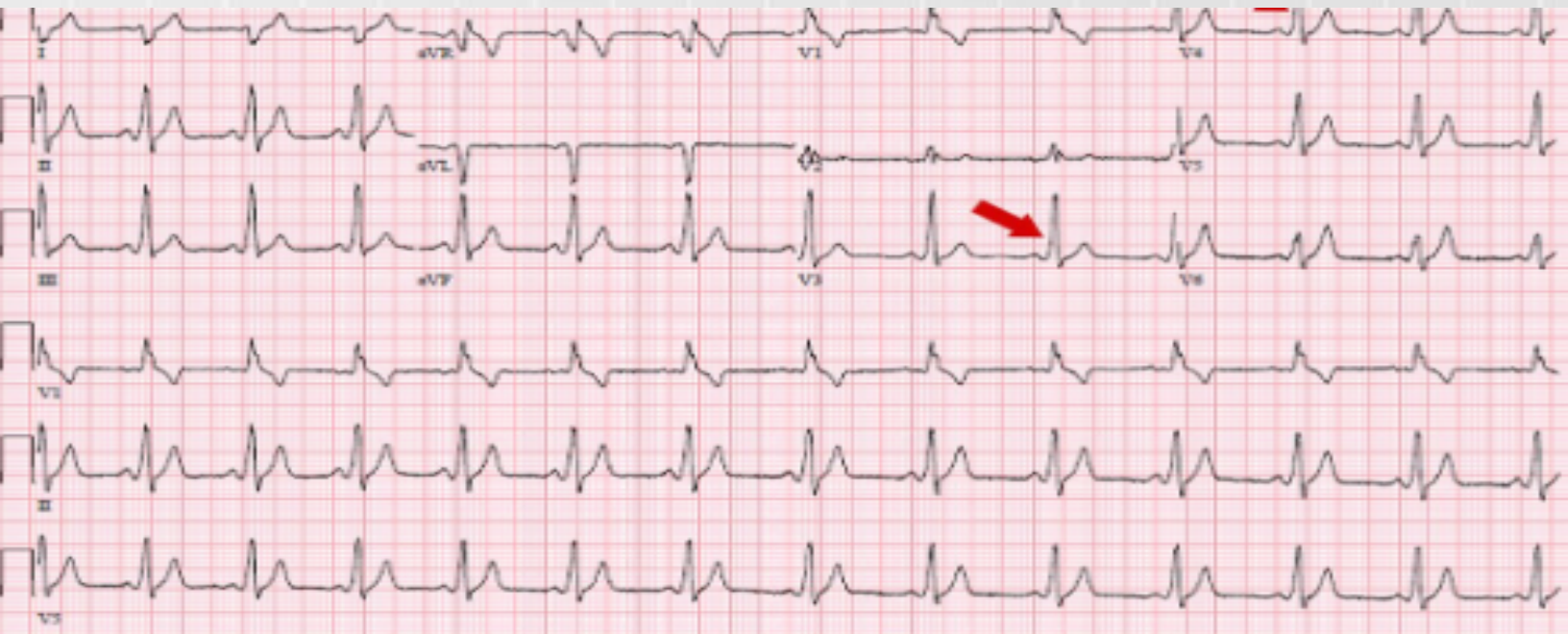
- Using the accessory pathway, supraventricular impulse is not delayed by the AV node. This results in earlier onset of left ventricular depolarization. The premature depolarization is represented by the *delta wave*.
- PR interval shortens less than 0.12 sec
- The addition of delta wave to the QRS complex forms a wider QRS complex

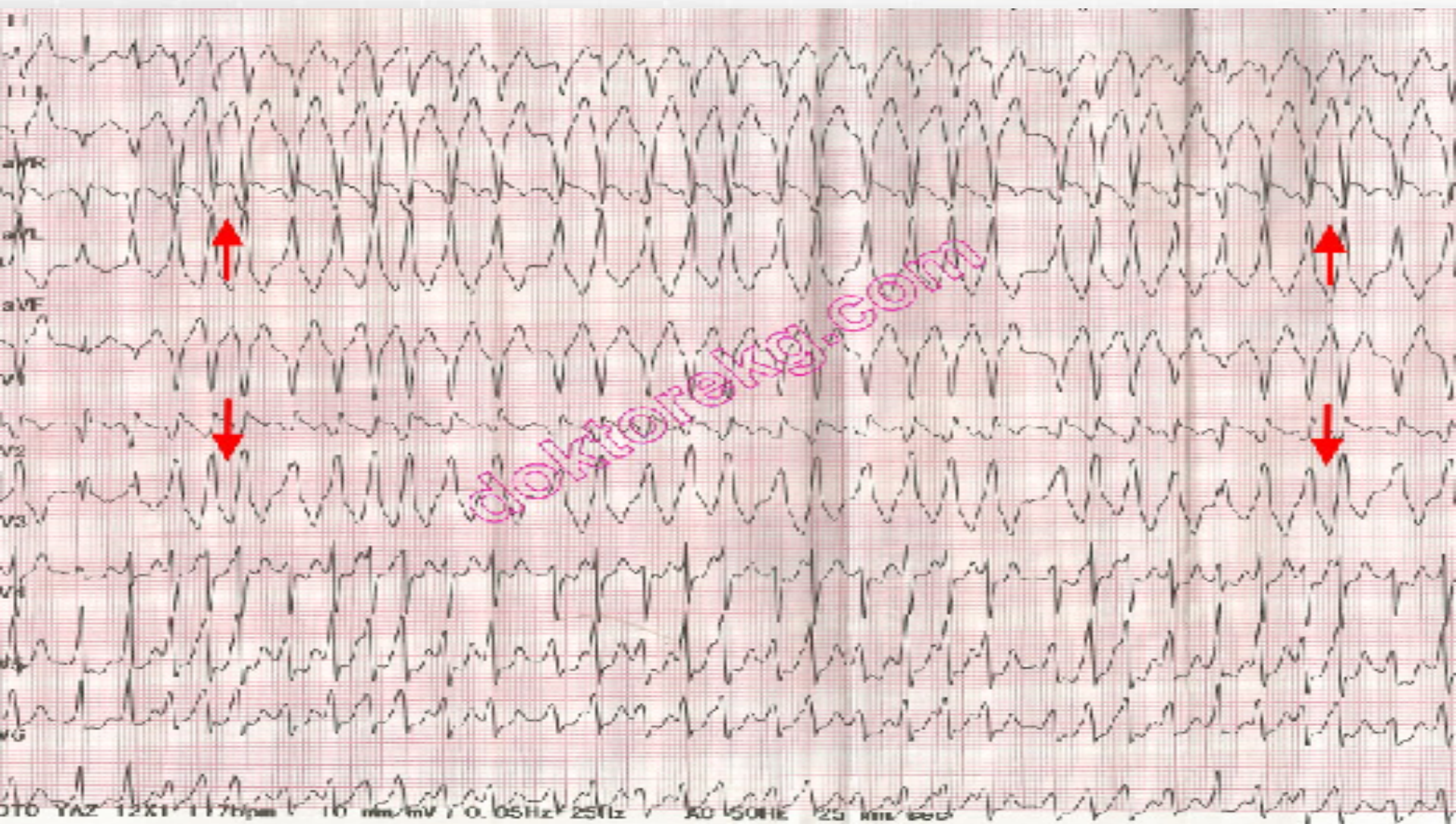


# Wolff-Parkinson- White Syndrome

## WPW syndrome may be intermittent :

- In some patients, preexcitation may be seen on occasional days.
- Preexcitation may appear in a few beats and then disappear and then appear again.





# TACHYARRHYTHMIAS

From a clinician's perspective, the tachyarrhythmias can be most usefully divided into two general groups: those with a "narrow" (normal) QRS duration and those with a "wide" QRS duration.

- Narrow complex tachycardias are almost invariably supraventricular (the focus of stimulation is within or above the AV junction).
- Wide complex tachycardias, by contrast, are either ventricular or supraventricular with aberrant ventricular conduction (i.e., supraventricular tachycardia with aberrancy).



# Major Tachyarrhythmias: Simplified Classification

## Narrow QRS Complexes

Sinus tachycardia

Paroxysmal supraventricular tachycardias (PSVTs)\*

Atrial flutter

Atrial fibrillation

## Wide QRS Complexes

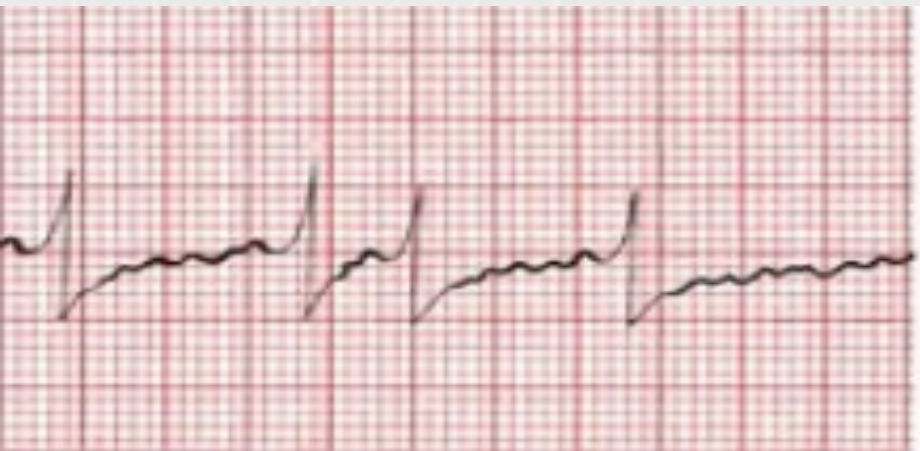
Ventricular tachycardia

Supraventricular tachycardia with aberration caused by a bundle branch block or Wolff-Parkinson-White preexcitation with (antegrade) conduction down the bypass tract

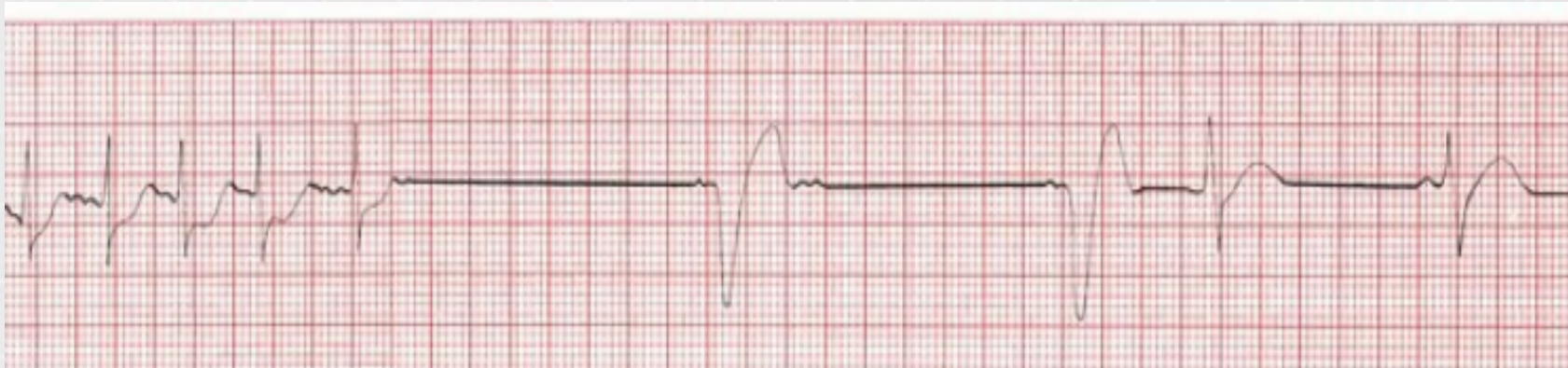*Note:* \*The three most common types of PSVTs are AV nodal reentrant tachycardia, atrioventricular reentrant tachycardia involving a bypass tract, and atrial tachycardia including unifocal and multifocal atrial tachycardia.

# Case report

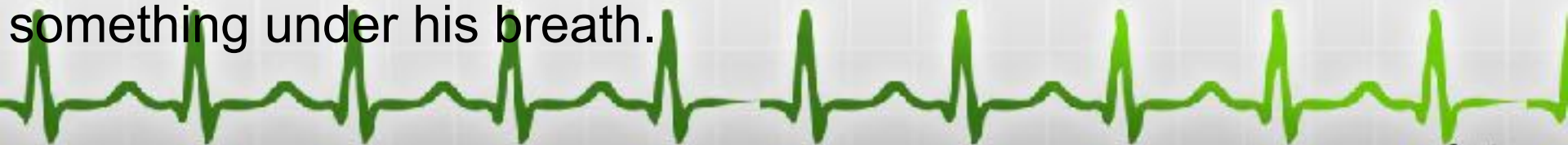- Patient comes to see the doctor late one Friday afternoon.  
He fainted the day before and now is feeling a bit light headed.  
He also has a strange fluttering sensation in his chest.



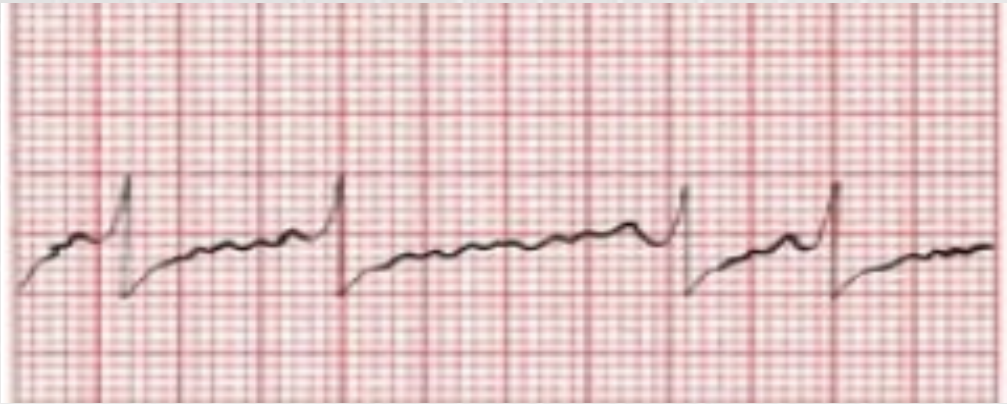Suddenly his eyes roll back in his head and he drops unconscious to the floor. Fortunately, the EKG is still running, and the doctor see:



The doctor drop down to his side, to begin cardiopulmonary resuscitation, when his eyes pop open and he mutters something under his breath.







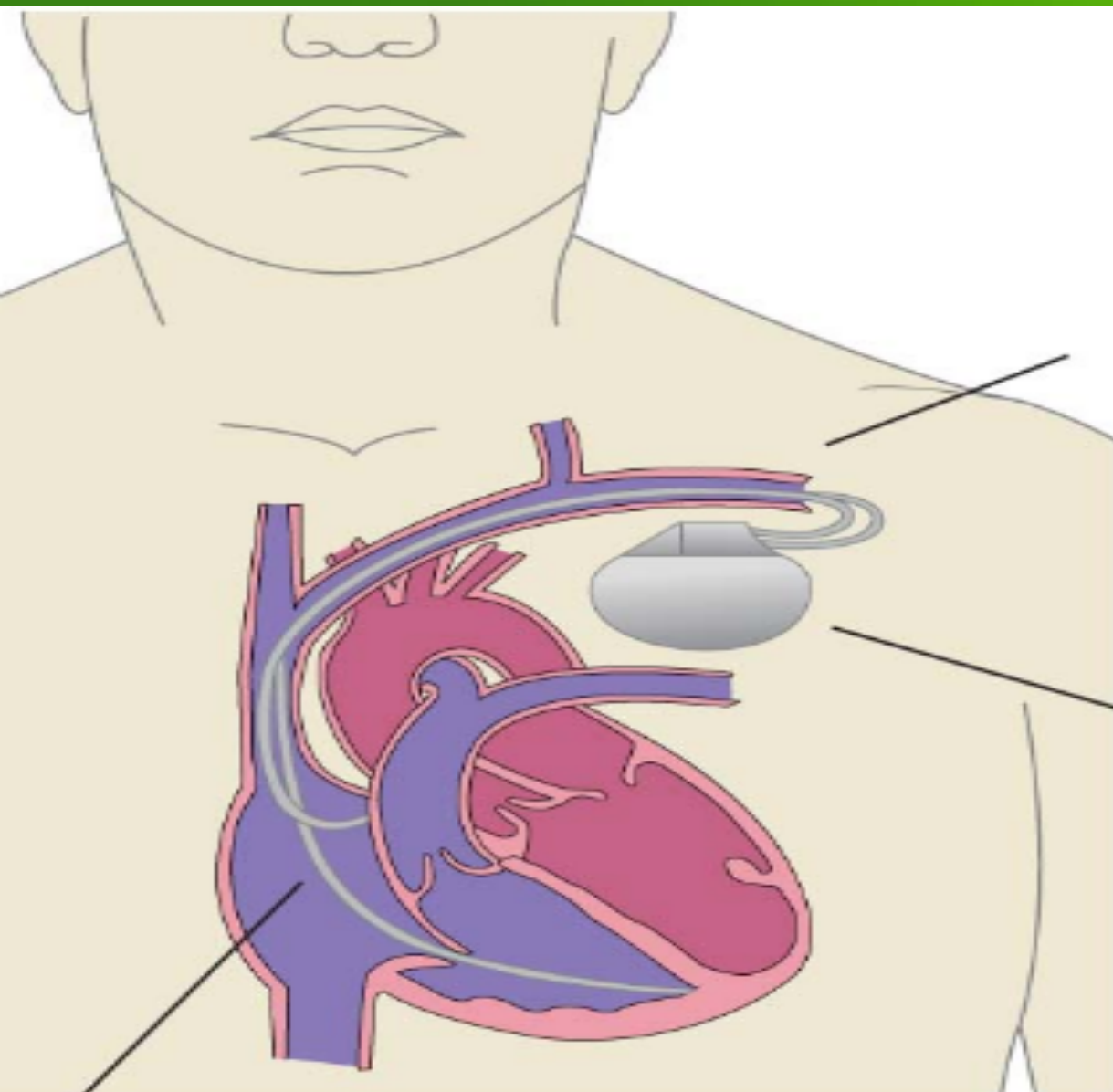
**what's going on?**



- Sick sinus syndrome, called the brady-tachycardia Syndrome. It is typified by alternating episodes of a supraventricular tachycardia, such as atrial fibrillation, and bradycardia. Often, when the supraventricular arrhythmia terminates, there is a long pause ( $> 4$ seconds) before the sinus node fires again.

Sick sinus syndrome usually reflects significant underlying disease of the conduction. It is one of the leading reasons for pacemaker.





Wires are inserted into a vein leading to the heart

Pacemaker box inserted under the skin

Electrodes in heart chambers

